

Serbian Journal of Dermatology and Venereology

ISSN 1821-0902

UDC 616.5(497.11)

Volume 2, Number 2, June 2010

ORIGINAL STUDY
HISTOPATHOLOGY IN THE DIAGNOSIS
OF DERMATOPHYTOSES

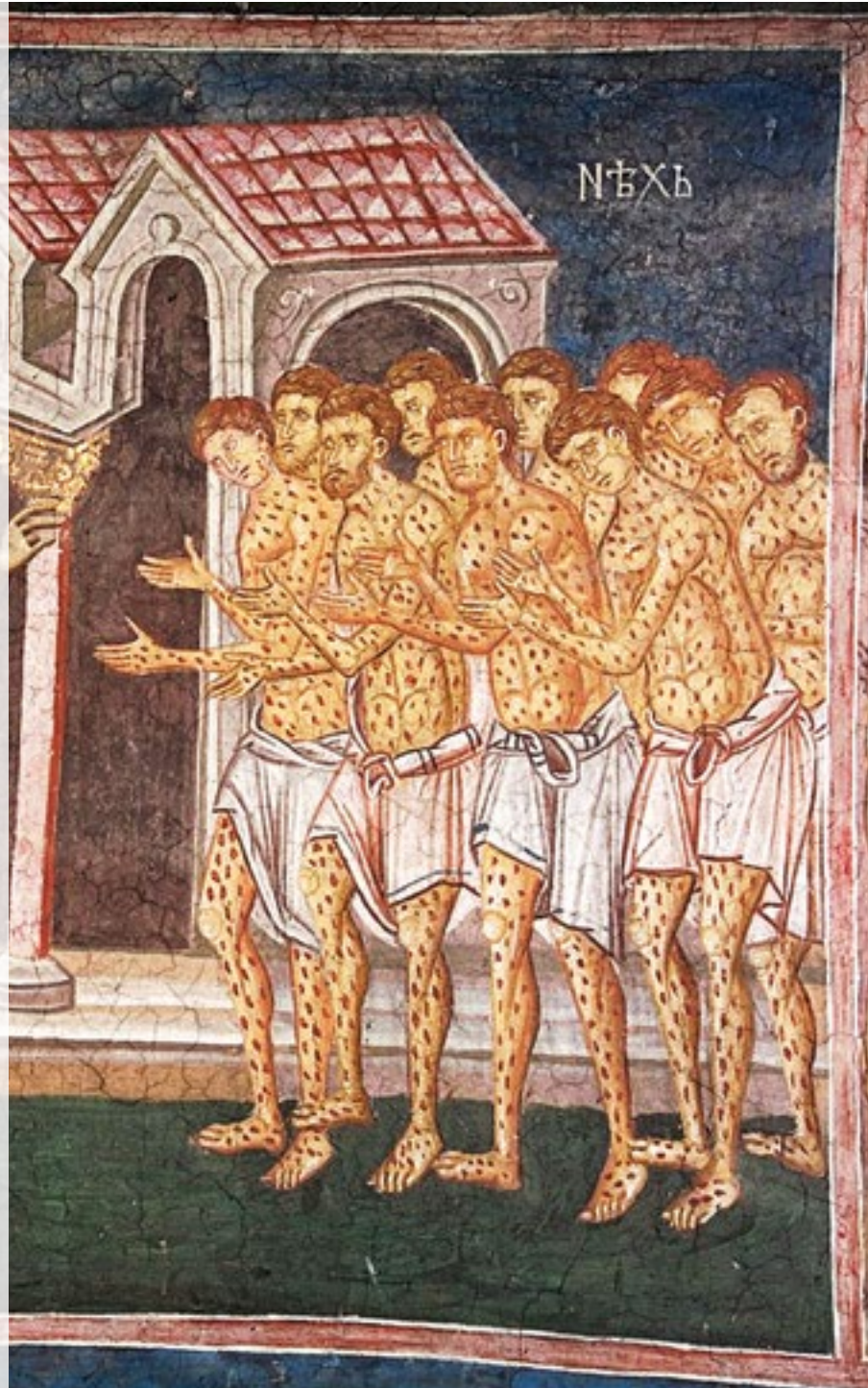CASE REPORTS
PSORIATIC ONYCHO -
PACHYDERMO - PERIOSTITIS

THEVENARD'S DISEASE -
A HEREDITARY NEUROPATHY

HISTORY OF MEDICINE
HISTORY OF DERMATOVENEREOLOGY
IN SERBIA FROM 1919 – 1945: part 2

REPORT

FORTHCOMING EVENTS



Published by the
Serbian Association of Dermatovenereologists





SERBIAN ASSOCIATION OF DERMATOVENEROLOGISTS

President of the Association
LJILJANA MEDENICA, Belgrade

SERBIAN JOURNAL OF DERMATOLOGY AND VENEREOLOGY

Editor-in-Chief
MARINA JOVANOVIĆ, Novi Sad

Assistants to the Editor-in-Chief
ZORAN GOLUŠIN, Novi Sad
DRAGAN JOVANOVIĆ, Niš
LIDIJA KANDOLF-SEKULOVIĆ, Belgrade
MILAN MATIĆ, Novi Sad

EDITORIAL BOARD

President
MILOŠ NIKOLIĆ, Belgrade

Secretary
DANIJELA DOBROSAVLJEVIĆ, Belgrade

Members

IVANA BINIĆ, Niš, Serbia	LJILJANA MEDENICA, Belgrade, Serbia
VERICA ĐURAN, Novi Sad, Serbia	MILOŠ PAVLOVIĆ, Ljubljana, Slovenia
ANNA GORKIEWICZ-PETKOW, Warsaw, Poland	ROBERT A. SCHWARTZ, New Jersey, USA
CAMILA K. JANNIGER, New Jersey, USA	MILENKO STANOJEVIĆ, Niš, Serbia
ĐORĐIJE KARADAGLIĆ, Belgrade, Serbia	JACEK C. SZEPIETOWSKI, Wroclaw, Poland
ANDREAS KATSAMBAS, Athens, Greece	GEORGE SORIN TIPLICA, Bucharest, Romania
ALEKSANDAR KRUNIĆ, Chicago, USA	NIKOLAI TSANKOV, Sofia, Bulgaria
BOSILJKA LALEVIĆ-VASIĆ, Belgrade, Serbia	NADA VUČKOVIĆ, Novi Sad, Serbia
MARKO LENS, London, United Kingdom	RADOŠ ZEČEVIĆ, Belgrade, Serbia
JOHN McGRATH, London, United Kingdom	

Technical Assistant: Vesna Šaranović
English Proofreading: Marija Vučenović
Serbian Proofreading: Dragica Pantić
UDC Selection: Zorica Đokić
Reference Checking: Branislava Čikić

The Journal is published four times a year with the circulation of 300. Manuscripts are to be submitted to the Editor-in-Chief: Prof. Dr. Marina Jovanović, Klinički centar Vojvodine, Klinika za kožne i venerične bolesti, 21000 Novi Sad, Hajduk Veljkova 1-7
E-mail: serbjdermatol@nadlanu.com, Tel: +381 21 484 3562; +381 21 451 781.

Copyright © 2009 by the Serbian Association of Dermatovenereologists

Published on behalf of The Serbian Association of Dermatovenereologists by Zlatni presek, Beograd

CONTENTS

Serbian Journal of Dermatology and Venereology 2010; 2 (2):41-80.

ORIGINAL STUDY

- 45 **THE ROLE OF HISTOPATHOLOGY IN DIAGNOSIS OF DERMATOPHYTOSES**

Dorđi GOCEV, Katerina DAMEVSKA

CASE REPORTS

- 54 **PSORIATIC ONYCHO-PACHYDERMO-PERIOSTITIS**

*Zorica PERIĆ-HAJZLER, Lidija KANDOLF-SEKULOVIĆ,
Lidija ZOLOTAREVSKI*

- 59 **THEVENARD'S DISEASE - A HEREDITARY SENSORY AND
AUTONOMIC NEUROPATHY TYPE I**

*Borut NIKOLIĆ, Milan MIŠOVIĆ, Miodrag ZORIĆ,
Dušica MATOVIĆ, Aleksandra ALEKSIĆ*

HISTORY OF MEDICINE

- 66 **HISTORY OF DERMATOLOGY AND VENEREOLOGY IN SERBIA – PART IV/2:
DERMATOVENEREOLOGY IN SERBIA FROM 1919 – 1945, PART 2**

Bosiljka M. LALEVIĆ-VASIĆ and Marina JOVANOVIĆ

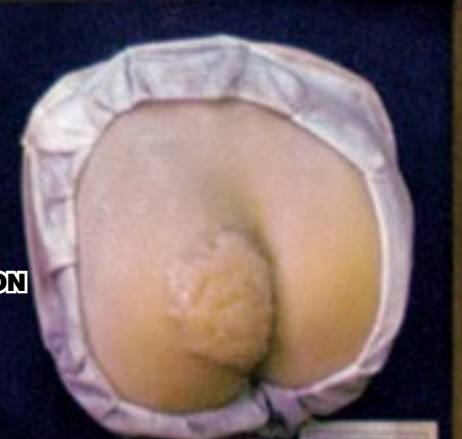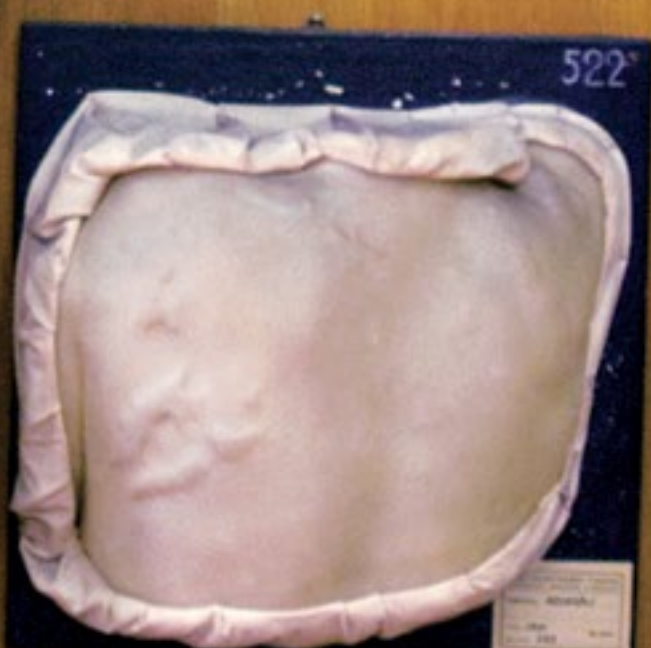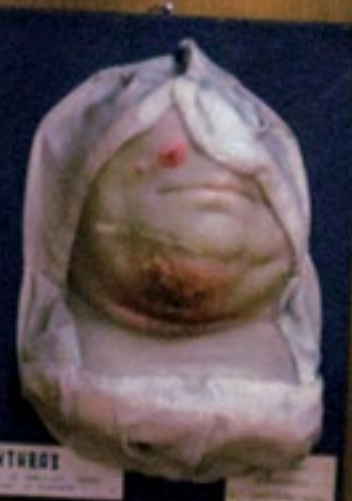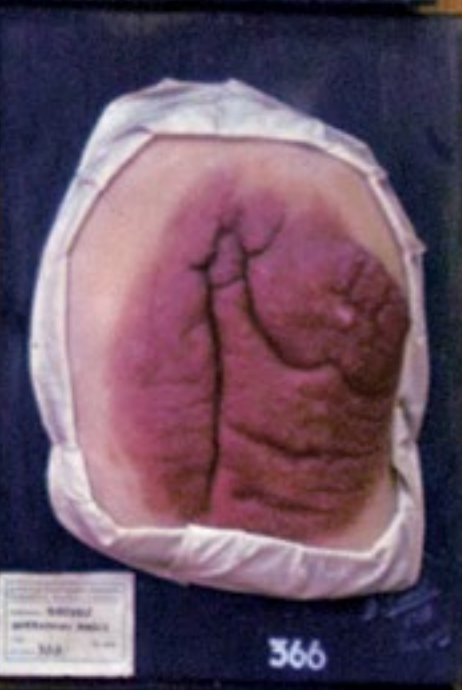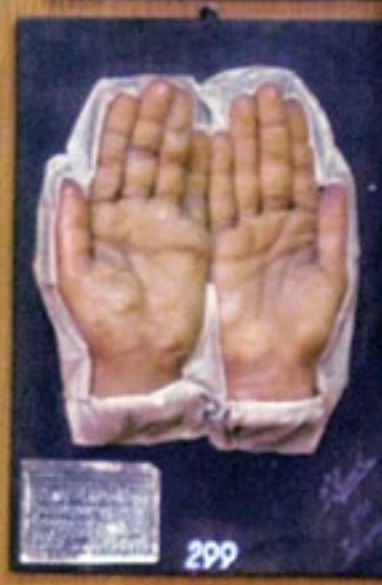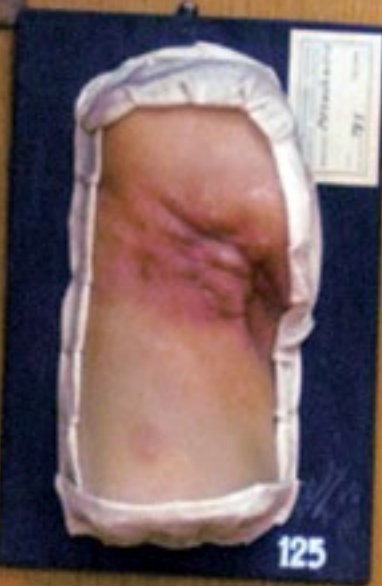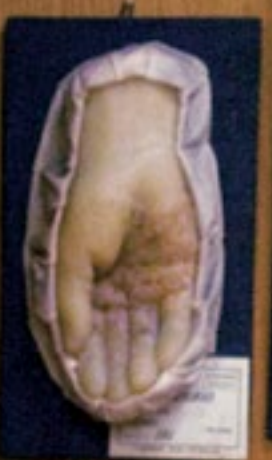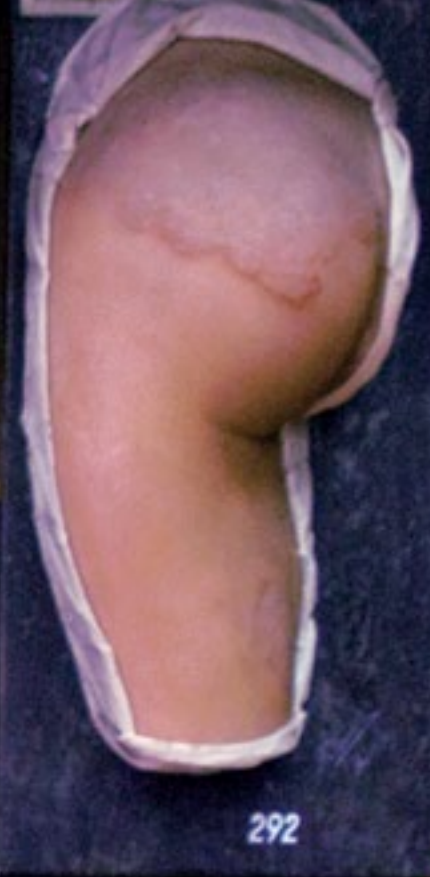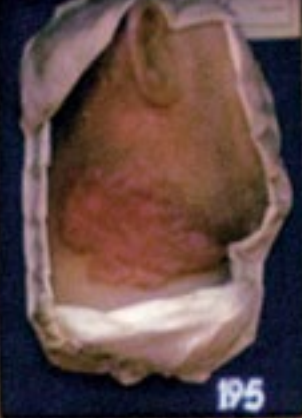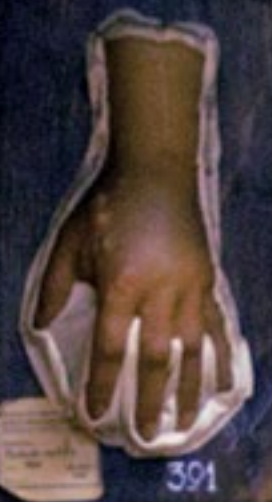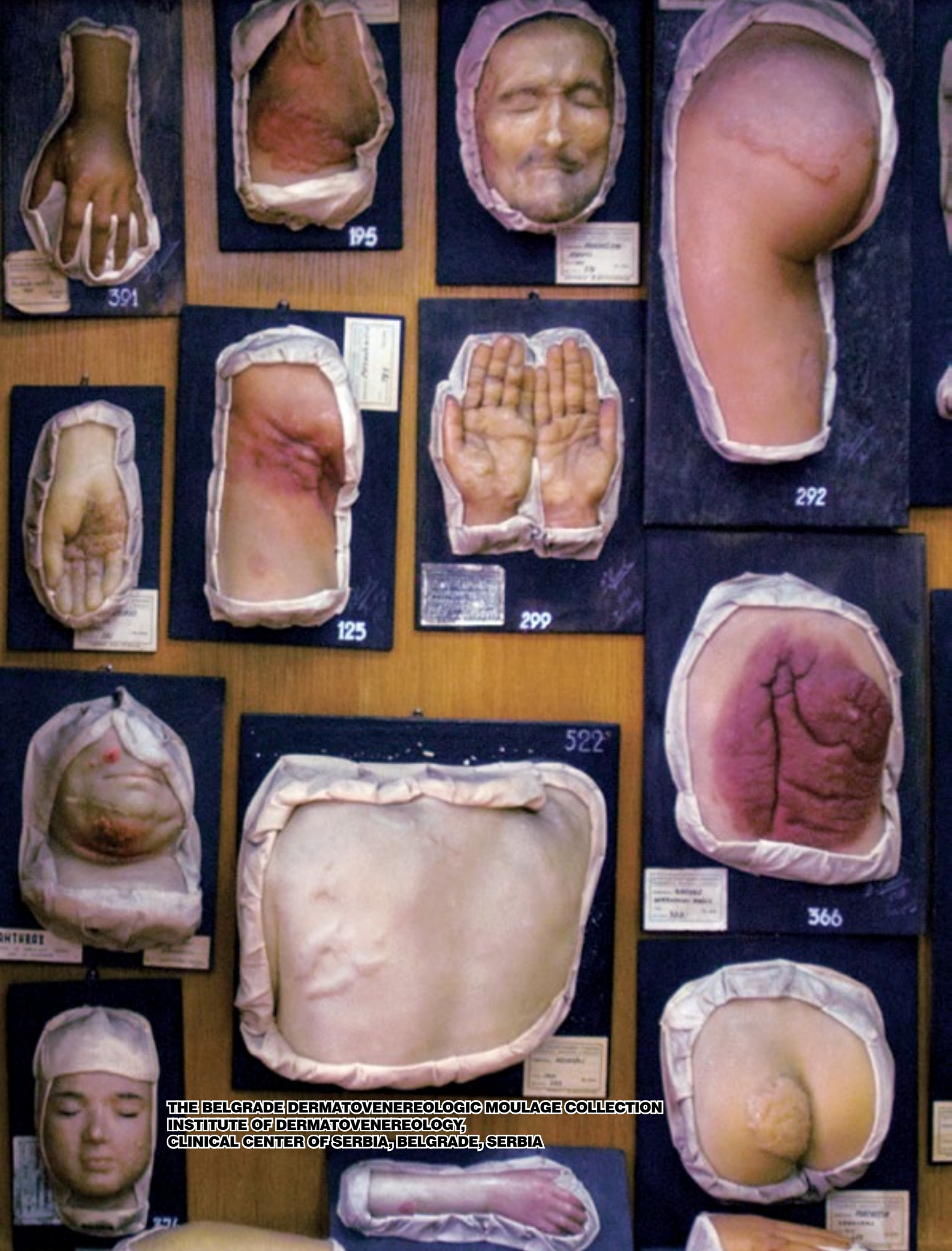REPORT

- 73 **A REPORT ON THE 7TH SPRING SYMPOSIUM OF
THE EUROPEAN ACADEMY OF DERMATOLOGY AND VENEREOLOGY**

Zoran GOLUŠIN

FORTHCOMING EVENTS

- 75 **DERMATOLOGY AND VENEREOLOGY EVENTS 2010-2011**



**THE BELGRADE DERMATOVENEREOLOGIC MOULAGE COLLECTION
INSTITUTE OF DERMATOVENEREOLOGY,
CLINICAL CENTER OF SERBIA, BELGRADE, SERBIA**

The role of histopathology in the diagnosis of dermatophytoses

Đorđi Gocev, Katerina Damevska

University Clinic of Dermatology, Faculty of Medicine, University "Ss Kiril and Metodij", Skopje, Republic of Macedonia

Corresponding author: Prim. Dr. Đorđi Gocev, E-mail: Dr.Gocev@t-home.mk

UDC 616.5-002.828-076.1

Abstract

Histopathological analysis is not a routine procedure for diagnosing fungal skin infections. In the histopathological specimens, fungi are visible only when using special stain such as *periodic acid-Schiff* (PAS). However, histopathological analysis may not be performed in small laboratories. Histopathological characteristics of fungal skin infections are not specific. In all skin biopsy cases, obtained without clinical suspicion of fungal infection, the knowledge of certain, most frequent histopathological reaction patterns, as well as specific histopathological indicators (a diagnostic histopathological "clue"), of certain superficial mycoses e.g., dermatophytoses, may raise a suspicion of fungal infection and warrant a fungal-specific staining. A retrospective analysis of all PAS-stained sections was carried out. All PAS-positive biopsy specimens were assessed for clinical features, histopathological patterns of skin reactions, and presence of histopathological indicators. Our results have shown that out of the total of 361 PAS-stained sections, fungal hyphae were identified in 12 (3.3%) specimens. In 5 (1.4%) cases, the diagnosis of fungal infection was suspected on clinical grounds, while in 7 (1.9%) cases detection of fungi was an unexpected finding. The most frequent type of histopathological pattern was spongiotic, and the most frequent histopathological indicator was the presence of neutrophils within the epidermis. Our results confirm that dermatophytoses may present with clinical and histological non-specific findings. PAS staining represents a relatively cheap and simple fungal-specific staining. It has been suggested that it not only confirms that the selected material is actually invaded, but also reduces the number of false-negative direct reports, where fungi are cultured from a microscopically negative specimen. Apart from a small percentage of positive findings, our results justify the need for routine PAS staining of all clinically and histologically non-specific inflammatory skin conditions.

Fungal infections account for 3-5% of all consultations in dermatology practice (1). Cutaneous manifestations of superficial fungal infections are rather common. The most frequent causative agents are dermatophytes, while less common are those that cause deep skin infections or primary systemic infections with a secondary skin involvement. The diagnosis is usually strongly suspected on clinical grounds, and supported by both direct microscopic findings, which is easily carried out by clearing the specimen in 10-30% potassium hydroxide solution, and by culture in selective media. Less commonly, fluorescent microscopy of stained specimens, Wood's light, histopathological analysis, cutaneous and immunological tests, as well as PCR are used. Histopathological analysis is not the routine procedure for diagnosing fungal skin infections.

Histopathological analysis of specimens is required in all cases in which deep and/or superficial fungal infection, e.g., dermatophytosis or tinea with negative direct microscopic and culture results, is suspected (1). Moreover, histopathology is the most sensitive technique for diagnosing onychomycoses (2).

Dermatophytes cannot be easily identified with routine histopathological stains, such as hematoxylin-eosin (H&E), even by experienced histopathologists, because fungal elements, the hyphae, are stained pale blue (Figure 1). If stained with H&E, hyphae can be detected in less than 60% of cases (3). Visualization of fungal elements in histological slides is facilitated with fungal-specific stainings, such as periodic acid-Schiff (PAS) and PAS-d (PAS-diastrase) which stain hyphae red (Figure 2), as well as Grocott's

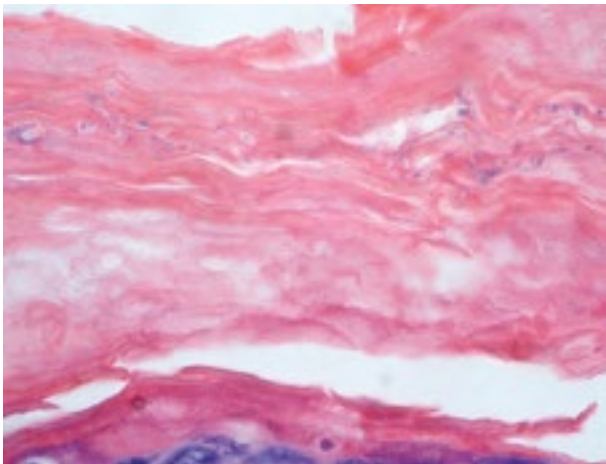


Figure 1. H&E-stained section showing pale blue stained hyphae in the corneal layer (hematoxylin and eosin, x 400)

methenamine silver (GMS) that stains them black (1).

Only on rare occasions, the skin biopsy is obtained and sent for dermatopathology evaluation, in order to confirm clinically diagnosed dermatomycosis. More often, the diagnosis of fungal skin infections is only one differential diagnosis among the others (e.g., psoriasis, parapsoriasis, eczema, palmoplantar pustulosis, annular erythema, granuloma annulare, etc.). According to many reports, the diagnosis of dermatophytic infection can be established

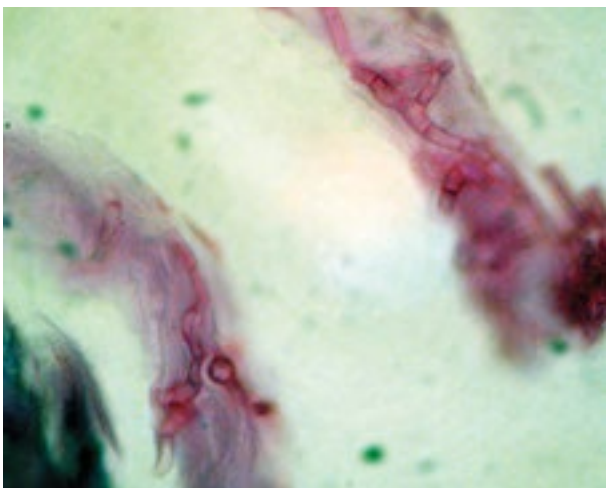


Figure 2. PAS-stained section showing red stained hyphae in the corneal layer (periodic-acid-Shiff, x 800)

histopathologically even in cases where it is not clinically suspected (4). Beside the atypical clinical appearance (Figure 3), dermatophyte infections may also exhibit atypical histological features. Cases of bullous (5), acantholytic (6), purpuric (7) reaction pattern, or even cases of eosinophilic folliculitis (8) have been described.

If dermatophyte infection (dermatophytosis), represents one among other clinically established diagnoses, then presence of fungal elements can be easily confirmed by biopsy, since slides will be stained not only with a H&E, but with a fungal-specific stains as well. In cases where skin biopsies were obtained without clinical suspicion of dermatophytosis, the most frequent patterns of histopathological reactions in dermatophytoses, as well as specific histopathological “indicators” (particularly important in establishing diagnosis of superficial fungal skin infections), can lead to suspicion of fungal infection and additional fungal staining. The presence of hyphae in slides is the only histopathological (HP) proof of dermatophytosis (1).

By the definition, the pattern of histological reactions is a combination of histological findings that are helpful in reducing the list of possible histological differential diagnoses, while a histological indicator – “diagnostic clue” is a subtle histologic finding that significantly leads to specific histological diagnosis. However, histologic patterns and indicators are not sufficient

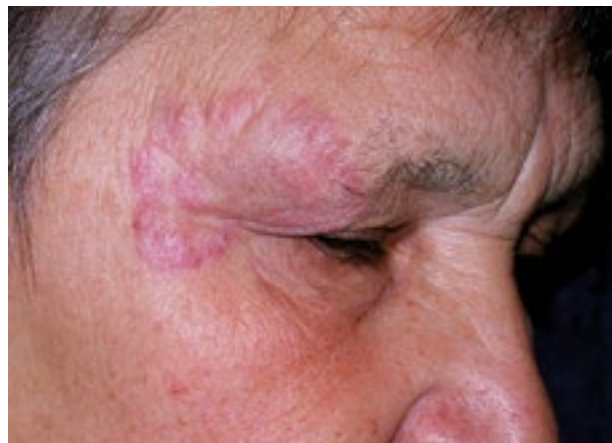

Figure 3. Tinea incognita

to establish the diagnosis of dermatophytosis, but they suggest taking further steps, such as special staining for fungal elements in order to confirm the diagnosis.

The most frequent histopathological reaction patterns of dermatophytoses

The presence of fungal elements in the epidermis induces tissue inflammatory reactions which vary from almost undetectable responses to severe reactions. The histologic pattern reactions highly depend on the fungi, immune status of the host and local factors (1).

1. Superficial perivascular dermatitis/perivasculitis is characterized by sparse perivascular infiltrates in the superficial dermis, and minimal or absent epidermal changes (discrete hyperkeratosis and intercellular edema). This finding is not specific, and it can be found in many other dermatological conditions. However, basket weave hyperkeratosis may indicate a fungal infection. Hyphae can be seen within the corneal layer on the H&E stained sections.

2. Spongiotic/eczematous reaction pattern is the most frequent finding in acute inflammatory skin conditions. This pattern shows perivascular, predominantly lymphocytic infiltrates in the upper dermis associated with prominent epidermal intercellular edema, hyperkeratosis and focal parakeratosis. If present, fungal elements are usually found close to the parakeratotic foci, making their visualization on H&E stained slides extremely difficult. This pattern is the most common finding in dermatophytoses.

3. Psoriasiform reaction pattern is characterized by psoriasiform epidermal hyperplasia, hyperkeratosis and parakeratosis. The existence of neutrophils in the spinous and corneal layers with formation of small "abscesses" is almost identical with the so called eruptive psoriasis. However, coexistence of parakeratosis and neutrophils can make visualization of hyphae and spores almost impossible, so PAS staining procedure is warranted.

4. Folliculitis and perifolliculitis reaction patterns are characterized by perifollicular inflammation of various intensity, and mononuclear as well as mixed cellular infiltrates. Spongiotic follicular epithelia with lymphocyte and neutrophil migration may be seen. PAS staining is of great importance in differentiating trichomycoses from folliculitis and perifolliculitis of other etiology (Figure 4). In slides with dense inflammatory infiltrates and follicle destruction, it is very difficult to identify fungal elements even in PAS-stained sections.

5. Granulomatous reaction pattern is usually associated with deep fungal infections. Dermal granulomatous inflammatory infiltrate finding requires additional PAS staining regardless of clinical diagnosis (1).

Histopathologic features ("clues") of dermatophytoses

H&E stained slides provide few valid signs that not only suggest the diagnosis of dermatophytosis, but also show the location where fungal elements should be sought.

1. Neutrophils in the epidermis are directly related to the presence of fungi in the epidermis, since fungi elicit neutrophil chemotaxis and migration into the epidermis (9). According to Ackerman, the presence of neutrophils and/or their fragments in the corneal layer, in association

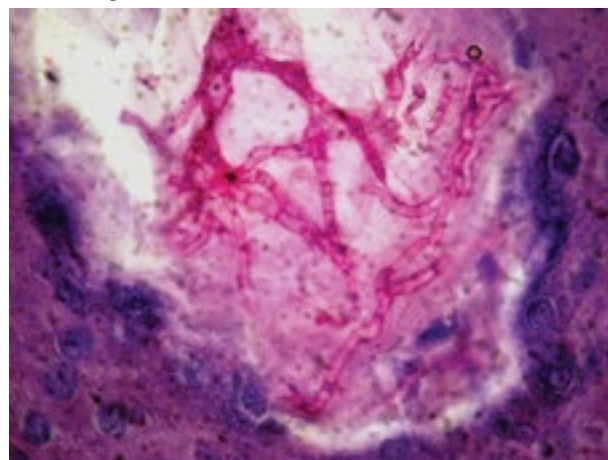


Figure 4. PAS-stained section showing hyphae in the hair follicle (periodic-acid-Shiff, x 400)

with compact orthokeratosis and/or parakeratosis, should be considered a positive symptom of dermatophytosis. Since 1986, it has been termed the diagnostic “clue to dermatophytoses” (10) (Figure 5).

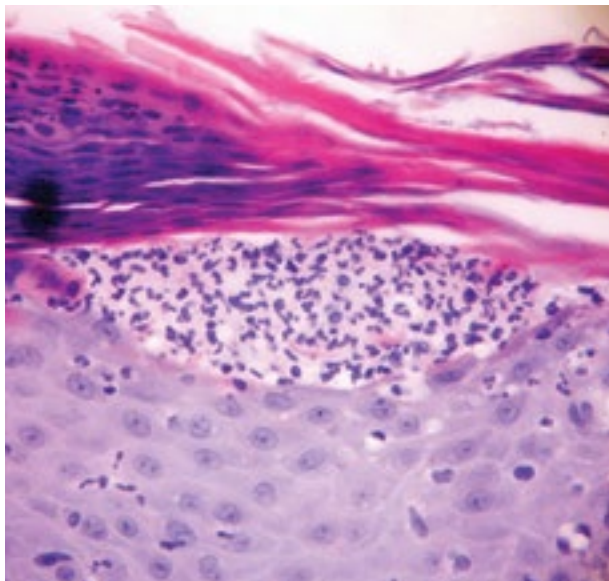


Figure 5. H&E-stained section showing neutrophils in the epidermis layer (hematoxylin and eosin, x 800)

2.” *Sandwich” sign* results from the presence of fungal hyphae between two zones of cornified cells. Superficially, there is a orthokeratotic lamella, partially or completely parakeratotic lamellae beneath, with formation of fissure in between (12). These histological findings strongly support the need for special staining. If present, fungal elements can be seen within the fissure – in the “sandwich”, between the two morphologically different lamellae of the corneal layer (Figure 6 and Figure 7). Although specific, this clue is not a common finding in histopathologic micrographs of fungal infections (3).

3. *Basket-weave pattern or compact hyperkeratosis* is frequently reported as a histopathological indicator, although it has been proven that this sign is a common finding in non-dermatophytic infections (3).

4. *Prominent papillary dermal edema (PPDE)*, originally described by Ackerman and

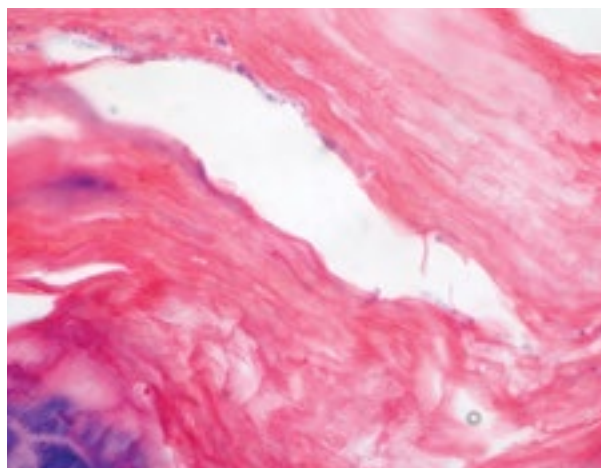


Figure 6. H&E-stained section showing a sandwich sign - hyphae in the corneal layer fissure (hematoxylin and eosin, x 400)

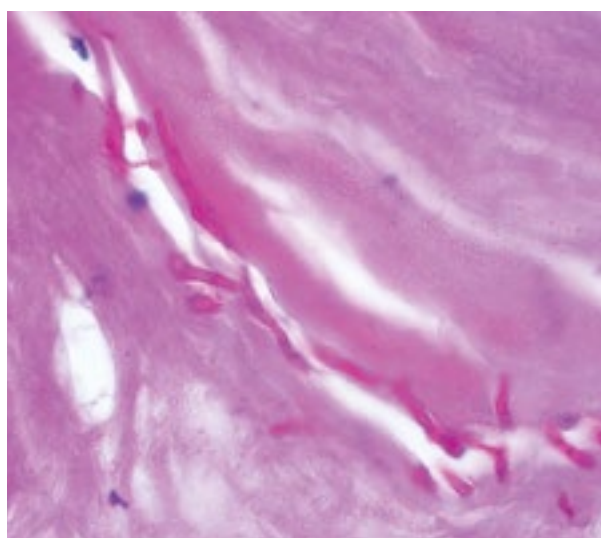


Figure 7. PAS-stained section showing a sandwich sign - hyphae in the corneal layer fissure (periodic-acid-Shiff, x 400)

confirmed by Hoss et al., was present in a series of 16 reported cases of dermatophytic infections in glabrous skin (13).

Purpose

The purpose of this study was to estimate the prevalence of PAS-positive skin biopsies among all PAS-stained biopsies performed during the past six years and to analyze their clinical and histopathological features. All PAS-positive biopsy

specimens were assessed for histopathologic patterns of skin reactions, and presence of histopathological indicators.

Material and methods

During the period from January 2004 to December 2009, a total of 361 PAS-stained biopsies were retrospectively re-examined and clinical data were analyzed in the Dermatopathology Laboratory of the University Clinic of Dermatology in Skopje. Clinical data were obtained by reviewing pathology referral information.

All PAS-positive biopsy specimens were assessed for histopathological patterns of skin reactions and presence of histopathological indicators.

Results

Out of a total of 2,391 biopsies received during the past six years, PAS staining was performed in 361 (15%). In 134 cases, dermatophytosis was one of the clinical differential diagnosis. In 127 cases skin biopsies were PAS-stained due to additional requirements of histopathologists.

Out of the total number of PAS-stained samples, fungi were identified in 12 (3.3%) slides. In 5 cases (1.4%), fungal infection was one among other differential diagnoses and in 7 cases (1.9%) newly diagnosed dermatophytosis was established.

The most frequent location of skin lesions were palms, soles (5) and face (2). The most common differential diagnoses were eczema, contact dermatitis and palmo-plantar psoriasis (Table 1).

The most frequent histopathological inflammatory reaction patterns (in 12 PAS-positive slides) were spongiotic, found in 7 (58%) cases, and psoriasiform pattern present in 3 cases (25%) (Table 2).

Neutrophils in the corneal layer were the most common histopathological indicators registered in 8 (66%) cases. Prominent papillary dermal edema was registered in 2 cases. Both patients suffered from tinea corporis.

Hyphae have been visible in H&E stained sections in 3 cases (cases number 8, 11 and 12).

In our series, few unusual clinical manifestations of fungal skin infections were registered. One patient (number 9) was diagnosed and treated for DLE instead for tinea faciale. One patient (number 12) with the diagnosis of HIV infection had extensive scaly and pustular lesions located on extremities. The biopsy specimen obtained from this patient showed predominantly eosinophilic dermal infiltrate and numerous hyphae visible in H&E stained section.

Discussion

Two factors make the histopathological diagnosis of dermatophytoses difficult. Firstly, hyphae cannot be easily seen in H&E stained sections. In one series, only 57% of PAS positive cases exhibited hyphae in H&E stained sections (3). In our study, only three cases (25%) presented with visible hyphae in H&E stained sections. Secondly, in most biopsies, dermatophytosis is only rarely suspected. Al-Almiri et al. reported that tinea was included in the differential diagnosis only in 45% of PAS positive cases (3).

We found 3.3% (12/361) PAS positive cases, moreover 1.9% (7 cases) were newly diagnosed dermatophytoses, where fungal infection was not clinically suspected. These results are similar to the results reported by Murphy whose study included a total of 99 PAS stained skin biopsies: 3 cases of clinically suspected dermatophytoses were confirmed, and 4 cases were newly diagnosed dermatophytoses (14). A cost-effective analysis was also performed, and it was concluded that a finding of at least one case of unexpected fungal infection is financially justified (14).

The importance of histopathological reaction patterns and indicators

Inflammatory response to superficial fungal infection highly depends on the fungal virulence, the host immune system, and local factors (1). Skin reactions may vary, ranging from mild to

Table 1. Clinical and histological findings in 12 patients with PAS positive staining

Patient #: age/gender/location	Submitted clinical diagnosis	Histopathological findings (H&E)
#1: 43 years/female/forearm	Allergic contact dermatitis	Scale, crust and fibrin NE Mixed dermal infiltrate
#2: 33 years/male/foot	Pustular psoriasis Tinea	Scale, crust, numerous hyphae SS, NE Mixed dermal perivascular infiltrate
#3: 21 years/female (no data about location)	Nummular dermatitis	Scale, crust NE, PPDE Mixed dermal infiltrate
#4: 45 years/female/shin	Tinea Contact dermatitis	Scale, crust, numerous hyphae NE Superficial/deep lymphocytic infiltrate
#5: 46 years/female/foot	Eczema Tinea Pustular psoriasis	Scale, crust, microvesicles NE Mixed dermal infiltrate
#6: 49 years/female/palm	Tinea Eczema tyloiticum	Compact keratin Focal scale, crust SS Perivascular lymphocytic infiltrate
#7: 27 years /male/shin	Eczema Pustular psoriasis	Scale, crust PPDE Superficial and deep mixed infiltrate
#8: 33 years/female/palm	Eczema Tinea Pustular psoriasis	Scale, crust, numerous hyphae NE Superficial lymphocytes Hyphae on H&E staining
#9: 27 years/female/face	DLE	Basket weave and compact keratin Superficial and deep mixed infiltrate
#10: 38 years/female/face	Leishmaniasis DLE	Basket weave and compact keratin SS Superficial and mid-dermal mixed infiltrate
#11: 68 years/male/glans penis	Erythroplasia of Queyrat	Scale, crust with numerous hyphae Subcorneal pustule NE Mixed infiltrate Hyphae on H&E staining
#12: 27 years/male/palm	AIDS Ofuji's Disease	Scale crust with numerous hyphae NE Superficial and deep infiltrate with eosinophils and neutrophils Hyphae on H&E staining

H&E: hematoxylin-eosin; NE: neutrophils in the epidermis; PPDE: prominent papillary dermal edema; SS: sandwich sign; DLE: discoid lupus erythematosus

severe forms. In the majority of cases, superficial fungal infections may present with spongiotic, psoriasiform, vasculopathic and folliculitis/perifolliculitis histopathological reaction patterns. However, non-typical microscopic findings were

recently described: lichenoid, vesiculobullous acantholytic and eosinophilic folliculitis (4-8).

The presence of neutrophils in the epidermis/corneal layer, is the most frequently reported symptom that was considered as the

Table 2. Histopathological reactions and indicators in 12 patients with PAS-positive tinea

Histopathological reaction patterns	Number of cases	Histopathological indicators	Number of cases
Superficial perivascular dermatitis	1	Neutrophils in the epidermis	8
Spongiotic pattern	7	Sandwich sign	3
Psoriasiform pattern	3	Basket weave hyperkeratosis	2
Folliculitis and perifolliculitis	1	Prominent papillary dermal edema	2

specific sign in the diagnosis of dermatophytoses for a long time. Meymandi et al. reported intraepidermal presence of neutrophils in 63% of tinea infection cases, and in 41% of psoriasis or eczema cases, the difference was not statistically significant (11). Al-Amiri et al. reported this histopathological finding in 28% of tinea cases. In our study, the presence of neutrophils in the epidermis represented the most frequent histopathological indicator, found in 8/12 (66%) of all PAS positive cases.

Prominent papillary dermal edema (PPDE) may occur in various dermatologic conditions: polymorphous light eruptions, arthropod bite reactions, Sweet syndrome, erysipelas, perniosis, lichen sclerosus et atrophicus (early stages) (15). Hoss et al. reported 16 cases of tinea associated with PPDE (15). All 16 cases occurred in the extremities of female patients. The authors proposed that lesions with PPDE should be strongly considered in the differential diagnosis of dermatophytoses. In our series, PPDE was found in two cases of tinea corporis.

In our study, the “sandwich” sign, which is a typical histopathological clue for skin fungal infections was present only in 3 (25%) cases. In a similar study it was reported in 12% of all studied cases (3).

These results show that histopathological H&E stained slides are not reliable histopathologic

parameters for establishing the diagnosis of dermatophytoses. Our study confirms that the presence of neutrophils in epidermis represents the most common histopathological diagnostic clue for fungal skin infections.

Conclusion

Histopathological analysis is of great benefit in the diagnosis of dermatophytoses and represents a substantial adjuvant diagnostic method. PAS staining represents a relatively cheap and simple fungal-specific staining. It has been suggested that this method not only confirms that the selected material is actually invaded, but also reduces the number of false-negative reports, where fungi are cultured from a microscopically negative specimen. Despite a low prevalence of positive findings, our results justify the need for routine PAS staining of all clinically and histologically non-specific inflammatory skin conditions.

References:

1. Hinshaw M, Longley BJ. Fungal diseases. In: Elder DE, Elenitsas R, Johnson BL, Murphy GF, editors. *Lever's histopathology of the skin*. Philadelphia: Lippincott Williams and Wilkins; 2004. p. 603.
2. Lawry MA, Haneke E, Strobeck K, Martin S, Zimmer B, Romano PS. Methods for diagnosing onychomycosis: a comparative study and review of the literature. *Arch Dermatol* 2000;136(9):1112-6.
3. Al-Amiri A, Chatrath V, Bhawan J, Stefanato CM. The periodic acid-Schiff stain in diagnosing tinea: should it be used routinely in inflammatory skin diseases? *J Cutan Pathol* 2003;30:611.

4. Ziemer M, Seyfarth F, Elsner P, Hipler UC. Atypical manifestations of tinea corporis. *Mycoses* 2007;50(Suppl 2):S31-5.
5. Terragni L, Marelli MA, Oriani A, Cecca E. Tinea corporis bullosa. *Mycoses* 1993;36(3-4):135-7.
6. Sánchez Yus E, Requena L, Simón P, de Hijas CM. Incidental acantholysis. *J Cutan Pathol* 1993;20(5):418-23.
7. Kim HS, Cho BK, Oh ST. A case of tinea corporis purpurica. *Mycoses* 2007;50(4):314-6.
8. Shindo M, Nakashima K, Yoshida Y, Yamamoto O. Trichophyton rubrum infection histologically identical to eosinophilic pustular folliculitis. *Clin Exp Dermatol* 2008;33(4):500-1.
9. Tani K, Adachi M, Nakamura Y, Kano R, Makimura K, Hasegawa A, et al. The effect of dermatophytes on cytokine production by human keratinocytes. *Arch Dermatol Res* 2007;299(8):381-7.
10. Ackerman AB. When you see-think. In: Ackerman AB, editor. *Histologic diagnosis of inflammatory skin diseases*. Philadelphia: Lea and Febiger; 1978. p. 830.
11. Meymandi S, Silver SG, Crawford RI. Intraepidermal neutrophils: a clue to dermatophytosis? *J Cutan Pathol* 2003;30:253.
12. Gottlieb GJ, Ackerman AB. The „sandwich sign“ of dermatophytosis. *Am J Dermatopathol* 1986;8:347.
13. Hoss D, Berke A, Kerr P, Grant-Kels J, Murphy M. Prominent papillary dermal edema in dermatophytosis (tinea corporis). *J Cutan Pathol* 2010;37(2):237-42.
14. Murphy JK, O'Donohue L. The diagnostic value and cost effectiveness of routine fungal stains in a dermatopathology service of a district general hospital. *J Clin Pathol* 2004;57:139-40.
15. Ackerman AB. Polymorphous light eruption. In: Ackerman AB, Chongchitnant N, Sanchez J, Guo J, Bennis B, Reichel M, et al, editors. *Histologic diagnosis of inflammatory skin diseases*. 2nd ed. Baltimore: Williams & Wilkins; 1997. p. 642.

Značaj patohistološkog nalaza u dijagnostici dermatofitoza

Sažetak

Uvod: Patohistološka analiza nije rutinska metoda u dijagnostikovanju gljivičnih oboljenja kože. Gljivice se u patohistološkim preparatima bojenim rutinskim bojama, npr. hematoksilin-eozinom, praktično ne mogu identifikovati, s obzirom da se gljivični elementi, tj. hife, boje bledo plavo (Slika 1). Gljivice postaju vidljive pomoću specijalnih bojenja, npr. *periodic-acid-Shiff* (PAS) bojenje, koje gljivice boji u crveno (Slika 2). Patohistološke promene kod gljivičnih infekcija nisu specifične, analogno kliničkom nalazu (Slika 3). U slučajeve kada je uzeta biopsija sa lezije bez prethodno postavljene sumnje na gljivičnu infekciju kože, poznavanje najčešćih modela patohistoloških reakcija kao i određenih patohistoloških indikatora (tzv. histološki *ključevi* za dijagnozu), kod pojedinih dermatomikoza, npr. dermatofitoza (površinske infekcije kože izazvane dematofitama sinonim tinea), mogu navesti patohistologa da posumnja na gljivičnu infekciju i dodatno uradi specijalno, npr. *periodic-acid-Shiff* (PAS) bojenje za prikazivanje gljivica. Patohistološki modeli. Najčešći modeli patohistoloških reakcija kod dermatofitoza: 1. *superfijalni perivaskulitis*, u kome je inflamatorni proces smešten pretežno oko krvnih sudova u površinskim delovima dermisa i koji je najmanje

specifičan, a može se videti kod velikog broja različitih dermatoloških oboljenja; 2. *spongiotično/ekcemski*, koji je najčešći i za koji su karakteristični spongioza i ekcem; 3. *psorijaziformni*, u kome se prisustvo neutrofilnih granulocita u spinoznom i kornealnom sloju sa formiranjem mikroapscesa praktično ne može razlikovati od eruptivne psorijaze; 4. *folikulitis i perifolikulitis*, u kome gust inflamatorni infiltrat i destrukcija folikula otežavaju detekciju gljivičnih elemenata i u PAS bojenim preparatima (Slika 4); 5. *granulomatozni*, koji se najčešće nalazi kod dubokih gljivičnih infekcija, i koji po pravilnu zahteva obavezno PAS bojenje nezavisno od kliničkog nalaza.

Patohistološki indikatori (*ključevi*): Na preparatima bojenim hematoksilin/eozinom mogu se u pojedinim slučajevima uočiti znaci koji ne samo da pobuđuju sumnju na infekciju izazvanu dermatofitima, nego mogu tačno da ukažu i na mesto na kome se nalaze gljivični elementi: 1. *neutrofilni granulociti u epidermisu* se dovode u direktnu vezu sa dermatofitima i ovaj nalaz se smatra *ključem za dermatofitoze* (Slika 5); 2. *znak „sendviča“*, u kome se u kornealnom sloju nalaze hife, smeštene u pukotini nastaloj između dve lamele, gornje ortokeratotične i donje parakeratotične (slike 6 i 7) - iako se

smatra specifičnim, ovaj znak je izuzetno retko prisutan; 3. *kornealni sloj u vidu pruća na korpici ili kompaktna hiperkeratoza*, nalaz koji se često navodi u funkciji indikatora, ali se praktično viđa u mnogim infekcijama kože koje nisu izazvane dermatofitima; 4. *edem u papilarnom dermu*, koji je karakterističan za gljivičnu upalu kože koja nije obrasla dlakom, tzv. glatke kože. Navedeni modeli i indikatori nisu sami po sebi dovoljni za postavljanje dijagnoze, oni indikuju bojenje datog preparata bojama specifičnim za gljivice.

Cilj: Ispitivanje je imalo za cilj da među svim PAS bojenim biopstatima kože, koji su rađeni tokom šestogodišnjeg perioda, od januara 2004. do decembra 2009. godine, utvrdi prevalenciju PAS-pozitivnih biopstata i da analizira njihove kliničke i patohistološke osobine.

Metod: Retrospektivno su analizirane biopsije sa izvršenim PAS bojenjem. Kod PAS pozitivnih biopsija određivani su sledeći parametri: kliničke karakteristike, modeli patohistoloških reakcija i prisustvo određenih patohistoloških indikatora.

Rezultati: Od 361 PAS-bojenih biopsija, kod 12 (3,3%) je dokazano prisustvo hifa. Kod 5 (1,4%) slučajeva bilo je kliničke sumnje za gljivično oboljenje, a kod 7 (1,9%) radilo se o novoj dijagnozi. Kod 127 od ukupno 361 PAS-bojenih biopsija, nije postojala prethodno postavljena klinička dijagnoza ali ni sumnja da se može raditi o gljivičnoj infekciji kože. U tim slučajevima je PAS bojenje naknadno indikovalo patohistolog. Najčešći model patohistološke reakcije bio je spongiotični, a najčešći patohistološki indikator, nalaz neutrofila u epidermu.

Zaključak: Dobijeni rezultati u ovom ispitivanju potvrđuju da se dermatofitoze, mogu prezentovati sa klinički i histološki nespecifičnim nalazima. PAS bojenje je relativno jeftina i jednostavna metoda za bojenje gljivica. I pored malog procenta pozitivnih nalaza, s obzirom na finansijsku opravdanost svake neočekivano dokazane gljivične infekcije, ova serija podržava potrebu za rutinskom primenom PAS bojenja kod klinički i histološki nespecifičnih inflamatornih dermatoza.

Psoriatic onycho-pachydermo-periostitis

Zorica PERIĆ-HAJZLER, Lidija KANDOLF-SEKULOVIĆ, Lidija ZOLOTAREVSKI

¹Department of Dermatology and Venereology, Military Medical Academy, Belgrade

²Institute of Pathology, Military Medical Academy, Belgrade

*Correspondence: Lidija KANDOLF-SEKULOVIĆ, E-mail: sekulovi@eunet.rs

UDC 616.517:616.72-002

Abstract

Psoriatic onycho-pachydermo-periostitis has been recognized as an uncommon subset of psoriatic arthritis, and to date, only a few cases have been reported. In general, psoriatic onycho-pachydermo-periostitis is regarded as a unique variant of psoriatic arthritis, but its pathology and pathophysiology are not well understood. Although psoriatic onycho-pachydermo-periostitis is usually found in patients with psoriasis, it can also be found in patients without psoriatic skin lesions. It is characterized by psoriatic nail changes (usually onycholysis), painful swelling of the soft tissue close to the distal phalanges, and radiographic changes of the distal phalanges with periosteal reaction and bone erosions. We present a 58-year-old man with a 3-year history of deformation, thickened nails and pustules on the skin of his fingers and toes, and painful redness of the nail bed accompanied with pain in small joints. The family history was negative. After confirmation of the diagnosis, methotrexate: 15 mg weekly, was initiated which led to symptoms improvement. Treatment of psoriatic onycho-pachydermo-periostitis is difficult. It is based on treatment modalities used for other forms of psoriatic arthritis, such as sulphasalazine, methotrexate, and anti-tumor necrosis factor antibody therapy with adalimumab and etanercept. Nonsteroidal anti-inflammatory drugs are usually ineffective. Retinoids, subungual cyclosporine and corticosteroid therapy also showed inefficient. In our patient, methotrexate has shown efficacy in symptom improvement.

Nail psoriasis is a common condition, particularly in patients with joint involvement. In psoriatic arthritis, distal interphalangeal joints are most frequently affected, but in some cases periphallangeal soft (connective) tissue thickening above the distal phalanges, including periosteal reaction, is present as well. Psoriatic arthritis has a significant negative impact on patient's quality of life, affecting physical activities, as well as emotional and social well being. Psoriatic onycho-pachydermo-periostitis is a recently described variant of psoriatic arthritis. It is characterized by psoriatic nail changes (usually onycholysis), painful swelling of the soft tissue close to the distal phalanges, and radiographic changes of the distal phalanges showing periosteal reaction and bone erosions (1). The disease is often refractory to treatment, and available therapeutic agents affect the nail-bed matrix with variable success.

Case report

We present a 58-year-old man, who was first admitted to our hospital in 2008, with a 3-year history of deformation, thickened nails and pustules on his fingers and toes, and recent painful redness of the nail bed, accompanied with pain in small joints. The family history was negative for similar conditions or skin disorders. Oral antifungal therapy was introduced in another institution, but without response.

Physical examination revealed tender, drumstick-like swelling of all fingers and toes. Bright-red erythema and scaling were observed on the distal area of the digits. The nail plates were partially destroyed with subungual hyperkeratosis (Figure 1 and 2). Arthralgia of the distal interphalangeal joints was present.

Complete blood count, electrolytes and liver-function tests were within normal limits.

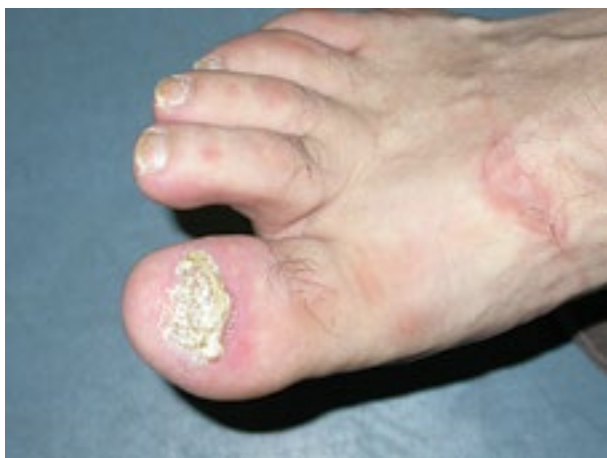

Figure 1. Swelling of the thumb

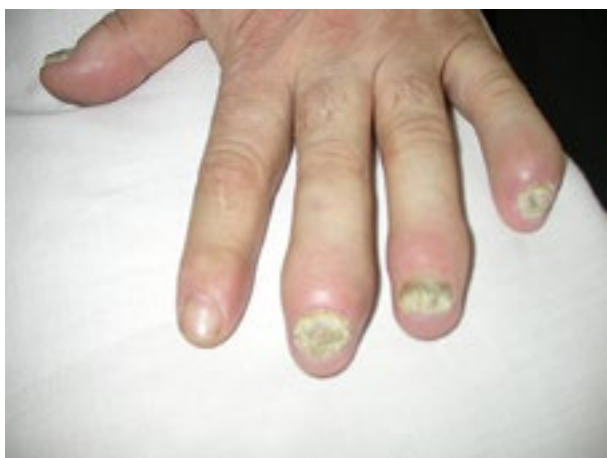

Figure 2. Swelling of the fingers
(drumstick-like fingers)

The rheumatoid factor was negative, direct, native mycological examination and cultures were negative on three occasions. Nail bed biopsy was performed, and a skin sample was sent for histopathological analysis. It revealed parakeratosis and neutrophils forming Munro's abscesses in the corneal layer, features consistent with nail psoriasis (Figure 3). Direct immunofluorescence of skin sections was negative for IgG, IgM, IgA, C3 and fibrinogen deposits.

X-ray examination of hands, feet and sacroiliac joints revealed a preserved articular space width, but pronounced degenerative changes, especially in the distal interphalangeal joints with narrowing most prominent on the third finger of

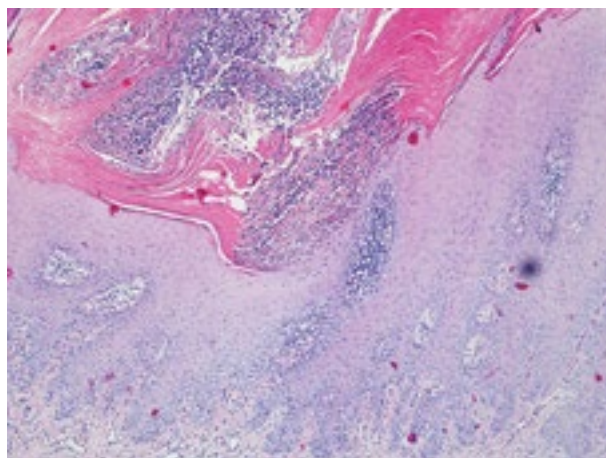


Figure 3. Histopathology analysis of the nail bed biopsy showing parakeratosis, intracorneal neutrophil pustule – Munro's abscess (Hematoxylin and Eosin, x 100)

the left hand. Severe degenerative changes were also present on the distal interphalangeal joints of both thumbs, with preserved articular spaces. A considerable soft tissue swelling was also evident (Figure 4).

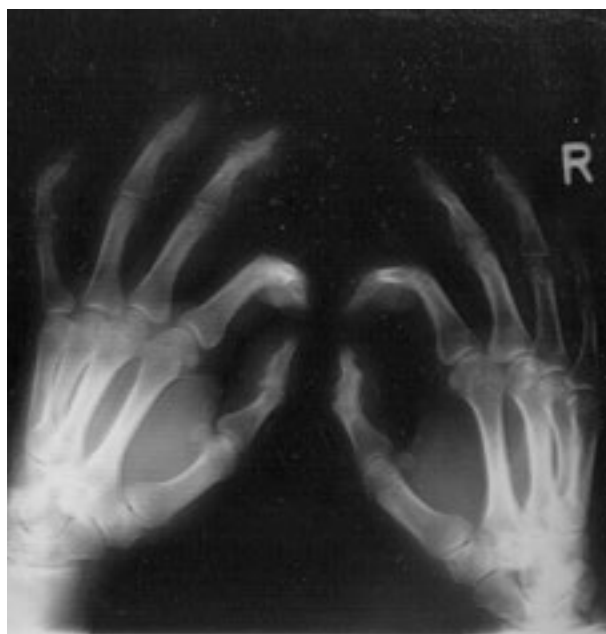

Figure 4. X-ray examination of hands revealing degeneration in the distal interphalangeal joints with narrowing most prominent on the third finger of the left hand, periostitis, swelling of the soft tissue

Based on the above-mentioned findings, the patient was diagnosed with psoriatic onycho-pachydermo-periostitis. After confirmation of the diagnosis, methotrexate therapy, 15 mg weekly, was initiated, which led to symptoms improvement.

The first control examination revealed a regression of erythema and desquamation on all fingers and toes. The pain was also significantly reduced. The treatment was continued with regular monitoring of the liver function. After three months of treatment, the pain was completely absent in the distal interphalangeal joints, and there were no new lesions on the nail plates. During the next six months, the dose was gradually reduced to 7.5 mg 1x a week, while maintaining good treatment outcome.

Discussion

Psoriatic onycho-pachydermo-periostitis was described by Fournier et al. in 1989 (1). It involves psoriatic onycho-dystrophy and connective tissue thickening above the distal phalanges, including periosteal reaction. Psoriatic onycho-pachydermo-periostitis can be extremely painful. Thumbs are most commonly involved, but psoriatic onycho-pachydermo-periostitis may involve other digits as well.

Given the lack of distal joint involvement, but common nail involvement, bone changes in psoriatic onycho-pachydermo-periostitis are hypothesized to be caused by spread of inflammation from subungual dermis to the bone. The fibrous septum, which directly joins the subungual dermis and the distal phalanx and projects into the bone, may provide a route for the transmission of inflammation. Although psoriatic onycho-pachydermo-periostitis is usually seen in patients with psoriasis, it can also be found in patients without psoriatic skin lesions. It has been recognized as an uncommon subset of psoriatic

arthritis and, to date, only a few cases have been described (1 - 4). In general, psoriatic onycho-pachydermo-periostitis is regarded as a unique variant of psoriatic arthritis, but its pathology and pathophysiology are not well understood.

The treatment of psoriatic onycho-pachydermo-periostitis is difficult. It is based on several treatment options, currently used for other forms of psoriatic arthritis, such as sulfasalazine, methotrexate, and anti-tumor necrosis factor antibody therapy with adalimumab and etanercept (3, 5). Nonsteroidal anti-inflammatory drugs are mostly ineffective. Retinoids, subungual cyclosporin and corticosteroid therapy are also inefficient. In our patient, methotrexate has shown efficacy regarding symptoms improvement.

Conclusion

Psoriatic onycho-pachydermo-periostitis is a recently described variant of psoriatic arthritis, which can be manifested in patients with or without other manifestations of psoriasis. Although there are no consistent data of satisfying therapy, and no guidelines in the treatment of this condition, all treatment options currently used for other forms of psoriatic arthritis may be of therapeutic benefit (3).

References:

1. Fournie B, Viraben R, Durroux R, Lassoued S, Gay R, Fournie A. Psoriatic onycho-pachydermo-periostitis of the big toe: anatomo-clinical study and physiopathogenic approach apropos of 4 cases. *Rev Rheum Mal Osteoartic* 1989;56:579-82.
2. Boisseau-Garsaud AM, Beylot-Barry M, Doutre MS, Beylot C, Baran R. Psoriatic onycho-pachydermo-periostitis: a variant of psoriatic distal interphalangeal arthritis? *Arch Dermatol* 1996;132(2):176-80.
3. Bauza A, Redondo P. Psoriatic onycho-pachydermo-periostitis: treatment with methotrexate. *Br J Dermatol* 2000;143:892-918.
4. Williamson L, et al. Extended report: nail disease in psoriatic arthritis: clinically important, potentially treatable and often overlooked. *Rheumatology* 2004;43(6):790-4.
5. Dans M, Hivnor C, van Voorhees AS. Psoriatic onychopachydermoperiostitis: improvement with etanercept. *Br J Dermatol* 2005;153(4):858-9.

Psoriatični onihopahidermoperiostitis

Sažetak

Uvod: Psorijaza često zahvata nokte, što se naročito često dešava kod artropatskog oblika psorijaze. U psorijatičnom artritisu najčešće su zahvaćeni distalni interfalangealni zglobovi, ali se u pojedinim slučajevima može javiti zadebljanje perifalangealnog mekog tkiva uz reakciju periosta. Psorijatični artritis u velikoj meri narušava kvalitet života obolelih, utičući na njihove fizičke, emocionalne i socijalne aktivnosti. Psorijatični onihopahidemoperiostitis je poseban oblik psorijatičnog artritisa, u kome postoje promene na noktima, najčešće oniholiza, bolno oticanje mekih tkiva oko distalnih falangi, uz prisustvo radiografski vidljivih promena na distalnim falangama u vidu periostne reakcije i erozija na kostima. Bolest je obično refrakтерна na primenjene terapijske modalitete.

Prikaz slučaja: Prikazujemo redak oblik psorijatičnog onihopahidermoperiostitisa kod pedesetosmogodišnjeg muškarca. Prvi put se javio kod nas na pregled 2008. godine sa anamnestičkim podacima o trogodišnjem prisustvu deformisanih, zadebljanih noktiju, pojavi sitnih gnojnih plikova na prstima obe šake i stopala, crvenilu i bolnosti malih zglobova. Pacijent nije dao podatke o srodnicima obolelim od psorijaze. Antimikotični lekovi koje je pacijent uzimao peroralno u prethodnom periodu nisu doveli do poboljšanja. Fizičkim pregledom pokazao je osetljivost, otok i izgled sličan palici na dobošu svih prstiju stopala i šaka. Distalni delovi prstiju bili su eritematozni i sa prisutnom deskvamacijom. Pored subungvalnih hiperkeratoza, nokatne ploče su pokazivale znake distrofije, a na nekim mestima su i nedostajale (slike 2 i 3). U distalnim interfalangealnim zglobovima šaka pacijent je osećao bol. Sve rutinske hematološke i biohemijske analize uključujući i reuma faktor bile su u granicama referentnih vrednosti. Uzorci izmenjenog tkiva u tri navrata su pregledani u nativnom mikroskopskom preparatu i u kulturi, ali nije potvrđeno prisustvo gljivične

infekcije. Patohistološka analiza isečka uzetog sa nokatnog krevca je pokazala promene koje se vide kod psorijaze noktiju, postojanje parakeratoze i neutrofilnih granulocita, koji su formirali u kornealnom sloju *Munro* apscese (Slika 2). Uzorci izmenjenog tkiva su pregledani u direktnom fluorescentnom mikroskopskom preparatu ali nije potvrđeno postojanje imunskih depozita.

Radiološki se na zglobovima šaka, stopala i sakroilijačnim zglobovima uočavala očuvana širina artikularnog prostora, uz vidljivo izražene degenerativne promene na distalnim interfalangealnim zglobovima sa suženjima naročito uočljivim na trećem prstu leve šake. Jako izražene degenerativne promene u distalnim interfalangealnim zglobovima uz očuvan artikularni prostor bile su prisutne na oba palca stopala, uz evidentan otok mekih tkiva oko distalnih falangi (Slika 3). Na osnovu gorenavedenih analiza, postavljena je dijagnoza psorijatičnog onihopahidermoperiostitisa. Pacijent je započeo lečenje metotreksatom u dozi od 15 mg nedeljno, nakon čega je usledilo kliničko poboljšanje.

Na prvom kontrolnom pregledu, uočena je regresija eritema i deskvamacije svim prstima šake i stopala. Osećaj bola je bio značajno smanjen. Lečenje je nastavljeno uz redovne laboratorijske kontrole funkcije jetre. Nakon tri meseca lečenja, osećaj bola je u potpunosti nestao na nivou distalnih interfalangealnih zglobova i nije dolazilo do pojave novih promena na nokatnim pločama. U toku narednih 6 meseci, doza leka je postepeno snižavana do 7,5 mg u jednoj dozi nedeljno uz očuvan dobar terapijski efekat.

Diskusija: Psorijatični onihopahidemoperiostitis prvi put je opisao 1989. godine Fournier sa saradnicima. Karakterišu ga promene na noktima, najčešće oniholiza, bolno oticanje mekih tkiva oko distalnih falangi i radiografski vidljiva periostna reakcija i erozije na kostima distalnih falangi.

Najčešće su zahvaćeni palčevi na stopalima, ali mogu biti zahvaćeni i svi ostali prsti stopala i šaka. Bolest je peaćena jakim osećajem bola, Iako se najčešće javlja kod obolelih od psorijaze, može da se javi i bez vidljivih psorijatičnih promena na koži. Oboljenje ima nedovoljno razjašnjenu etiologiju i patofiziologiju, ali smatra se da predstavlja poseban oblik psorijatičnog artritisa. Do sada je u svetskoj literaturi objavljen mali broj slučajeva. Pretpostavlja se da se zbog poštete distalnih interfalangealnih zglobova i postojanja promena na noktima, inflamacija sa subungvalnog dermisa preko fibroznih septuma prenosi na koštano tkivo. Bolest je obično

tvrdokorna na primenjene terapijske modalitete koji deluju na matriks nokatnog kreveca, sa promenljivim terapijskim efektom, a koji se primenjuju za lećenje psorijatičnog artritisa: sulfasalazin, metotreksat, anti-tumor nekrozis faktor alfa antitela, adalimumab i etanercept. Lećenje retinoidima, subungvalno aplikovanim ciklosporinom, kortikosteroidima i nesteroidnim antiinflamatornim lekovima ne pokazuje željeni terapijski odgovor.

Zaključak: Prikazujemo slučaj retke terapijski tvrdokorne kliničke varijante psorijatičnog artritisa, u kome je primena metotreksata dovela do kliničkog poboljšanja.

Thevenard's Disease - a hereditary sensory and autonomic neuropathy type I

Borut Nikolić^{1*}, Milan Mišović¹, Miodrag Zorić², Dušica Matović¹, Aleksandra Aleksić¹

¹Department of Dermatology and Venereology, Military Medical Academy, Belgrade

²Department of Orthopedics and Traumatology, Military Medical Academy, Belgrade

*Correspondence: Borut Nikolić, E- mail: borutbn@yahoo.com

UDC 616.5-002.4-056.7:616.833]-07/-08

Abstract

Thevenard's Disease is a rare, hereditary sensory and autonomic neuropathy which leads to hyperkeratotic and ulcerative lesions of the feet. We present two patients, a father and son, 39 and 18 years of age, in whom the disease first manifested in adolescence. Plantar hyperkeratosis and trophic, painless ulcerations occurred first, with subsequent feet deformities. Neurological and radiological findings pointed to chronic demyelination, polyneuropathy with damage to sensory fibers. Differential diagnosis and treatment options are discussed.

Hereditary sensory and autonomic neuropathy type I (HSAN I), i.e. Thevenard's disease, is a dominant hereditary sensorimotor, axonal neuropathy which usually develops in the second (rarely later) decade of life, without autonomic disorder. It may be classified both as a genetic and a clinical heterogeneous disease with sensory dysfunction. Type I HSAN was firstly described by Nelaton (1) in 1852, and by Thevenard (2) in "L'acropathie ulcero-mutilante familiale" that is familial ulcerative mutilating acropathy, a name used up to now. We present two patients (a father, and son) with HSAN I.

Case 1

A 39-year-old man was admitted due to a painless ulceration on the right plantar foot (Figure 1). The onset of the disease occurred at the age of 17, with hyperkeratosis on the right plantar foot at the level of metatarsophalangeal (MTP) joints. Due to hammer-like toe deformities and aggravated walking ability when the patient was 18, amputation of the 2nd and 3rd toes of the right foot, including pertaining methatarsal

bones, was performed, while at the age of 20, the great toe distal phalanges were amputated. The following year distal phalanges of the 1st, and 2nd toe of the left foot were amputated. The disease progressed with a reduced pain and loss of temperature sensation, foot edema, formation of hallux on both sides, and a painless ulceration on the right foot sole. On two occasions, when the patient was 33 and 34-years old, a reconstructive surgery using a rotation flap was attempted to

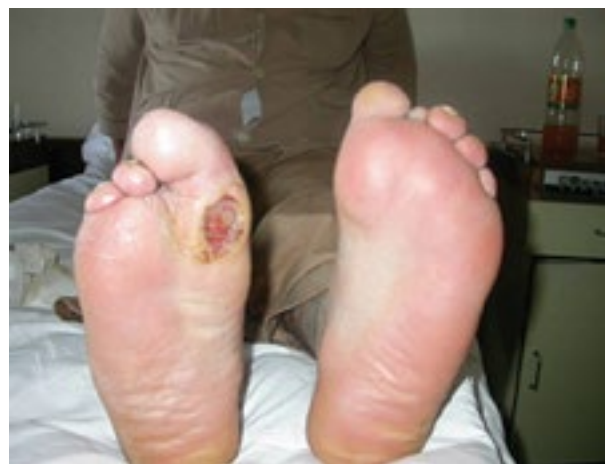

Figure 1. Right plantar foot ulceration

manage the ulcer, but without success. Routine laboratory tests showed that all the examined parameters were within the range of normal, including glucose, ESR 14 mm/h. Serology for lues was negative. Radiography of the feet revealed visible amputation of the middle and distal phalanges of the 2nd toe and distal phalange of the great toe of the left foot; amputation of the 2nd and 3rd toes of the right foot including a part of the pertaining methatarsal bones (Figure 2). Doppler ultrasonography of the lower extremities showed a normal finding for the arteries and deep veins, while valvular stenosis of the left greater saphenous vein was observed. The neurophysiologic examination (EMNG) suggested a chronic, axonal, sensomotoric, medium severe polyneuropathy.

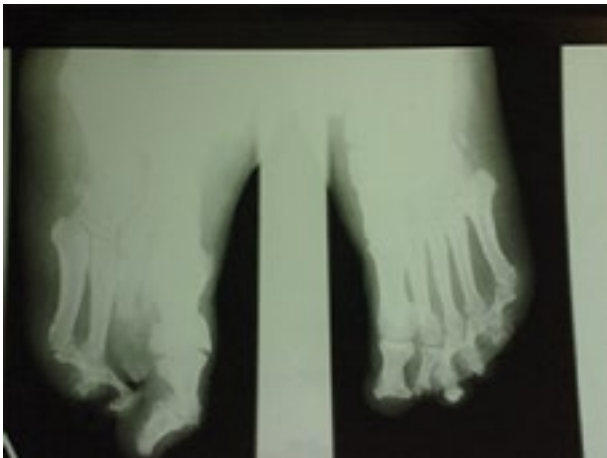

Figure 2. Radiography of the feet: amputation of the middle and distal phalanges of the 2nd toe and distal phalange of the great toe of the left foot. Right: amputation of the 2nd and 3rd toes of the right foot, including and pertaining phalanges of both toes

Case 2

The son of the above patient, aged 18, was also admitted due to plantar ulcer. The onset of the disease occurred when the patient was 17, with hyperkeratosis on the left foot sole at the level of MTP I joint, where a deep painless ulceration developed (Figure 3). At the age of 19, resection of the 2nd methatarsal bone bulb releasing the

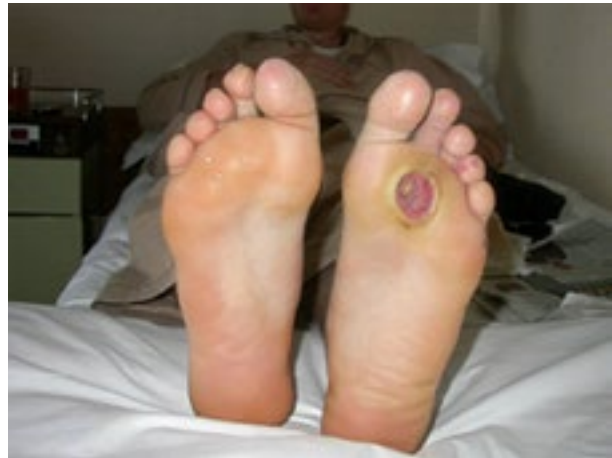

Figure 3. Left foot sole deep ulceration

tendon due to the flexion finger contour was done, as well as ulcer reconstruction, but this was ineffective and chronic ulcer developed again.

Laboratory findings showed no pathology, ESR 16 mm/h, VDRL and TPHA were negative. Radiography of the feet revealed normal bone structures. Doppler ultrasonography of the lower extremities showed normal findings except for a decreased blood flow through the arteries of both feet soles. EMNG examination revealed absence of sensory action in both tibial, median, and ulnar nerves to the right.

Discussion

Hypersensitive sensory and autonomic neuropathies (HSANs) or hypersensitive sensory neuropathies (HSNs) are genetically defined neuropathies which are classified into five types (HSAN I-V) (3). Type I is the most common form where sensory neurons and their small fibers are primarily affected (4). The disease is caused by the mutation of the gene SPTLC 1, which codes a long strain of a basic subunit 1 serine palmitoyl transferase (SPTLC 1) at the chromosome 9q 22.1 - q 22.3 (5). Patients show rise of *de novo* synthesis of glycosylceramidase in lymphoblasts that results in abnormal neuronal apoptosis (6-8). Some more recent studies suggest that this mechanism is not present in every patient, as well

as that the development of the disease is affected by gene expression, so that the clinical presentation may be less severe and the disease may occur later in life (9). The disease usually manifests in the second or third decade of life. Sensory alterations cause consequential hyperkeratosis, mutilating acropathy, and painless plantar ulcerations. Except for the loss of pain sensation, temperature sensation is also damaged. Achilles reflex is weak or absent. Motor dysfunction of various degrees may be present (10). The anal sphincter function and sexual ability are preserved. The disease progresses with frequent episodes of osteomyelitis, sequestrations, acroosteolysis leading to sole mutilation (10).

By phenotype, HSAN I is similar to Charcot-Marie-Tooth (CMT) 2B, a disease mediated by RAB7 gene mutation, and with more pronounced motoric disorders (11). Recently a new form has been described, namely the so-called HSAN I B which, besides neuropathy, includes a frequent occurrence of cough and gastroesophageal reflux (12).

HSAN II is an autosomal, recessive, hereditary disease. It starts in early childhood, affects extremities, and it is characterised by loss of sensory functions, ulcerations, spontaneous amputation, atrophy, hyporeflexia (11,13). It is a consequence of HSN2 gene mutation at the chromosome 12q 13.33 (14,15).

HSAN III (familial dysautonomia, Riley-Day syndrome) is an autosomal recessive hereditary disease frequently associated with the Eastern Europe Ashkenazi Jews. It presents at birth with insensitivity to pain and temperature, cardiovascular damage, pneumonia, vomiting, gastrointestinal tract dysfunction with frequent episodes of hypertension. Diagnostic criteria include absence of fungiform papillae on the tip of the tongue and pathologic histamine test. The disease is a consequence of IKBKAP gene mutation at the chromosome 9q 31 (16,17).

HSAN IV is also an autosomal recessive hereditary disease associated with NTRK1 gene mutation at the chromosome 1q 21 – q 22. The affected patients have an innate insensitivity to pain, anhidrosis, mental retardation, frequent febrile episodes (11,18).

In these patients, eccrine sweat glands are not innervated (19). Early death happens in approximately 20% of children.

HSAN V (20) is similar to the type IV, the major difference being in less pronounced anhidrosis and absence of mental retardation (11). A possible pathogenic mechanism is a mutation of the gene that codes the beta nerve growth factor (BNGF) at the chromosome 1p 11.2 - p 13.2. We also took into consideration a special disease (maybe a new type of HSAN VI) already presented in elderly Japanese siblings (in three of six family members), including anosmia, anhidrosis and loss of sensoric functions, orthostatic hypotension, but without ulcerations (21).

In differential diagnosis, leprosy, syringomyelia, hereditary motoric and sensory neuropathy (HMSN) must be considered, which are predominantly motoric neuropathies of slow and rapid progression, as well as Fabry's Disease, and Lesch Nyhan's Syndrome, porphyria (primarily motoric neuropathy) (22). Also, acquired ulceromutilational acropathy may be considered when caused by alcoholism, cigarette smoking and it usually develops later in life. Letic neuropathy (dorsalis tibiae), diabetic polyneuropathy and acropathy were also excluded.

We presented two patients with a rare disease, in whom the diagnosis was made based on the anamnesis, clinical presentation, slow progression of the disease and neurophysiologic findings. The therapy is symptomatic. Attention should be paid to the care of the feet and wearing comfortable, anatomic footwear. Also, corrective surgery is advised in advanced cases.

References

- Nelaton A. Asection singuliere des os du pied. *Gaz Hop Civ Milit* 1852;4:13.
- Thevenard A. L'acropathie ulcero-mutilante familiale. *Rev Neurol* 1942;74:193-212.
- Dyck P, Chance P, Lebo R, Carney J. Hereditary motor and sensory neuropathies. In: Dyck PJ, Griffin JW, Low P, Poduslo JF, eds. *Peripheral neuropathy*. 3rd ed. Philadelphia: WB Saunders; 1993. p. 1094-136.
- Houlden H, King R, Blake J, Groves M, Love S, Woodward C, et al. Clinical, pathological and genetic characterization of hereditary sensory and autonomic neuropathy type I (HSAN I). *Brain* 2006; 129(2):411-25.
- Nicholson GA, Dawins JL, Blair IP, Kenerson ML, Gordon MJ, Cherryson AK, et al. The gene for hereditary sensory neuropathy type I (HSN-I) maps to chromosome 9q 22.1 - q 22.3. *Nat Genet* 1996;13:101-4.
- Verhoeven K, Coen K, de Vriendt E, Jacobs A, Van Gerwen V, Smout I, et al. SPTCLC 1 mutation in twin sisters with hereditary sensory neuropathy type I. *Neurology* 2004;62:1001-2.
- Bejaoui K, Wu C, Scheffler MD, Haan G, Ashby P, Wu L, et al. SPTLC 1 is mutated in hereditary sensory neuropathy, type 1. *Nat Genet* 2001;27:261-2.
- Dawkins JL, Hulme DJ, Brohmbhatt SB, Auer-Grumbach M, Nicholson GA. Mutations in SPTLC 1, encoding serine palmitoyltransferase, long chain base subunit-1, cause hereditary sensory neuropathy type 1. *Nat Genet* 2001;27:309-12.
- Klein CJ, Wu J, Kruckeberg KF, Hebring SJ, Anderson SA, Cuningham SJ, et al. SPTLC 1 and RAB 7 mutation analysis in dominantly inherited and idiopathic sensory neuropathies. *J Neurol Neurosurg Psychiatry* 2005;76:1022-4.
- Dyck PJ. Neuronal atrophy and degeneration predominantly affecting peripheral sensory and autonomic neurons. In: Dyck PJ, Thomas PK, Griffin JW, Low PA, Poduslo JF, eds. *Peripheral neuropathy*. Philadelphia: WB Saunders; 1933. p. 1065-93.
- Houlden H, Blacke J, Reilly MM. Hereditary sensory neuropathies. *Curr Opin Neurol* 2004;17: 569-77.
- Kok C, Kennerson ML, Spring PJ, Ing AJ, Pollard JD, Nicholson GA. A locus for hereditary sensory neuropathy with cough and gastroesophageal reflux on chromosome 3p 22 - p 24. *Am J Hum Genet* 2003;73:632-7.
- Bosch P, Smith B. Disorders of peripheral nerves. In: Bradley WG, Danoff R, Fenichel G, Marsden D, eds. *Neurology in clinical practice*. 3rd ed. Guilford: Butterworth Heinemann; 2000. p. 2069-71.
- Lafreniere RG, MacDonald ML, Dube MP, MacFarlane J, O'Driscoll M, Brais B, et al. Identification of a novel gene (HSN2) causing hereditary sensory and autonomic neuropathy type II through the Study of Canadian Genetic Isolates. *Am J Hum Genet* 2004;74:1064-73.
- Coen K, Pareyson D, Auer-Grumbach M, Buyse G, Goemans N, Claey's KG, et al. Novel mutations in the HSN2 gene causing hereditary sensory and autonomic neuropathy type II. *Neurology* 2006;66:748-51.
- Riley CM, Day RL, Greeley DMcl, Langford WS. Central autonomic dysfunction with defective lacrimation. *Pediatrics* 1949;3:468-77.
- Axelrod FB. Familial dysautonomia. *Muscle Nerve* 2004;29:352-63.
- Indo Y, Tsuruta M, Hayashida Y, Karim MA, Ohta K, Kawano T, et al. Mutations in the TRKA/NGF receptor gene in patients with congenital insensitivity to pain with anhidrosis. *Nat Genet* 1996;13:485-8.
- Nolano M, Crisci C, Santoro L, Barbieri F, Casale R, Kennedy WR, et al. Absent innervation of skin and sweatglands in congenital insensitivity to pain with anhidrosis. *Clin Neurophysiol* 2000;111:1596-601.
- Dyck PJ, Mellinger JF, Reagan TJ, Horowitz SJ, McDonald JW, Litchy W, et al. Not "indifference to pain" but varieties of hereditary sensory and autonomic neuropathy. *Brain* 1983;106:373-90.
- Einarsdottir E, Carlsson A, Minde J, Toolanen G, Svensson O, Solders G, et al. A mutation in the nerve growth factor beta gene (NGFB) causes loss of pain perception. *Hum Molec Genet* 2004;13:799-805.
- Jacob A, Savada C, Thomas SV. Painless injuries in child: Hereditary sensory and autonomic neuropathy. *Ann Indian Acad Neurol* 2006;9:39-41.

Thevenardova bolest - nasledna, senzorna i autonomna neuropatija tipa I

Sažetak

Uvod: Nasledna neuropatija tip I, Thevenardova bolest predstavlja dominantno naslednu aksonsku (senzornu i autonomnu) neuropatiju koja se najčešće javlja u drugoj deceniji života. Na osnovu etiopatogenetskih i kliničkih karakteristika, ubraja se u heterogenu grupu bolesti koju karakterišu senzorni (disfunkcionalni) poremećaji. Nelaton

je 1850. godine prvi opisao ovu bolest. Thevenard je bolest okarakterisao kao hereditarnu ulceromutilantnu akropatiju, te se ona i danas opisuje pod tim nazivom.

Prikaz slučaja: U radu su prikazana dva slučaja porodičnog javljanja ovog oboljenja. Kod oca, tridesetdevetogodišnjeg muškarca, bolest se javila

u sedamnaestoj godini života u vidu hiperkeratoze na tabanu levog stopala i to u nivou metatarzo-falangealnih zglobova. Već u osamnaestoj godini amputiran mu je drugi i treći prst na desnom stopalu uključujući i odgovarajuće metatarzalne kosti. Bolest je poprimila progresivan tok, pa je u dvadesetoj godini amputirana distalna falanga na palcu desnog stopala. Navedene promene su otežavale još više hod, prsti na stopalu su poprimali izgled čekića, ulceracija na tabanu se povećavala kao i otok čitavog stopala. Senzorne funkcije u smislu percepcije bola i temperature su se smanjivale do potpunog gubitka. U dva navrata, tokom četvrte decenije života, na pacijentu je izvršena rekonstruktivna hirurška intervencija sa rotacionim režnjem radi sanacije ulkusa na tabanu desnog stopala. Na prijemu, svi laboratorijski nalazi bili su u granicama normale, uključujući i serološke reakcije na sifilis. Radiografskim snimkom utvrđeno je: odsustvo srednje i distalne falange drugog prsta i distalne falange palca na levom stopalu; nedostatak drugog i trećeg prsta desnog stopala uključujući i deo metatarzalnih kostiju. Ultrasonografski je isključeno postojanje insuficijencije arterijskih krvnih sudova kao i dubokih vena na donjim ekstremitetima. Elektromioneurografija je ukazala na postojanje hronične, aksonske senzorno-motorne polineuropatije srednjeg stepena težine. U drugom prikazanom slučaju, kod sina prethodno opisanog pacijenta, bolest je počela u sedamnaestoj godini života. Kao osamnaestogodišnji mladić, primljen je prvi put na bolničko lečenje da bi se sanirala ulceracija koja se razvila iz hiperkeratotičnog zadebljanja na levom stopalu. Već u devetnaestoj godini kod njega je urađena resekcija na nivou druge metatarzalne kosti sa oslobađanjem tetive (fleksiona kontraktura prsta), kao i rekonstrukcija postojeće ulceracije. Sprovedena terapija nije urodila plodom, s obzirom da se u daljem periodu ponovo razvila hronična ulceracija na istom mestu. Objektivnim pregledom, uočena je

duboka bezbolna ulceracija na nivou baze prvog metatarzo-falangealnog zgloba na levom stopalu. Svi laboratorijski nalazi su bili u granicama normale. Radiografija stopala je otkrila očuvanost strukture koštanog tkiva. Ultrazvučni pregled je ukazivao na usporenu arterijsku cirkulaciju na nivou oba stopala. Elektromioneurografskim pregledom uočeno je senzorno oštećenje na nivou: n. *tibialis* obostrano, n. *medianus* desno i n. *ulnaris* desno.

Diskusija: Pod hipersenzitivnim senzornim i autonomnim neuropatijama podrazumeva se heterogena grupa naslednih neuropatija koje su iz didaktičkih razloga klasifikovane u pet fenotipova. Prvi tip je najčešći i u njemu su primarno izmenjeni senzorni neuroni. Do oštećenja senzornih neurona dolazi usled mutacije gena SPTLC 1 (eng. *serine palmitoyl transferase-long chain*) koji je smešten na 9q 22.1 - q 22.3 i koji je odgovoran za sintezu serin-palmitoil transferaze. Posledično dolazi do *de novo* sinteze glikozilceramida i do proliferacije limfoblasta koji su odgovorni za apoptozu neurona. Novija istraživanja ukazuju da je stepen ekspresivnosti genetskog poremećaja odgovoran za čitav dijapazon različitih kliničkih manifestacija. Senzorni poremećaji rezultuju hiperkeratozom, mutilacionom akropatijom i bezbolnim plantarnim ulceracijama. Dolazi do oštećenja osećaja toplote, do smanjenja ili potpunog odsustva Ahilovih refleksa, kao i do disfunkcijskih motornih poremećaja različitog stepena. Funkcija sfinktera i seksualna aktivnost ostaju očuvani. Bolest pokazuje progredijentan tok pa se često razvijaju osteomijelitis sa sekvestracijom koštanog tkiva i akroosteolizom, koja vodi ka teškim mutilacijama stopala.

Diferencijalna dijagnoza: U diferencijalnoj dijagnozi treba uzeti u obzir *Charcot-Marie-Tooth* bolest, do koje dolazi usled mutacije na RAB 7 genu i kod koje su motorni poremećaji značajno jače izraženi. U odnosu na ostala četiri fenotipa (II-V), diferencijalno-dijagnostički drugi tip koji se nasleđuje autozomno recesivno (mutacija na

HSN2 genu, smeštenom na hromozomu 12q 13.33) karakterišu poremećaji koji se javljaju već u ranom detinjstvu a mogu da zahvataju bilo koji ekstremitet. U trećem tipu (autozomno recesivni *Riley-Day* sindrom) promene su prisutne već na rođenju. Pored oslabljenog osećaja bola i temperature, postoje poremećaji kardiovaskularnog i gastrointestinalnog sistema sa epizodama hipertenzije, povraćanja, čestih pneumonija. Patognomonično je odsustvo filiformnih papila na jeziku i histaminski test. Za nastale promene odgovorna je mutacija na IKBKAP genu smeštenom na hromozomu 9q31. Četvrti fenotipski tip (autozomno recesivna nasledna mutacija na genu NRTK 1, smeštenom na hromozomu 1q 21 – q 22) karakteriše i prisustvo anhidroze, mentalna retardacija i česte febrilne epizode. Usled odsustva inervacije ekrinih znojnih žlezda, kod 20% obolele dece dolazi do smrtnog ishoda. Peti fenotipski tip (verovatno mutacija gena koji kodira sintezu neurogenog faktora rasta β -smeštenog na hromozomu 1p 11.2 - p 13.2) klinički se razlikuje od prethodnog

po odsustvu mentalne retardacije i manje izraženoj anhidrozi. Takođe, diferencijalno-dijagnostički, treba pomišljati i na bolest (šesti fenotip?) koja je opisana kod Japanaca, i to kod tri od šest članova jedne porodice, u vidu prisustva funkcionalnih senzornih poremećaja, anosmije, anhidroze, ortostatske hipotenzije - ali bez ulceracija. Diferencijalno-dijagnostički treba isključiti i lepru, siringomijeliju, druge nasledne senzorne neuropatije, ali i često prisutne faktore rizika za stečene mutilantne akropatije kao što su alkoholizam (promene se javljaju kasnije u životu), lues (*tabes dorsalis*) i dijabetesna polineuropatija i akropatija.

Zaključak: Prikazom obolelih stiče se uvid u jednu retku naslednu neurokutanu genodermatozu, čija diferencijalna dijagnoza obuhvata širok spektar senzornih, motornih i disfunkcijskih poremećaja neurovegetativnog sistema. Za sada, u terapiji na raspolaganju stoje samo higijensko-dijetetske mere (anatomski prilagođena komforna obuća), kao i korektivne hirurške mere u uznapredovalim slučajevima.



Avène

Tolérance extrême

0% konzervansa konačno postaje stvarnost!

Klinički dokazano dejstvo

- *Nepodnošenje kozmetičkih sredstava*
- *Kožne alergije*
- *Iritacije kože (crvenilo, zatezanje, bockanje)*
- *Posle medicinskih zahvata (laser, piling,...)*

- 188 pacijenata
- 149 specijalista (dermatolozi, alergolozi i plastični hirurzi)
- Zadovoljstvo upotrebom programa Tolérance extrême

Poboljšanje stanja kože kod 93% pacijenata (sve indikacije)

Klinički znaci	D0	D7	D21
Iritacija kože	5,52	3,24 -29% p<0,001	1,22 -70% p<0,001
Eritem	5,75	3,18 -29% p<0,001	1,36 -71% p<0,001

Procena kliničkih znakova (skala 0-10)

**0% KONSERVANSA
PARFEMA
EMULGATORA**

D.E.F.I PATENTIRANI SISTEM ZATVARANJA
Proizvod ostaje sterilan i zaštićen od kontaminacije za sve vreme njegove upotrebe.



Krema
9 sastojaka
50 ml

Losion za čišćenje
bez ispiranja
6 sastojaka
50 ml

Samo kvalitetan proizvod pruža sigurnost primene i očekivano delovanje

Južni bulevar 142, 11000 Beograd, +381 (0) 11/3446 409, office@oktal-pharma.rs

OKTAL PHARMA

znak kvaliteta u vašoj apoteci

History of dermatology and venereology in Serbia – part IV/2: Dermatovenereology in Serbia from 1919 – 1945, part 2

Bosiljka M. LALEVIĆ-VASIĆ^{1*} and Marina JOVANOVIĆ²

¹Institute of Dermatology and Venereology, Clinical Center of Serbia, Belgrade, Serbia

²Clinic of Dermatovenereology Diseases, Clinical Center of Vojvodina, Novi Sad, Serbia

*Correspondence: Bosiljka LALEVIĆ-VASIĆ, E-mail: labuba@eunet.rs

UDC 616.5(497.11)(091)”1919/1945”

UDC 616.97(497.11)(091)”1919/1945”

Abstract

After the First World War, Serbia was facing the lack of hospitals and physicians, and organization of the health care system was a real challenge. Both problems were closely associated with dermatovenereology. Between the two world wars, a great contribution to the development of Serbian dermatovenereology as a current discipline was given by Prof. Dr. Đorđe Đorđević, who was the first director of the *Clinic for Skin and Venereal Diseases* in Belgrade (1922 – 1935), and by his closest associate Prof. Dr. Milan Kićevac (1892 – 1940) who was his successor at the position of the director of the Clinic (1935 – 1940). In 1922, Prof. Dr. Đorđe Đorđević was the founder of two institutions significant for Serbian dermatovenereology: *Clinic for Skin and Venereal Diseases*, where he also acted as a director, and the *Department of Dermatovenereology* at the *School of Medicine* in Belgrade, where he was the first teacher of dermatovenereology. In 1927, Prof. Dr. Đorđe Đorđević initiated the foundation of the *Dermatovenereology Section of the Serbian Medical Society*, and he and his associate and successor, Prof. Dr. Milan Kićevac were the main organizers of the *Association of Dermatovenereologists of Yugoslavia*. With this Association, all other regional dermatovenereology sections in the County became parts of the *Pan-Slavic Dermatovenereology Association*. Prof. Dr. Đorđe Đorđević and Prof. Dr. Milan Kićevac also organized the First, Second and the Third Yugoslav Dermatovenereology Congresses (1927, 1928, and 1929), and in 1931, the Second Congress of *Pan-Slavic Dermatovenereology Association*. Their teamwork resulted in legislation concerned with health care, eradication of venereal diseases and prostitution, and finally with setting the foundation for professional and scientific dermatovenereology in Serbia. Prof. Đ. Đorđević investigated current problems of venereal diseases and organized professional expeditions in Serbia and Montenegro studying the expansion of syphilis. However, in his experimental work, Prof. M. Kićevac investigated photo-dermatoses and the IV venereal disease, at the same time pointing to immunological phenomena in streptococcal and staphylococcal infections. Dr. Vojislav Mihailović (1879 – 1949) was a significant figure in Serbian dermatovenereology and acted as the Chief of the *Department of Skin and Venereal Diseases* within the *General Public Hospital* in Belgrade. His scientific papers and books on the history of dermatovenereology and general medicine had a great impact on the Serbian dermatovenereology. His books dealing with the history of dermatovenereology: “*The History of Venereal Diseases till 1912*” and “*Out of the History of Sanitary Health Care in the Rebuilt Serbia from 1804 – 1860*”.

Associate Professor Dr. Sava Bugarski (1897 – 1945), a student of Prof. Dr. Kićevac and later the director of *Clinic for Skin and Venereal Diseases* in Belgrade (1940 – 1945), was engaged in the field of experimental dermatovenereology. Dr. Jovan Nenadović (1875 – 1952), one of the most eminent physicians in Novi Sad, took part in the foundation and work of the *Dermatovenereology Section of the Serbian Medical Society* as well as its honorary life president. In 1919, he founded the *Dermatovenereology Department* within the Novi Sad Hospital, as well as an *Outpatient Dermatovenereology Clinic*, outside the Hospital, although he was the director of both institutions.

In the period between the two world wars, among the most prominent physicians of the Military Sanitary Headquarters who contributed the development of dermatovenereology were the chiefs of the *Dermatovenereology Department of the General Military Hospital* in Belgrade: Major, later on, Brigadier General, Dr. Božidar Janković (1874 – 1936), and the Sanitary Brigadier General, Dr. Milivoje Pantić (1885 – 1959). Dr. B. Janković wrote important professional papers, among which the following are most significant: “*Fight against Venereal Diseases in the Army*” and “*Treatment of Syphilis with Silber-Salvarsan*.”

Distinguished physicians of the military sanitary service, such as Dr. Petar Davidović, made significant contributions to the work of civilian dermatovenereology institutions of that time. In 1921, Dr. Petar Davidović was the director of the newly founded *Venereal Department* of the Niš *Public Hospital*, which was on a high professional level.

The First World War, invasion and post-war epidemics of infectious diseases in Serbia have caused a great loss of lives, both of civilians and of health professionals (1). Apart from the lack of hospitals, lack of physicians was a great problem affecting the health care system and dermatology in Serbia (1).

Physicians

The problem of the lack of physicians after the First World War was partly solved by recruiting physicians from the former Austro-Hungarian Empire, and from Russian immigrants, whereas soon after that *School of Medicine* was founded in Belgrade (2). Most Serbian medical students were educated abroad. For that reason, a substantial budget was approved for their scholarships in 1919 and 1920/1921. Out of this number of medical students, a remarkable number of future dermatologists returned to Serbia (1).

After the First World War, rapid development of dermatovenereology began in Serbia, mostly due to the appearance of two experts with outstanding organizing abilities, high scientific and research potentials and loyalty to their profession. They created legal standards, organized eradication of venereal diseases and prostitution and set foundations for professional and scientific dermatovenereology in Serbia. The first was Prof. Dr. Đorđe Đorđević and the other Prof. Dr. Milan Kićevac (Figure 1). Apart from their high professional and scientific reputation, they were favorite teachers to their students.

Prof. Dr. Đorđe Đorđević (1885 – 1935) graduated from medicine in 1909 in Vienna. During his studies, he worked at the *University Clinic for Skin and Venereal Diseases* with Prof. Finger. After graduation, he was appointed Assistant at the *Dermatovenereology Clinic* in Innsbruck, whereas in 1912 he moved to Zagreb where he had a private practice, but also worked at the *Department of Skin Diseases* of the “*Hospital of Brothers of Mercy*”.

In 1918, after the war, he moved to Belgrade and became the Head of the newly established *Outpatient Service for Skin and Venereal Diseases* (OSSVDs) (3). In 1922, he was the main founder of two institutions significant for Serbian dermatovenereology: *Clinic for Skin and Venereal Diseases* (CSVDs), being its director as well, and the *Department of Dermatovenereology* at the *School of Medicine* in Belgrade, where he was the first teacher of dermatovenereology (4). He was appointed Associate Professor of dermatovenereology in 1923, a Full Professor in 1933, and a Vice Dean in the academic year 1934/35 (5).



Figure 1. Prof. Dr. Milan Kićevac

In 1927, Prof. Dr. Đorđe Đorđević was one of the founders and the first president of the *Dermatovenereology Section* of the *Serbian Medical Society* (DVS SMS) (6).

He was especially interested in solving one of the most serious problems of that time – treatment of syphilis (SY), while his research in gonococcal infections anticipated non-specific urethritis (3, 4). He was involved in socio-medical health care and organized professional expeditions which investigated the expansion of SY, as well as the general health status of people in the East Serbia, Macedonia, Sandžak, and Montenegro. He had published 49 papers, out of which 19 in international journals.

Prof. Dr. Đorđe Đorđević was an honorary or regular member of eight European Dermatovenereology Associations (3). He died unexpectedly, a few days after his 50th birthday, in 1935.

Prof. Dr. Milan Kićevac (1892 – 1940) (Figure 1) started studying medicine in Vienna, but completed his studies in Bern. He was an “Assistant Étranger” in Paris, assistant to Milian, and he attended histological, clinical and microbiological courses of Milian, Civatte and Sabouraud (7).



Figure 2. Constituent Assembly of the Yugoslav Association of Dermatovenereologists in Belgrade in 1927: Dr. Jevrem Žujović is standing in the first row (indicated by an arrow); Prof. Dr. Đorđe Đorđević, is standing in the second row (indicated by an arrow); Prof. Dr. Milan Kićevac is standing in the last row (indicated by an arrow).

Prof. Kićevac was the first, enthusiastic and loyal associate and later the successor of Prof. Đorđević at all his positions, but also a researcher who was the founder of our experimental dermatovenereology. He accepted the Sabouraud's motto: "In order to uncover the truth, it is necessary to attack axioms" At the same time as Frei, he investigated allergic reactions to gland biopsy in the fourth venereal disease (7).

Prof. Dr. Milan Kićevac was famous for his investigations in the field of photo-dermatoses, and his papers were well known and cited. He pointed to the significance of sunlight in the development of *dermatitis pratensis*, using terms "exogenous and endogenous photo-catalysts and photo-sensibilizators". He was among the first to write about "streptococidal and staphylococidal agents", and ahead of his time, he pointed to the importance of immunologic phenomena in bacterial infections (7, 8). He had published 84 papers, mostly in French journals, which were often cited; after his early death, he left a number of unpublished papers and a textbook in dermatovenereology. Unfortunately, they had been lost in the whirlwind of war. He was a corresponding or full member of 8 European Dermatovenereology Associations. He died in 1940, at the age of 49 (7).

During their work, Prof. Dr. Đorđe Đorđević and Prof. Dr. Milan Kićevac had a leading role in the organization of dermatovenereology service. Their work was closely related so that we will write about them and their work at the same time. Owing to their work dermatovenereology in Serbia had developed into a modern discipline with international reputation. They organized activities for eradication of venereal diseases and prostitution. Prof. Dr. Đorđe Đorđević had initiated creation of the *Belgrade Dermatovenereology Moulage Collection*, but they worked on it together (4). After the foundation of the *Dermatovenereology Section (DVS)* of the *Serbian Medical Society (SMS)*, in 1927 they were the main organizers of the *Association of Dermatovenereologists of Yugoslavia (ADVY)* (Figure 2) whose president was Dr. Jevrem Žujović (9). The Association included all dermatovenereology sections of the Kingdom of the Serbs, Croats and Slovenes (SCS) of that time, and owing to that, they became members of the *Pan-Slavic Association of Dermatovenereologists (PSADVs)* founded in Prague at that time (10). They and their associates organized the First (1927), Second (1928) and Third (1929) Yugoslav Dermatovenereology Congresses (11, 12, 13). After the First Congress

of the PSADVs, held in Warsaw in 1929, Prof. Dr. Đorđe Đorđević became its president, while Dr. Milan Kićevac, Assistant at that time, was appointed a Secretary of the Association. In 1931, they organized the Second Congress of the PSADVs in Belgrade, which was attended, apart from the members of Slavic national associations, by outstanding dermatologists from France, Romania and Greece. The Congress was very successful with international participation (13).

Dr. Vojislav Mihailović (1879 – 1949) (Figure 3) was the Head of the *Department of Skin Diseases and Syphilis* (DSDS) within the *General Public Hospital* (GPH) in Belgrade (1927–1941). He graduated from medicine in 1904 in Graz (14). Among his first publications was a monograph on venereal diseases titled: “*Venereal Diseases: Etiology, Course and Eradication*”. Its second extended edition was published in 1924 (15). Apart from numerous professional papers (15), he was interested in the history of medicine and wrote two books of great significance. The first one: “*The History of Venereal Diseases in Serbia up to 1912*”, was the first and only book on the history of venereal diseases in our country (16). The second book: “*Out of the History of Sanitary Health Care in the Rebuilt Serbia from 1804 – 1860*”, presented the development of medicine in our country in the first half of the 19th century (17). Both



Figure 3. Dr. Vojislav Mihajlović



Figure 4. Associate Professor, Dr. Sava Bugarski

books were written based on original archive documents, attached in its entirety, translated into the current Serbian language and thus they are indispensable in the study of this field of medicine. Still a student, he translated Eugene Brieux play “*Damaged Goods*” about the painful life of people with syphilis (16).

Associate Professor, Dr. Sava Bugarski (1897 – 1945) (Figure 4) started studying medicine in Zagreb, but continued and graduated in Graz in 1924. He specialized in dermatovenereology at the CSVDs in Belgrade (18). In 1926, he was appointed an Assistant, and in 1939 as an Associate Professor at the *Department of Dermatovenereology* at the *School of Medicine* in Belgrade (18). He was the director of the CSVDs with occasional interruptions during the occupation from 1940 to 1945. Being a student of Prof. Kićevac, he was interested in experimental dermatovenereology and investigated effects of sunlight on certain dermatoses. He studied effects of anti-syphilis therapy on the *T. pallidum* virulence on experimental animals. Results of his studies were published in national and international professional journals. He also died unexpectedly, in 1945, before the age of 50 (18, 19).

Dr. Jovan Nenadović (1875 – 1952) (Figure 5) was the first Serbian dermatovenereologist



Figure 5. Dr. Jovan Nenadović

in Vojvodina. In 1900, he graduated from the *Medical University of Graz*, and specialized in dermatovenereology in Vienna, working with eminent scientists such as Kaposi and Finger. After the First World War, in 1918, when he returned to Novi Sad, there was neither Hospital nor Department for the treatment of patients with skin and venereal diseases. Then he founded the *Department of Skin and Venereal Diseases* of the GPH in Novi Sad with 100 beds, and outside the hospital an independent *Public Outpatient Service for Skin and Venereal Diseases*, for free of charge treatment of patients with venereal diseases. Dr J. Nenadović was the director of both institutions (20, 21). Later, he became the director of the GPH in Novi Sad and the first president of the *Danube Banovina Medical Association*. He had a private medical office with all the necessary state-of-the-art equipment (18).

He was one of the initiators and founders of the DVS of the SMS and its honorary life president. He was engaged in humanitarian work and initiated all significant humanitarian, social and cultural events in Novi Sad. He was also one of the greatest humanists and among the most eminent physicians of that time (21).

Dr. Božidar S. Janković (1874–1936), a Sanitary Brigadier General, was awarded a great number of war decorations, among which the following two are most important: Gold medal for best service and Gold medal for bravery; he graduated from medicine in St. Petersburg, and in the period from 1908 – 1910, he was an intern at the GPH in Belgrade (22). As a Reserve Major, after the end of the First World War, he became a director of the *Dermatovenereology Department (DVD)* of the *General Military Hospital (GMH)* in Belgrade (23). In 1920, he joined the army of the Kingdom of SCS (22).

He specifically dealt with one of the greatest health problems of that time – venereal diseases. Among his published works, two are of great significance: a book: “*The Fight against Venereal Diseases in the Army*” (24) and “*On the Treatment of Syphilis with Silber-Salvarsan*” (25). Later, as a Colonel, he was the Medical Officer of the *Third Army Area*, and in 1934 he was promoted to the rank of a Sanitary Brigadier General (5, 25).

Dr. Milivoje Pantić (1885 –1959) (Figure 6), a Sanitary Brigadier General, graduated from the *School of Medicine* in Vienna in 1900. After the First World War, as a Major, he became the director of the DVD of the *Permanent Military Hospital* of the *First*



Figure 6. Dr. Milivoje Pantić

Military Area, and till the beginning of the Second World War he was the director of the DVD of the GMH in Belgrade (23, 26).

Dr. Petar Davidović (1884 - ?, after 1933), was born in Srem, Vojvodina. He attended the Karlovačka High School and graduated from *School of Medicine* in Prague (27). In 1921, after being demobilized, he became the Head of the *Department for Skin and Venereal Diseases* of the *City Hospital* in Niš, up to then directed by Dr. Eva Haljecka, general practitioner. The work of this Department was at a high professional level, so medical students had been able to perform their practice in that institution, whereas their knowledge and skills were estimated by the director of the Department (28).

To be continued.

Abbreviations

- ADVY - Association of Dermatovenereologists of Yugoslavia
 CSVDS - Clinic for Skin and Venereal Diseases
 DSDS - Department of Skin Diseases and Syphilis
 DVD - Dermatovenereology Department
 DVS - Dermatovenereology Section
 GMH - General Military Hospital
 GPH - General Public Hospital
 OSSVDs - Outpatient Service for Skin and Venereal Diseases
 PSADVs - Pan-Slavic Association of Dermatovenereologists
 SCS - Serbs, Croats and Slovenes
 SMS - Serbian Medical Society
 SY - Syphilis

References

- Milovanović V. Editor: Medicinski godišnjak Kraljevine Jugoslavije (Annual Medical Report of the Kingdom of Yugoslavia). Beograd: Jugoreklam K. D; 1933.
- Ignjatović M. Srpska ratna vojna doktrina u ratovima 1912-1918 (Serbian war surgical doctrine 1912 - 1918). *Vojnosanit Pregl* 2008;65(Suppl):49-58.
- Kičevac M. In Memoriam. Prof. Đ. Đorđević. Naučni i stručni rad Prof. Đorđa Đorđevića (Scientific and professional work of Prof. Đ. Đorđević). *Med Pregl* 1936;11(4):61-3.
- Kičevac M. Klinika za kožne i venerične bolesti (Clinic for Skin and Venereal Diseases). U: Medicinski fakultet Univerziteta u Beogradu 1920-1935 (In: School of Medicine of the Belgrade University from 1920 - 1935). Beograd: Medicinski fakultet; 1935. p. 125-31.
- Čolović R. Djordjević Djordje. U: Popov Č. Editor. Srpski biografski rečnik 3 D-Z (Serbian biographical dictionary 3 D - Z.). Novi Sad: Matica Srpska - Miro Vuksanović; 2007. p. 540-1.
- Zapisnik II redovne godišnje skupštine Dermatovenerološke sekcije SLD (Minutes of the Second regular assembly of the Dermatovenereology Section of the SMS). *Srp Arh Celok Lek* 1928;30(3):232-3.
- Bugarski S. In Memoriam. Prof. dr Milan Kičevac. *Med Pregl* 1940;15(4):73-5.
- Kičevac M. Fotodermatoze biljnog porekla (Photodermatoses of plant origin). *Med Pregl* 1939;14 (4):61-6.
- Osnivačka skupština Jugoslovenskog derma-tološkog društva (Founding meeting of the Association of Dermatovenereologists of Yugoslavia). *Srp Arh Celok Lek* 1928;30(11):931-42.
- Skup Jugoslovenskih dermatologa i venerologa i osnivanje Jugoslovenskog dermatovenerološkog društva (Meeting of Yugoslav dermatologists and venereologists and foundation of the Association of Dermatovenereologists of Yugoslavia). *Srp Arh Celok Lek* 1928;30(2):147-9.
- M. K. II skup Jugoslovenskih dermatologa i venerologa (The second meeting of Yugoslav dermatologists and venereologists). *Med Pregl* 1929;4(1):38.
- Kičevac M. III Skup Jugoslovenskih dermatologa i venerologa (The third meeting of Yugoslav dermatologists and venereologists). *Med Pregl* 1930;5(1):31-4.
- Ilić S. II Kongres Sveslovenskog dermatološkog Saveza (The second congress of the Pan-Slavic Dermatology Association). *Med Pregl* 1931;6(8):229-34.
- Stanojević V. Likovi i dela istaknutih lekara od osnivanja Srpskog lekarskog društva do danas (Characters and works of prominent physicians since the foundation of SMS to date). U: Đurić D, i sar. Srpsko lekarsko društvo: Spomenica 1872-1972 (Serbian Medical Society: Memorial Book 1872-1972). Beograd: Srpsko lekarsko društvo; 1972:159-254.
- Mihajlović V. Polne bolesti: njihov postanak, tok i suzbijanje (Venereal Diseases: Etiology, Course and Eradication). 2nd ed. Beograd: Vuk Karadžić; 1924.
- Mihailović V. Istorija polnih bolesti u Srbiji do 1912. godine (The history of venereal diseases in Serbia till 1912). Beograd: Biblioteka centralnog higijenskog zavoda; 1931.
- Mihailović V. Iz istorije saniteta u obnovljenoj Srbiji od 1804 - 1860 (Out of the history of health care in the rebuilt Serbia from 1804 - 1860). Beograd: Srpska Akademija nauka CLXXX; Odeljenje medicinskih nauka 4; 1951.
- Milanović M. Biografski leksikon: poznati srpski lekari (Biographical lexicon: Eminent Serbian physicians). Beograd: Milanović Milena; 2005.
- Arhivski dokumenat (Archive document). *Arhiv Srbije*, F I; 1856/45.
- V. J. Pedesetogodišnjica lekarskog i kulturnog rada Dr Jovana Nenadovića (50th Anniversary of medical and cultural work of Dr. Jovan Nenadović). *Med Pregl* 1951;4(9-10):1-3.
- V. K. In memoriam. Dr Jovan Nenadović. *Med Pregl* 1953;6 (3):201-2.
- Nedok AS. Janković Božidar. U: Popov Č, urednik. Srpski biografski rečnik 3 D-Z (Serbian biographical dictionary 3 D - Z). Novi Sad: Matica Srpska; 2007. p. 269.
- Dinić MŽ, Kandolf-Sekulović L, Zečević RD. Sto godina dermatovenerologije u Vojski Srbije (A hundred years of dermatovenereology in the Serbian Army). *Vojnosanit Pregl* 2010;67(1):73-6.

24. Janković BS. Borba s veneričnim bolestima u vojsci (Management of venereal diseases in the army). Beograd: Ministarstvo vojno i mornarice; 1923.
25. Janković B. O lečenju sifilisa silbersalvarsanom (On the therapy of syphilis by silber-salvaran). *Srp Arh Celok Lek* 1921;21(9):487-502.
26. Bjelajac MS. Generali i Admirali Kraljevine Jugoslavije 1918-1941. (Generals and Admirals of the Kingdom of Yugoslavia from 1918 – 1941). Beograd: Institut za noviju istoriju Srbije, Dobra d.o.o; 2004.
27. Nedok AS. Davidović Petar. U: Popov Č, urednik. Srpski biografski rečnik 3 D-Z (Serbian biographical dictionary 3D-Z). Novi Sad: Matica Srpska; 2007. p. 51.
28. Krstić S. 80 godina službe i 20 godina Klinike za kožne i polne bolesti u Nišu (80th Anniversary of the Service and 20th Anniversary of the Clinic for Skin and Venereal Diseases in Niš). Niš: Univerzitetski klinički centar, Klinike za kožne i polne bolesti; 1991.

A report on the 7th Spring Symposium of the European Academy of Dermatology and Venereology

The 7th Spring Symposium of the European Academy of Dermatology and Venereology (EADV) was held at the "Hotel Croatia" Conference Center in Cavtat, from 13-16 May, 2010. Jasna Lipozenčić, the symposium chairperson, informed the participants that the logo of the 7th Spring Symposium of the EADV was: "Harmony in Dermatology and Venereology", inspired by the need of coexistence of dermatology and venereology, which was the tradition in Croatia, and *conditio sine qua non* in the European medicine. There were active participations from 63 countries, mostly from Romania, Croatia, the United Kingdom, Spain, Portugal, Korea, Serbia, Iran, Poland, Germany, but also from the United Emirates, USA, Mexico, Morocco and Japan.

This Symposium offered a rich scientific program, emphasizing the profound and complex influence of skin health on all aspects of human life. Prevention and management of skin and venereal diseases provides an opportunity for physicians, scientists and patients to meet and share the perspectives on dermatology and venereology.

The attendants of the 7th Spring Symposium of the EADV in Cavtat could participate in the following symposia: Updates on Melanoma Management, Skin Conditions and Endocrinology, Psoriasis, Skin Diseases in the Mediterranean, Bullous Diseases Revisited, Acne and Rosacea, Skin Clues of Systemic and Connective Tissue Diseases, Photodermatology, Atopic Dermatitis, Non-Surgical Treatment of Non-Melanoma Skin Cancer, HIV Infection in Dermatology and Dermatofungoses. Apart from these, eleven Workshops were held.

Two professors from Serbia were chairpersons at the 7th Symposium of the EADV: Ljiljana Medenica (Free Communications) (Figure 1) and Miloš Nikolić (Skin Clues of Systemic and Connective Tissue Diseases) (Figure 2).



Figure 1. Andrea Peserico (Italy) and Ljiljana Medenica (Serbia) as chairpersons in Free Communications in Cavtat



Figure 2. Jana Hercogova (Czech Republic) and Miloš Nikolić (Serbia) as chairpersons at the Symposium: Skin Clues of Systemic and Connective Tissue Diseases

The following lectures were presented from Serbia: “Epidermolysis Bullosa Acquisita: A Rare Autoimmune Bullous Disorder” by M. Milinković, D. Milčić and S. Vesić; “Coexistence of Pemphigus Juvenilus and Psoriasis Vulgaris in a Patient with Down’s Syndrome” by S. Vesić, D. Milčić and M. Milinković; “Evaluation of Long Pulsed Nd: YAG Laser-Assisted Facial Hair Removal in Skin Type Fitzpatrick I-III” by J. Kozarev. Apart from lectures, there were 25 posters from Serbia.

The lecture “What’s New in Clinical Dermatology”, given by Rudolph Happle from Germany, included the following topics: A new field of clinical dermatology - Adverse cutaneous effects of biologics; A presently fashionable form of quackery - Mesotherapy and superimposed segmental manifestation of polygenic skin disorders.

Erwin Tschachler from Austria gave a lecture “What’s New in Venereology”, dealing with

trends for syphilis therapy in some countries. The trend for newly reported cases of syphilis in Western Europe seems stable, although at a higher level than in the mid 1990s. Azithromycin shows high efficiency orally, at a dose of 2.0 g in the treatment of early syphilis. He also opened the topic if therapeutical eradication of HIV-1 in infected patients is possible.

Peter Steijlen from The Netherlands gave a lecture: “What’s New in Pediatric Dermatology” and discussed about propranolol for severe hemangiomas of infancy, and a new trend: Pathway-based and translational medicine.

Zoran GOLUŠIN

Clinic of Dermatovenereology Diseases
Clinical Center of Vojvodina, Novi Sad, Serbia

*Correspondence: Zoran GOLUŠIN

E-mail: zgolusin@eunet.rs

FORTHCOMING EVENTS

Dermatology and Venereology Events 2010-2011

DATE	MEETINGS, CONGRESSES, SYMPOSIA	ABSTRACT SUBMISSION DEADLINE	MORE INFORMATION AT
4-7 September, 2010	16 th Meeting of the European Society for Pigment Cell Research, Hinxton Cambridge, UK	31 May, 2010	www.registration.hinxton.wellcome.ac.uk
9-11 September, 2010	40 th Annual ESDR Meeting (European Society for Dermatological Research), Helsinki, Finland	14 May, 2010	www.esdr2010.org
15-18 September, 2010	10 th Congress of the European Society of Contact Dermatitis, Strasbourg, France	March, 2010	www.escd-gerda2010.com
23-25 September, 2010	25 th IUSTI (International Union Against Sexually Transmitted Infections) – Europe Conference, Tbilisi, Georgia	31 May, 2010	www.iusti2010-tbilisi.ge
23-26 September, 2010	31 st Annual Meeting of the ISDS (International Society for Dermatologic Surgery)	No abstract submission	www.isdsworld.com
6-10 October, 2010	19 th EADV Congress Gothenburg, Sweden	3 March, 2010	www.eadvgothenburg2010.org
15-17 October, 2010	6 th EMAA (European Masters in Aesthetic and Anti-Aging Medicine), Paris, France	30 May, 2010	www.euromedicom.com
21-23 October, 2010	XXXI Symposium of The International Society of Dermatopathology, Barcelona, Spain	25 August, 2010	www.isdpbarcelona2010.net
29 October – 01 November, 2010	X th ADI (Ionic Dermatological Association) International Congress, Floriana, Malta	27 August, 2010	www.malta2010.net
4-7 November, 2010	1 st World Congress on Controversies in Plastic Surgery and Dermatology, Barcelona, Spain	4 August, 2010	www.comtecmed.com/coplasdy/2010
12-13 November, 2010	XV Belgrade Dermatological Days, Department of Dermatology, Military Medical Academy, Belgrade, Serbia	1 September, 2010	www.udvs.org
9-11 December, 2010	COSMODERM XIV – The International Aesthetic Dermatology Congress of ESCAD, Dresden, Germany	15 June, 2010	www.cosmoderm2010.de
14-17 April, 2011	8 th EADV Spring Symposium Carlsbad, Czech Republic	In construction	www.eadv.org
24-29 May, 2011	22 nd World Congress of Dermatology, Seoul, Korea	31 October, 2010	www.wcd2011.org
16-19 June, 2011	1 st Congress of the Society of Dermatovenereologists of Montenegro, Budva-Bečići, Montenegro	In construction	www.udvcg.me e-mail: dr.stilet@t-com.me
7-10 September, 2011	41 st Annual ESDR Meeting (European Society for Dermatological Research), Barcelona, Spain	In construction	www.esdr.org
15-17 September, 2011	2 nd 5-Continent-Congress: Lasers and Aesthetic Medicine, Canes, France	31 March, 2011	www.5-cc.com

Prepared by: Dr. Tatjana Roš, Clinic of Dermatovenereology Diseases, Clinical Center of Vojvodina, Novi Sad, Serbia

AUTHOR GUIDELINES

Serbian Journal of Dermatology and Venereology is a journal of the *Serbian Association of Dermatologists and Venereologists*. The journal is published in English, but abstracts will also be published in Serbian language. The journal is published quarterly, and intended to provide rapid publication of papers in the field of dermatology and venereology. Manuscripts are welcome from all countries in the following categories: editorials, original studies, review articles, professional articles, case reports, and history of medicine.

Categories of Manuscripts

1. **Editorials** (limited to 5 pages) generally provide commentary and analyses concerning topics of current interest in the field of dermatology and venereology. Editorials are commonly written by one author, by invitation.
2. **Original studies** (limited to 12 pages) should contain innovative research, supported by randomized trials, diagnostic tests, outcome studies, cost-effectiveness analysis and surveys with high response rate.
3. **Review articles** (limited to 10 pages) should provide systemic critical assessment of literature and other data sources.
4. **Professional articles** (limited to 8 pages) should provide a link between the theory and practice, as well as detailed discussion or medical research and practice.
5. **Case reports** (limited to 6 pages) should be new, interesting and rare cases with clinical significance.
6. **History of medicine** (limited to 10 pages) articles should be concerned with all aspects of health, illness and medical treatment in the past.

The journal also publishes book reviews, congress reports, as well as reports on local and international activities, editorial board announcements, letters to the editor, novelties in medicine, questions and answers, and "In Memoriam". All submitted manuscripts will undergo review by the editor-in-chief, blind review by members of the manuscript review panel or members of the Editorial Board. Manuscripts submitted to this journal must not be under simultaneous consideration by any other publisher. Any materials submitted will NOT BE RETURNED to the author/s.

All manuscripts should be submitted to the **Editor in Chief: Prof. Dr. Marina Jovanović**, Clinic of Dermatovenereologic Diseases, Clinical Center of Vojvodina, Hajduk Veljkova 1-3, Novi Sad, Serbia, by mail to: serbjdermatol@nadlanu.com.

Manuscripts for submission must be prepared according to the guidelines adopted by the International Committee of Medical Journal Editors (www.icmje.org). Please consult the latest version of the Uniform Requirements for Manuscripts Submitted to Biomedical Journals.

1. Manuscript Preparation Guidelines

The manuscript should be written in English, typed in double spacing throughout on A4 paper, on one side only; Use Times New Roman, font size 12, with 30 lines and 60 characters per line. Articles must be written clearly, concisely and in correct English. Accepted manuscripts in need of editing will be returned after editing to the corresponding author for approval. When preparing their manuscripts, authors should follow the instructions given in the *Categories of Manuscript*: the number of pages is limited (including tables, figures, graphs, pictures and so on to 4 (four)), and all the pages must be numbered at the bottom center of the page.

For manuscript preparation, please follow these instructions:

1.1. Title page

The title page should include the following information:

- The title of the article, which should be informative, without abbreviations and as short as possible;
- A running title (limited to 30 characters);
- Authors' names and institutional affiliations;
- The name, mailing address, telephone and fax numbers, and email of the corresponding author responsible for correspondence about the manuscript. Furthermore, authors may use a footnote for acknowledgements, information and so on.

1.2. Abstracts

A structured abstract in English (limited to 150 words) should follow the title page. The abstract should

provide the context or background for the study, as well as the purpose, basic procedures, main findings and principal conclusions. Authors should avoid using abbreviations.

- An abstract in Serbian language, (limited to 150 words) should follow the second page. It should contain a briefing on the purpose of the study, methods, results and conclusions, and should not contain abbreviations.

1.3. A list of abbreviations

Use only standard abbreviations, because use of non-standard abbreviations can be confusing to readers. Avoid abbreviations in the title, abstract and in the conclusion. A list of abbreviations and full terms for which they stand for should be provided on a separate page. All measurements of length, height, weight, and volume should be reported in the metric units of the International System of Units – SI, available at <http://www.bipm.fr/en/si/>.

1.4. Cover Letter

Manuscripts must be accompanied by a cover letter, which should include a date of submission, statement that the manuscript has been read and approved by all the authors and that the authorship requirements have been met. It should also include the name, address, and telephone number of the corresponding author, who is responsible for communicating with other authors about revisions and final approval of the proofs. The original copy of the cover letter, signed by all authors, should be enclosed with the manuscript.

2. Tables and illustrations

Tables should capture information concisely and precisely. Including data in tables, rather than in the text, reduces the length of the article itself.

- Submit tables in separate files, not included in the manuscript. Tables are to be double spaced and numbered sequentially, with Arabic numbers (Table 1, Table 2, etc.), in order of text citation. Each column, including the first, must have a heading. Provide a brief title for each table. Put all explanatory matter in footnotes, including any nonstandard abbreviations used in the table.

*- **Figures** should be submitted in a separate file, not included in the manuscript document. Cite figures consecutively, as they appear in the text, with Arabic numbers (Fig. 1, Fig. 2, Fig. 3, etc.). Each figure must be assigned a title, as well as a legend. Legends should appear on a separate page, not with each figure. The **Legend Page** is to be numbered in sequence after the last page of the references list. Figures should be professionally drawn, as sharp black-and-white or color photographs. If photographs of persons are used, either the subjects must not be identifiable, or their pictures must be accompanied by written permission to use them.*

3. References

References in the text, tables and legends should be identified by Arabic numerals in parentheses. Number references consecutively in the order in which they are first mentioned in the text. The *Vancouver System* of referencing should be used. List each author's last name and initials; full first names are not included. List all authors, but if the number exceeds six, give the first six followed by „et al.” National journals, which are not indexed in *Index Medicus*, should be abbreviated according to the style in the *List of Abbreviated Titles of Yugoslav Serial Publications* available on <http://vbsw.vbs.rs>. For further information please visit www.ICMJE.org.

4. Additional information

Accepted manuscripts are edited and returned to the corresponding author for approval. Then a final version of the manuscript will be requested in a defined period of time. Authors will be notified of acceptance or rejection by email, within approximately 4 weeks after submission.

*- Open access: Every article published in the **Serbian Journal of Dermatology and Venereology** will immediately be accessible on www.udvs.org to everyone at no charge.*

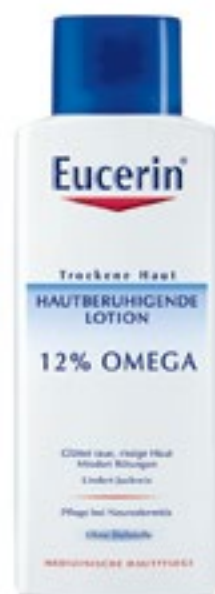For further information please contact the Editorial Office (Tel: +381 21/484 35 62) or visit our web site: www.udvs.org.

CIP – Каталогизacija y publikaciji
Народна библиотека Србије, Београд

616.5(497.11)

SERBIAN Journal of Dermatology and
Venerology / editor-in-chief Marina
Jovanović. - Vol. 1, no. 1 (january 2009)-
. - Belgrade (Pasterova 2) : The Serbian
Association of Dermatovenereologists, 2009-
(Beograd : Zlatni presek). - 30 cm

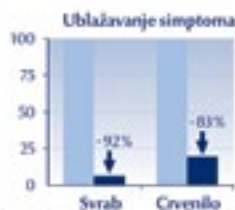Tromesečno
ISSN 1821-0902 = Serbian Journal of
Dermatology and Venerology
COBISS.SR-ID 156525836



Konačno olakšanje za suhu i kožu sa crvenilom

Novi Eucerin® Losion za telo sa 12% omega masnim kiselinama pruža olakšanje za suhu kožu sa crvenilom i čestim svrabom. Prirodne omega masne kiseline, dobijene iz ulja noćurka i semena grožđa, jačaju oštećeni odbrambeni mehanizam kože. Visoko efikasan likokalkon biljnog porekla ublažava crvenilo i dugotrajno umiruje kožu. Ova jedinstvena kombinacija sastojaka dovoljno je blaga za upotrebu i kod obolele kože i kože beba.

Klinička ispitivanja* dokazuju efikasnost i dobru podnošljivost na koži. Losion je pogodan kao dodatna nega kod atopijskog ekcema. www.Eucerin.com



Eucerin®

NAUKA U SLUŽBI ZDRAVE KOŽE
Samo u apotekama



Cover figure: Christ Healing Ten Lepers, Christ's Miracles, XIVth century, The monastery Visoki Dečani, Serbia, Kosovo

**Published by the
Serbian Association of Dermatovenereologists**