

# Serbian Journal of Dermatology and Venereology

ISSN 1821-0902

UDC 616.5(497.11)

Volume 3, Number 1, March 2011

**EDITORIAL**  
**COMPETENCY GAPS  
IN DERMATOLOGY**

**REVIEW ARTICLE**  
**GENITAL HERPES**

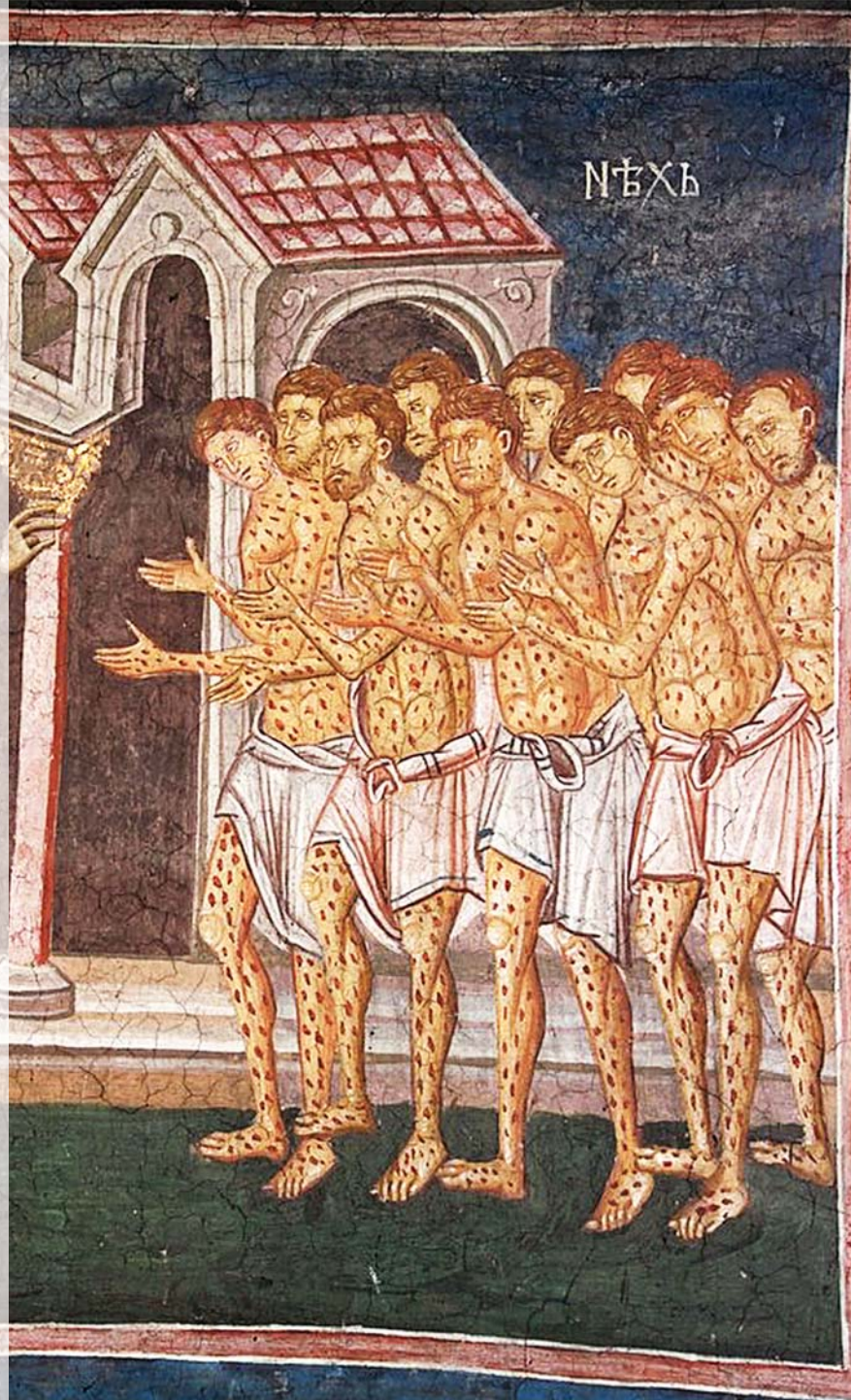
**CASE REPORTS**  
**EXTENSIVE LICHENOID  
CUTANEOUS SARCOIDOSIS**

**BULLOUS LICHEN PLANUS  
IN CHILDHOOD**

**HISTORY OF MEDICINE**  
**DERMATOVENEREOLOGY IN THE  
SERBIAN ARMY**

**REPORTS**

**FORTHCOMING EVENTS**



Published by the  
Serbian Association of Dermatovenereologists







## SERBIAN ASSOCIATION OF DERMATOVENEREOLOGISTS

President of the Association  
**LJILJANA MEDENICA, Belgrade**

## SERBIAN JOURNAL OF DERMATOLOGY AND VENEREOLOGY

Editor-in-Chief  
**MARINA JOVANOVIĆ, Novi Sad**

Assistants to the Editor-in-Chief  
**ZORAN GOLUŠIN, Novi Sad**  
**DRAGAN JOVANOVIĆ, Niš**  
**LIDIJA KANDOLF-SEKULOVIĆ, Belgrade**  
**MILAN MATIĆ, Novi Sad**

### EDITORIAL BOARD

President  
**MILOŠ NIKOLIĆ, Belgrade**

Secretary  
**DANIJELA DOBROSAVLJEVIĆ, Belgrade**

### Members

<b>IVANA BINIĆ, Niš, Serbia</b>	<b>LJILJANA MEDENICA, Belgrade, Serbia</b>
<b>VERICA ĐURAN, Novi Sad, Serbia</b>	<b>MILOŠ PAVLOVIĆ, Ljubljana, Slovenia</b>
<b>ANNA GORKIEWICZ-PETKOW, Warsaw, Poland</b>	<b>ROBERT A. SCHWARTZ, New Jersey, USA</b>
<b>CAMILA K. JANNIGER, New Jersey, USA</b>	<b>MILENKO STANOJEVIĆ, Niš, Serbia</b>
<b>ĐORĐIJE KARADAGLIĆ, Belgrade, Serbia</b>	<b>JACEK C. SZEPIETOWSKI, Wroclaw, Poland</b>
<b>ANDREAS KATSAMBAS, Athens, Greece</b>	<b>GEORGE SORIN TIPLICA, Bucharest, Romania</b>
<b>ALEKSANDAR KRUNIĆ, Chicago, USA</b>	<b>NIKOLAI TSANKOV, Sofia, Bulgaria</b>
<b>BOSILJKA LALEVIĆ-VASIĆ, Belgrade, Serbia</b>	<b>NADA VUČKOVIĆ, Novi Sad, Serbia</b>
<b>MARKO LENS, London, United Kingdom</b>	<b>RADOŠ ZEČEVIĆ, Belgrade, Serbia</b>
<b>JOHN McGRATH, London, United Kingdom</b>	

Technical editor: Vladimir Bugarski  
Technical Assistant: Vesna Šaranović  
English Proofreading: Marija Vučenović  
Serbian Proofreading: Dragica Pantić  
UDC Selection: Zorica Đokić  
Reference Checking: Branislava Čikić

The Journal is published four times a year with the circulation of 360. Manuscripts are to be submitted to the  
Editor-in-Chief: Prof. Dr. Marina Jovanović, Klinički centar Vojvodine,  
Klinika za kožne i venerične bolesti, 21000 Novi Sad, Hajduk Veljkova 1-7  
E-mail: serbjdermatol@open.telekom.rs, Tel: +381 21 484 3562; +381 21 451 781.

Copyright © 2009 by the Serbian Association of Dermatovenereologists

Published on behalf of The Serbian Association of Dermatovenereologists by Zlatni presek, Beograd

# CONTENTS

Serbian Journal of Dermatology and Venereology 2011; 3 (1):1-48.

## EDITORIAL

- 5 **WIDENING COMPETENCY GAPS IN THE STATE OF THE ART DERMATOLOGY**  
*Miloš D. PAVLOVIĆ*

## REVIEW ARTICLE

- 7 **GENITAL HERPES**  
*Marina JOVANOVIĆ*

## CASE REPORTS

- 23 **EXTENSIVE LICHENOID TYPE OF CUTANEOUS SARCOIDOSIS – A CASE REPORT**  
*Lidija KANDOLF-SEKULOVIĆ, Miroslav DINIĆ, Tatjana RADEVIĆ,  
Radoš D. ZEČEVIĆ, Lidija ZOLOTAREVSKI, Vukojica KARLIČIĆ*
- 28 **BULLOUS LICHEN PLANUS IN CHILDHOOD – A CASE REPORT**  
*Biljana ARSOV, Svetlana POPADIĆ, Miloš NIKOLIĆ*

## HISTORY OF MEDICINE

- 33 **ONE HUNDRED YEARS OF DERMATOVENEREOLOGY IN THE SERBIAN ARMY**  
*Miroslav Ž. DINIĆ, Lidija KANDOLF-SEKULOVIĆ, Radoš D. ZEČEVIĆ*

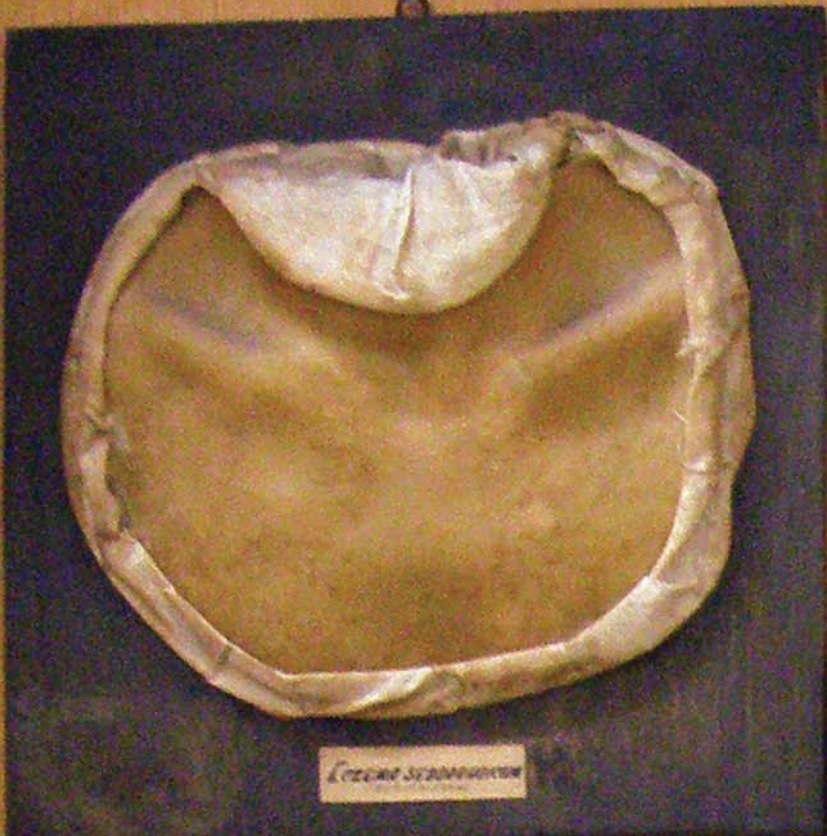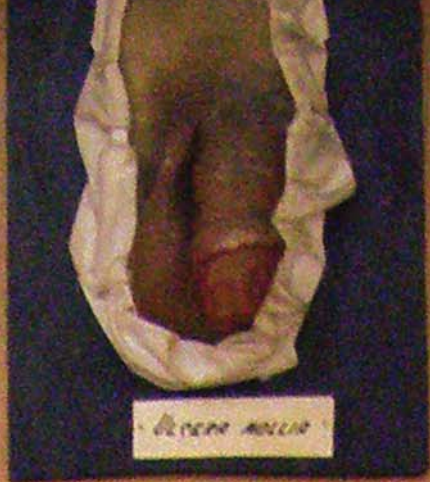## REPORTS

- 39 **ACTIVITIES OF THE DERMATOVENEREOLOGY SECTION OF THE  
SERBIAN MEDICAL SOCIETY IN 2010**  
*Sonja VESIĆ*
- 41 **2010 ANNUAL REPORT ON THE WORK OF THE DERMATOVENEREOLOGY  
SECTION OF THE SOCIETY OF PHYSICIANS OF VOJVODINA OF  
THE SERBIAN MEDICAL SOCIETY**  
*Olga VLAOV-ŽARKOV*

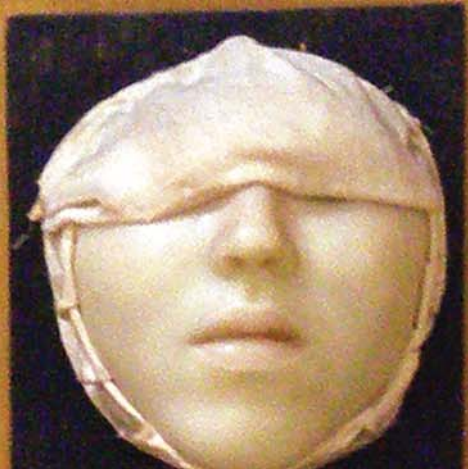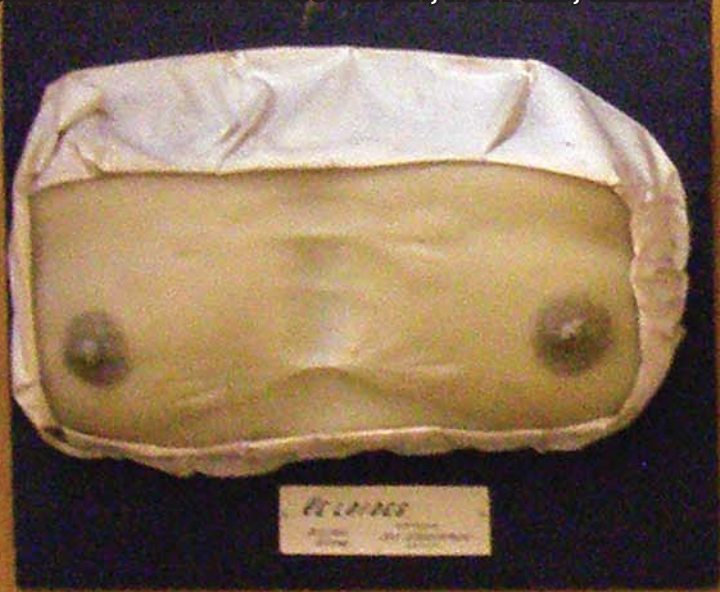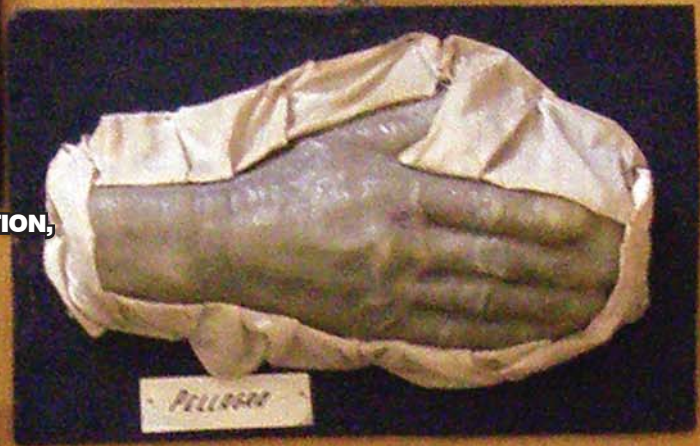## FORTHCOMING EVENTS

- 43 **DERMATOLOGY AND VENEREOLOGY EVENTS 2011**





THE NOVI SAD DERMATOVENEREOLIC, MOULAGE COLLECTION,  
CLINIC OF DERMATOVENEREOLGY,  
CLINICAL CENTER OF VOJVODINA, NOVI SAD, SERBIA





## Widening competency gaps in the state of the art dermatology

Miloš D. PAVLOVIĆ\*

Dermatology Centre Parmova, Ljubljana, Slovenia

\*Correspondence: Miloš D. PAVLOVIĆ, E mail: milos.pavlovic@dcp.si

UDC 616.5-051:614.25

Due to the Publisher's error, the editorial entitled "WIDENING COMPETENCY GAPS IN THE STATE OF THE ART DERMATOLOGY", published in Serbian Journal of Dermatology and Venereology, Vol 2; No 4, 2010, was attributed to Ivan D. Pavlović, instead to Miloš D. Pavlović. That is why the above-mentioned editorial by Miloš Pavlović will be published again in this issue of SJDV.

Dermatology is really unique among medical and surgical specialties today; it encompasses a huge number of disorders originating either in the skin and subcutaneous tissue, or affecting the skin of other organs. Dermatologists are probably dealing with more diagnoses and disease entities than any other specialists in modern medical practice. Apart from deepening their knowledge about mechanisms of many skin diseases, including their genetic background, and of sophisticated novel medical treatment modalities, new exciting approaches to the management of many skin disorders found their way into the clinical practice of dermatology over the last decades. Some like to dub it procedural dermatology, others simply dermatologic surgery.

As a natural extension of these developments, a further step in the growth of dermatology has been marked by birth of cosmetic dermatology and dermatosurgery. The probable reasons for such changes in dermatology are manifold, but irrespective of the motives, now they must be respected. Though many colleagues, even fellow specialists, feel reluctant to think that a dermatologist should be using a scalpel or a liposuction cannula - it comes with the territory and the bell cannot be unrung. It is indisputable that dermatologists are best suited to treat skin disorders: inflammatory, cancerous or esthetic. Unfortunately, specialty training programs in Serbia and some neighboring countries are obviously short of courses improving knowledge and skills. Ever more competitive environment in the field of medicine forces us to move on.

In a way this is an appeal to all those who are in a position to have an impact on the creation of the specialty training curricula for dermatology, but mostly to those chairing university departments responsible for education. We should not let things slip through our fingers. At the prospects of restricted

hospital resources for dermatology, we are threatened from two sides: lack of general medical knowledge and skills (so far considered to be internistics), and failure to master surgical skills pertinent to skin and subcutaneous tissue including phlebology. There are many countries, including Austria, Germany, Spain and UK, which may serve as a good example of how the things should be managed. However, strong opposition may be expected from many colleagues, especially surgeons and internists, but it should not be a reason to give up. The crucial first step for our Dermatological Society, along with chairwomen and chairmen of the University Departments is to include basic specialty training programs in dermatology. These programs should include a minimum of surgical skills (not only skin biopsy or simple excisions), while specialized dermatology centers should offer advanced training in surgical dermatology, phlebology, and some other areas (we actually used to, like allergology). Only a collective effort may make headway. International societies and many colleagues, experts in the field of dermatology, could give best assistance to this purpose. If we fail to react immediately, we simply risk losing a large part of our specialty taken over by others, from doctors to beauticians. It has already been happening over the last years. In the near future, we may witness specialists of physical medicine, plastic or general surgery, specialists of "anti-aging medicine", oncologists, pediatricians, rheumatologists and many others, to set standards of care and regulate our practice. It will, of course, be only our fault.

Though dermatosurgery seems to be the weakest point, many other areas, even those well established by our predecessors more than a century ago, may be lost for dermatology: just like allergology and phlebology. The former has already been officially transferred to internists as a subspecialty, and as such it may be lost for future generations of dermatologists.

In some countries of the former Yugoslavia, internists-allergologists have already found themselves best suited to diagnose and treat atopic and contact dermatitis! As a result of our passiveness, phlebology has been limited to conservative care of venous ulcers and a bit of diagnostics but crucial therapeutic aspects of chronic venous insufficiency like ambulatory phlebectomies, foam sclerotherapy or endovenous vein ablation techniques, are being done by vascular surgeons. Nevertheless, the first two procedures have been devised and practiced by dermatologists for decades, and the last modern techniques were mastered and promoted also by our colleagues (S. Schuller-Petrović, T. M. Proebstle, M. P. Goldman, M. Stücker...).

In efforts to reach the goal we may ask and get expert guidelines and advice from many of our

foreign colleagues, especially those already having strong connections to our country. They will surely be willing to help.

I do hope that this appeal will find its way to all responsible for remedying our profession, by enabling young colleagues to be actually involved in areas of dermatology so far underrepresented, forgotten and even unregistered within our specialty and subspecialty curricula. With every year lost, we risk to allow others to confine us to “second-class” doctors, prescribing creams and lotions for ill-defined skin changes nobody wants to deal with. In other words, as a specialty, we are signing our own death warrant. The ball is now in the court of the *Serbian Association of Dermatovenereologists* and Heads of University Dermatology Departments. Let’s hope they will succeed!

# Genital Herpes

Marina JOVANOVIĆ\*

Faculty of Medicine of the University of Novi Sad, Clinic of Dermatovenereology Diseases,  
Clinical Center of Vojvodina, Novi Sad, Republic of Serbia

\*Correspondence: Marina Jovanović, E-mail: prof.drmarina@gmail.com

UDC 616.988:578.82]:616.97

## Abstract

Genital herpes is a chronic, nearly always active herpes simplex virus (HSV) infection of sacral ganglia, that may appear bilaterally and in more ganglia than previously thought. It represents one of the most prevalent sexually transmitted infections, and the most frequent cause of genital ulcer disease in the general populations of developed countries. It is caused by HSV type-2 (HSV-2) in 60-80% of cases, with HSV-1 infections causing the remainder. Genital herpes caused by HSV-1 is on the rise. Since genital HSV-1 infections have higher risk for transmission from mother to infant during delivery than HSV-2, they account for 30% of all cases of neonatal herpes. Serological studies have found prevalence of HSV-2 in the general population of developed countries to be up to 25%. Thirty years ago, herpes was defined as “Today’s Scarlet Letter” in the absence of reliable serological tests and highly effective medications, for diagnosis and treatment of genital herpes. In 2000, apart from virus isolation in cell culture (70% sensitivity), that has long been regarded as the diagnostic gold standard, type specific serological tests and highly effective antiviral agents have evolved. However, the following questions were raised: should serological testing be routinely recommended in asymptomatic patients; can antiviral therapy reduce asymptomatic shedding of the virus; can antiviral therapy reduce sexual transmission of infection; can antiviral therapy reduce acquisition of viral copathogens, such as human immunodeficiency virus (HIV)? Now, ten years later, we know the answers. Type specific HSV DNA detection by real-time PCR assays (100% sensitivity) are tests of choice for every person with recurrent genital ulcers lasting more than 4 days, and must be available in those laboratories currently performing a significant number of PCR tests for different purposes. Type specific IgG serology assays are indicated in all asymptomatic persons who are at increased risk for HSV infection. In sexually active patients experiencing  $\geq 6$  recurrences per year, daily suppressive dose of acyclovir, valacyclovir or famciclovir should be discontinued after a maximum of a year of continuous antiviral therapy in order to reassess recurrence frequency. If necessary, the therapy should be restarted after at least two recurrences. With such expansive diagnostic possibilities and more aggressive therapeutic approaches, we can define genital herpes not as a “Scarlet Letter”, but as a “widespread untoward consequence of human sexuality”.

## Key words

Herpes Genitalis + diagnosis + drug therapy + epidemiology + etiology + therapy + prevention and control + vaccination; Signs and Symptoms; Serologic Tests; Polymerase Chain Reaction; Recurrence; Immunocompromised Host; Infant, Newborn; Pregnancy Complications; Acyclovir; Antiviral Agents

Recent data encourage the definition of genital herpes as a chronic, nearly always active herpes simplex virus (HSV) infection of sacral ganglia, that may appear bilaterally and in more ganglia than previously thought (1).

## Epidemiology

Genital herpes represents one of the most prevalent sexually transmitted infection and the most frequent

cause of genital ulcer disease in the general populations of developed countries (2). It is caused by HSV type-2 (HSV-2) in 60-80% of cases, with HSV-1 infection causing the remainder (3). Genital herpes caused by HSV-1 is on the rise and accounts for nearly half of new cases in developed countries, especially among young adults of white ethnicity in the UK. This may be due to a reduced exposure to HSV during childhood, and to increasing practice of oral sex (4). The increased genital

HSV-1 positivity rate of 64% in young women, aged 24 years or younger, is likely to affect the overall positivity rates among their local population (5). Since genital HSV-1 infections have higher risk for transmission from mother to infants during delivery than HSV-2, they account for 30% of all cases of neonatal herpes.

Serological studies have found prevalence of HSV-2 in the general population of developed countries to be up to 25%; a total number of 29 million cases in men, and 12.3 million cases of HSV-2 infection in women of Eastern Europe and Central Asia (WHO 2003) (6). The presence of HSV-2 antibodies almost always indicates a genital infection, while presence of HSV-1 antibodies may also indicate orolabial herpes, depending on the clinical presentation. About 1 in 5 adults in the USA have genital herpes, but only 9% of them are aware of their infection (7). Under-diagnosing is increasing, being the main obstacle for effective control of transmission. In one study, HSV-2 was isolated from genital specimens in about 72% of persons with asymptomatic genital herpes (8).

## Etiology and pathophysiology

Genital herpes is caused by herpes simplex viruses (HSVs). There are two types of HSVs: type-1 (HSV-1) which has primarily and traditionally been associated with oro-facial infections, and HSV type-2 (HSV-2) with anogenital, sexually transmitted infections. However, differentiation of HSV-1 from HSV-2, based on anatomical site of infection is not absolute, since genital herpes may frequently be caused by HSV-1 as a consequence of orogenital sexual relationships. Infection occurs during a close contact with mucous membrane, abraded skin lesions or mucosal secretions of a person who has genital lesions, or is shedding HSV. Viral invasion of epithelial cells happens at the site of exposure, and then HSV ascends via sensory nerves to the sacral root ganglia and enters a lifelong latent state. Recurrent episodes are due to HSV reactivation. Viruses travel along the sensory neurons to the corresponding mucocutaneous area (3). Intermittent reactivation of virus from sacral ganglia and lytic replication in the epithelium is thought to result in viral shedding at the genital mucosa, with or without symptoms, predominantly at the site of primary acquisition (3). The anatomic patterns of genital HSV reactivation, and the resulting immune response for clearing the virus, may increase the risk of sexual HSV transmission and the acquisition of viral co-pathogens, e.g., a human immunodeficiency virus (HIV) type 1. HSV-2 has been linked to the acquisition and transmission of HIV-1. Genital ulcers from HSV may facilitate the transmission

of HIV through mucosal disruptions. The infiltration of CD4+ lymphocytes in herpetic lesions creates targets for HIV attachment and entry.

It has been shown that HSV reactivates in the genital tract in more than 90% of persons, while nearly one-half of HSV shedding days are without symptoms. The most common sites of viral shedding in women are vulva, cervix and perianal region. More recent studies suggest that HSV-2 reactivates at regions overlapping genital sites from multiple ganglia. Infection of the contralateral ganglia may occur during primary or recurrent infection. Thus, HSV shedding occurs nearly continuously at widely spaced regions of the genital tract (9).

The clearance of virus from mucosal surfaces probably depends on a number of factors, including the local immunologic response. It has been demonstrated that HSV-specific cytotoxic CD8+ T cells accumulate near sensory nerve endings in genital skin during subclinical HSV-2 reactivation. Moreover, it has recently been shown that HSV-specific CD8+ T cells persist at the site of a genital ulceration for more than 6 months (10), which may explain why some episodes of HSV shedding are asymptotically cleared within hours, while others progress to genital lesions (9).

If each episode of reactivation elicits a persistent immune response to clear the virus, the patterns of widespread reactivation may explain the role of HSV-2 in increasing the risk of HIV-1 acquisition (9).

## Clinical manifestations

First infection with either herpes simplex virus type 1 (HSV-1) or type 2 (HSV-2) is termed primary infection and results in either symptomatic disease at the site of viral entry (i.e. on the face or genital area), or asymptomatic, and thus unrecognized infection. In addition, there may be systemic symptoms, similar to other acute viral illnesses (11). The primary HSV genital infection can be asymptomatic or characterized by the appearance of painful mucocutaneous vesicles on the genital area, 4 to 7 days after sexual intercourse, which evolve into erosions and crusts. Spontaneous healing occurs in 5 to 10 days (12).

The lesions and natural history of the resulting HSV-1 and HSV-2 infections are very similar. However, because HSV-2 is almost always associated with genital disease, whereas HSV-1 is associated with both oropharyngeal and genital disease, acquisition of HSV-1 usually results in lesions of the oro-pharynx and around the mouth and on the lips and chin, but occasionally the eyes are also affected. Sexual transmission of HSV most often causes infection of the genital mucosa, genital skin



(penile and labial) and perigenital region. Viruses from genital secretions may also infect other areas, including the eyes, oropharynx and rectal mucosa (13).

Primary herpetic infection, when a HSV seronegative person acquires HSV-1 or HSV-2, is usually the most severe manifestation of infection. Following primary exposure to HSV-1 children may develop severe oro-pharyngitis. Such episodes resolve spontaneously, but recurrences are possible (infection persists in the cervical ganglia). Similarly, if an individual has not been exposed to HSV-1 in childhood, he or she may develop severe genital lesions following sexual exposure to HSV-2 later in life. As with HSV-1 infections, primary HSV-2 infections resolve spontaneously, but recurrences are likely to occur (the infection persists in the sacral ganglia) (13).

In cases of initial, non-primary infection, i.e. when a person with antibodies to HSV-1 subsequently acquires HSV-2, the genital infection is less severe, but it is also associated with recurrences.

In most cases of genital herpes (80–90%) the disease progresses subclinically, but may become symptomatic at any time (13).

The incubation period of both HSV-1 and HSV-2 is usually from two to 10 days (up to four weeks). Therefore, the first episode may indicate either recent or long-lasting infection. Recurrent herpetic infection is associated with reactivation of the virus. The recurrences arise per month. The localization of the primary and recurrent lesions usually coincides. Both oral and genital herpes are manifested by acute recurrences followed by varying periods of latency, when the virus remains in a non-multiplying episomal form in the nuclei of the neurons within the ganglia. Commonly, each episode or recurrence is characterized by a patch of redness at the site of the recurrence, followed by a localized papular and then a vesicular rash. The vesicles contain a clear fluid that contains many thousands of infectious viral particles. These vesicles burst, forming shallow ulcers or erosions that eventually crust and heal spontaneously without leaving scars. These episodes usually last less than 10 days, but may be prolonged as a result of secondary bacterial infection or immunosuppression (13).

The main clinical symptoms in females are: papular and/or vesicular rash on genitals or thighs; genital ulcerations; dysuria; vaginal and/or cervical discharge; dyspareunia; inguinal discomfort. The main clinical manifestations are: papular and vesicular rash on vulva, perineum, thighs; urethritis; vaginal discharge; dysuria; dyspareunia; hyperemia of the mucous membranes of vulva and vagina; cervicitis (13).

The main clinical symptoms in males are: papular and/or vesicular rash on genitals or thighs; genital ulcerations; perineal pain; dysuria; inguinal discomfort. The main clinical manifestations are: papular and vesicular rash on thighs, penis, perineum; urethral discharge; dysuria (13).

The main clinical symptoms in newborns (and/or infants) are: vesicular skin rash; keratoconjunctivitis; mild pyrexia; lethargy; convulsions. The main clinical manifestations are: vesicular skin rash; keratoconjunctivitis; mild pyrexia; irritability; convulsions (13).

The main clinical complications of genital herpes infections are: viral meningitis; radiculomyelopathy with involvement of sacral nerves; extensive vesicular skin rash; increased risk for acquiring and shedding human immunodeficiency virus (HIV). The main clinical complications of genital herpes infections in newborns (and/or infants) are: generalized skin rash; encephalitis; infant death (13).

Genital and oral herpes are life-long infections. Neonatal herpes (including neonatal encephalitis) as well as increased risk for acquiring and shedding human immunodeficiency virus (HIV) are the most serious consequences of genital herpes infection (14).

Reactivation of latent HSV leads to subclinical (asymptomatic shedding) or symptomatic genital mucocutaneous outbreaks. Symptomatic recurrent flares occur in 20 to 50% of patients with anti-HSV antibodies (12). When infection involves the genital region, subsequent recurrence frequency is greater for HSV-2 than HSV-1 infection (11). Genital HSV-1 infection leads to less frequent outbreaks (mean recurrence rate: 1.3/ year) than HSV-2 infection (15). Recurrences are milder than the primary infection, characterized by more limited and less painful unilateral (or bilateral) lesions, without systemic symptoms (11). Following a symptomatic first episode of HSV-2 genital infection, a median recurrence rate is four recurrences during the first year.

The rate of recurrence usually decreases over time, but in about one quarter of patients it increases. Immunosuppressed patients have more severe and frequent recurrences. The recurrence rate is lower in patients with recurrent genital herpes (12).

## Diagnosis

Clinical diagnosis of genital herpes is non-specific and insensitive. Since the classic herpes is not a typical herpes, and that majority of patients have atypical lesions, dependence on clinical diagnosis alone should be maximally avoided (2).

**Laboratory diagnosis**

Laboratory confirmation should be done in all persons with suspected genital herpes. Methods used for the diagnosis could be classified into direct detection of HSV in lesions and serology testing.

**HSV detection**

In all patients with recurrent genital ulcers of unknown etiology and actual lesions lasting more than 4 days, diagnostic confirmation is recommended by performing assays that directly detect HSV in genital specimens. Testing swabs should be taken from the base of the lesion (ulcer or unroofed vesicle) and transported in viral medium (11). HSV detection could be done by using virus isolation in cell culture or HSV DNA detection in muco-cutaneous swabs by using nucleic acid amplification tests (NAATs) e.g., real time polymerase chain reaction (PCR) (11,13,16). Both methods allow virus typing. HSV detection using PCR has been shown to be the method of choice (11).

*Nucleic acid amplification tests*

HSV detection by real-time PCR is superior compared with virus culture and represents the gold standard for laboratory diagnosis of genital herpes, because it increases HSV detection rates in mucocutaneous swabs by 11-71% compared with virus culture (3). PCR increases sensitivity from average 70%, using viral culture, to almost 100% (17). Moreover, it allows less strict sample transportation conditions. When compared with traditional PCR, real-time PCR allows detection and virus typing in a single test. It also allows simplified conditions of performance and lowers the risk of cross contamination (11,13). A more recent study has shown that when compared with virus culture, HSV-1 and HSV-2-type-specific PCR conducted with real time, has significantly improved the turnaround time, with almost 70% of tests having been reported in less than 24h (16). Thus, it significantly improved the diagnosis of genital herpes without additional cost. In order to provide results at the preferred costs, real-time PCR assays must be available in those laboratories currently performing a significant number of PCR investigations for different purposes (16). The main disadvantage of real-time PCR assays is that they cannot test virus resistance using routine methodologies (11).

*Viral isolation in cell culture*

In the past, virus isolation in cell (e.g., human fibroblasts) culture has been the "cornerstone" of HSV diagnosis (13). The isolation rate from actual lesions (swab/scraping must be taken from active

lesions during viral shedding, which, on average, lasts 4 days) ranges between 90% from vesicular or pustular lesions, 70% from ulcers to 27% at the crusting stage. Its advantages include high specificity and detection of active infection within a clinical lesion. It allows virus typing and antiviral sensitivity testing by routine methodologies (11). The characteristic cytopathic effect of HSV in tissue culture appears within 24-72 hours, but may take up to five days (13). It is not only being slow (7-10 days) and less sensitive than PCR, but rather labour intensive and expensive. Its storage and transport conditions affect the sensitivity (11).

When using cell culture, specific HSV typing can be done on the infected cell cultures by direct immunofluorescence (DIF) (using fluorescein isothiocyanate or immunoperoxidase-labeled type-specific monoclonal antibodies), or by testing supernatant by nucleic acid amplification tests (NAATs) with specific primers (13).

*Alternative tests for virus detection in settings with limited laboratory facilities*

Alternative assays for virus detection are not generally recommended, since they are 10-100 fold less sensitive when compared with virus culture (11). They offer detection of HSV antigen in settings with limited laboratory facilities.

*Antigen detection*

Viral antigen detection can be performed on swabs by enzyme immunoassay (EIA) or by direct immunofluorescence (DIF) (by using fluorescein-labeled monoclonal antibodies) on smears/tissue sections.

Antigen detection enzyme immunoassay may offer a rapid diagnostic alternative in symptomatic patients with typical presentations, when sensitivity may be even higher than that of virus culture (but lower for cervical and urethral swabs). However, most commercially available EIAs do not differentiate between serotypes (11, 13).

Direct immunofluorescence can be a valuable diagnostic tool when performed in populations with high-prevalence of genital herpes. For asymptomatic patients its sensitivity may be less than 50% in comparison with cell culture (11,13).

**HSV serology testing**

Serologic tests detect antibodies to HSV in the blood, and indicate an ongoing latent infection. Unfortunately, serological tests (type- or non-type-specific) alone, cannot suggest the etiology of a persisting genital lesion with any degree of certainty (13).



Traditionally, serologic tests for anti-herpes simplex virus (HSV) antibodies have been of a limited value for the treatment of patients with genital herpes (18,19). Although the number of genital HSV-1 infections has been increasing, HSV-1 seropositivity is usually associated with orolabial infection. Since HSV-2 infection, limited to the oral mucosa, occurs rarely, HSV-2 seropositivity is considered synonymous for genital infection. While a positive HSV-2 serologic test result does not exclude other causes of genital eruptions, it may be useful to justify antiviral treatment in selected patients. On the other side, complete absence of seropositivity may be useful to exclude genital herpes. It has been reported that at least 12% of patients with a clinical history of genital herpes have no serologic evidence of infection (20). One study reported that serologic testing contributed to diagnosis in 79% of patients with recurrent genital eruptions of unknown etiology (21). As HSV-1 recurs less frequently than HSV-2, specific typing has not only diagnostic and therapeutic, but a prognostic utility as well. Moreover, many cases of genital herpes are transmitted by persons who are unaware of the fact that they are infected, or do not know how to recognize the symptoms. The great majority of these persons intermittently shed the virus. More than half of "asymptomatic" patients can be taught to recognize the symptoms. Thus, determination of specific serostatus allows more comprehensive counseling and better management (11,18,23).

Type-specific and non-type-specific antibodies to HSV develop during the first weeks after infections, and during this period, a "window", the test results will be negative. Although the detection of HSV-specific immunoglobulins-class M (IgM) in the absence of IgG response (type-specific IgG becomes detectable 2 weeks to 3 months after the onset of symptoms) is theoretically useful for detection of recent herpes infection (19), IgM response will also be detected in a third of patients with recurrent genital herpes caused by HSV-2. Thus, detection of IgM represents a poor indicator of recent infection (13). Moreover it has limited availability in routine diagnostic practice (11).

Traditionally, the epidemiologic gold standard has been the Western blot analysis (sensitivity > 94% and > 99%, whereas specificity > 94% and > 99% for HSV-1 and HSV-2, respectively), but being rather expensive, it is available only in a few research centers. The majority of patients who are seropositive for herpes simplex virus type 2 (HSV-2) by Western blot analysis are unaware of their symptoms (unrecognized infection) or have a subclinical infection.

Regarding serologic immunoassays for HSV antibodies that were commercially available in 1991, these tests suffered from poor sensitivity and specificity. The tests used relative reactivity against HSV-1 and HSV-2 to determine which subtype was dominant. Both types share many same antigens. The overall sensitivity and specificity was about 70%. The tests were often unable to detect antibodies to HSV-2 in patients with antibodies to both viral subtypes.

A new generation of enzyme immunoassays with a high degree of sensitivity (88% for HSV-1 and 95-98% for HSV-2) and specificity (99% for HSV-1 and 97-98% for HSV-2) have been developed and they are commercially available for nearly two decades: Gull HSV-1, HSV-2 gG IgG and Gull HSV-1, HSV-2 gG IgM type specific ELISA (Gull Laboratories' Salt Lake City, Utah, USA); POckit™ HSV-2 (Diagnology, UK); Cobas® Core HSV-2 IgG EIA (Roche, Basel, Switzerland). The results are rapidly obtained and inexpensive. These tests are based on the antigenically unique, type-specific glycoproteins gG-2 for HSV-2 and/or gG-1 for HSV-1. The POckit HSV-2 Rapid Test only determines HSV-2 seropositivity and provides rapid (6 minutes) results with sensitivity of 96% and specificity of 97% compared with the Western blot analysis (22).

Currently, several commercial type-specific HSV serologic tests with reported sensitivity > 95% and specificity > 97% are available, e.g.: Focus HerpeSelect ELISA and Immunoblot; Katon HSV-2 assay. Regarding rapid point-of-care tests, several tests are commercially available, e.g., Biokit HSV-2 assay, previously POckit™ HSV-2, with sensitivity and specificity > 92% (11). Rapid, point-of-care serologic tests for sexually transmitted infections can be used outside the routine laboratory and in less sophisticated clinical settings. The first FDA-cleared HSV-2 rapid test (POckit) for whole blood and serum was described in 1999, but in recent years, new assays with native gG-2 have been developed, such as the lateral-flow immunochromatographic assay (LFIA), which represents a rapid, sensitive and specific point-of-care device for detection of herpes simplex virus type-2-specific IgG antibodies in serum and whole blood. The sensitivity of the HSV-2 LFIA compared to that of the HerpeSelect ELISA (which uses recombinant gG-2 antigen) was 100% with specificity of 97.3% (23).

In conclusion, HSV-type-specific serological testing is a useful diagnostic tool, but it is not recommended for routine use in all asymptomatic patients. Moreover, it is valuable only if it is done

according to endorsed consensus guidelines. According to the 2010 European guidelines for the management of genital herpes (11), type-specific serologic testing is indicated in the following groups:

1. patients with history of recurrent or atypical genital disease of unknown etiology when direct virus detection methods have been negative;
2. patients with first-episode genital herpes at the onset of symptoms, where differentiation between primary and established infection indicates counseling and management (the absence of HSV IgG against the virus type recovered in the genital lesion is consistent with the primary infection);
3. sexual partners with genital herpes, where concerns are raised about transmission;
4. asymptomatic pregnant women, where there is a history of genital herpes in the partner, since clinical diagnosis of genital herpes at the time of delivery correlates relatively poorly with HSV detection from genital sites by either culture or PCR and fails to identify women with asymptomatic HSV shedding;
5. persons with high-risk sexual behaviour;

Testing of HIV-infected patients and HIV-infected pregnant women is not routinely recommended (11).

## Management

### First-episode genital herpes

First episodes of genital herpes are frequently associated with general and local complications. Therapy should be commenced as soon as possible and on clinical suspicion alone.

#### *Antivirals*

Currently, no therapy alters the natural course of genital herpes infection. Acyclovir, valacyclovir and famciclovir are all effective only in reducing the severity and duration of episode.

Oral antiviral drugs should be given within the first 5 days of the episode, or while new lesions are still forming. The only indication for the use of intravenous therapy is when the patient is unable to swallow or tolerate oral medications because of vomiting. Being less effective than oral agents, topical agents should not be recommended. Patients with sustained systemic symptoms, new lesion development, and complications, should continue therapy beyond five days. The recommended regimens are presented in Table 1. (11).

#### *Supportive measures*

Saline bathing and the use of topical anaesthetic agents e.g., lignocaine of gel or ointment should be recommended (11).

#### *Counseling*

When counseling patients with first episode genital herpes, the following issues should be discussed during one or two sessions: transmission risks including subclinical shedding; limited impact of condoms and antivirals; information about pregnancy is important both to men and women.

#### *Management of complications*

Hospitalization may be required for the following complications: urinary retention, meningism, superinfection of lesions (by the rule, candida occurs during the second week) (11).

### Recurrent genital herpes

Strategy for managing genital herpes recurrences includes supportive therapy only, episodic antiviral treatment, and suppressive antiviral therapy. It may vary according to recurrence frequency, symptom severity, and relationship status, for most patients, being supportive only, with local saline bathing or topical petroleum gel.

#### *Episodic antiviral treatment*

Oral acyclovir, valacyclovir and famciclovir are effective at reducing the duration and severity of recurrent genital herpes. No advantages of one therapy over another, or extended 5-day treatment over ultra-short therapy were reported. The recommended regimens – all five days long – are presented in Table 1. (11).

#### *Suppressive therapy*

Suppressive therapy should be given to patients with a recurrence rate equivalent to  $\geq 6$  recurrences/year, but even patients with a lower rate of recurrence will also benefit from a reduced rate of recurrence with treatment.

Safety and resistance in patients on long-term therapy have been achieved through 18 years of continuous surveillance. Even after prolonged periods of suppression, many patients will find no significant improvement in disease frequency or severity, upon discontinuation and reassessment. The recommended regimens are presented in Table 1. (11).

The optimal total daily dose of suppressive acyclovir therapy is 800 mg, and full suppressive effect is usually only obtained five days into treatment. It is very important to mention that once-daily acyclovir does not suppress genital herpes recurrences. Therapy should be discontinued after a maximum of a year of continuous antiviral therapy to reassess recurrence frequency, providing the patient is willing to accept this course of treatment. A small number of patients will experience a reduction in recurrence frequency compared with pre-suppression symptomatic



Table 1. Antiviral therapy in the management of the immunocompetent individuals with genital herpes

Therapy	Duration		Drug		
	Course	Days	Acyclovir	Valacyclovir	Famcyclovir
Genital herpes					
First-episode				Daily regimen	
	5-day course	5	200 mg x 5 400 mg x 3	500mg x2	250 mg x 3
Recurrent					
	5-day course	5	200 mg x 5 400 mg x 3		
	Short course	1			1000 mg x2
		2	800 mg x 3		
		3		500 mg x 2	
	Suppression	≤ 365	200 mg x 4 400 mg x 2	250 mg x 2	
< 10 per year				500 mg x 1	250 mg x 2
> 10 per year				250 mg x 2 1000 mg x 1	

levels. The minimum period of assessment should include two recurrences. The treatment should be restarted in patients who continue to have significant symptoms (11).

To prevent clinical symptoms, short courses of suppressive therapy may be given e.g. for holidays, exams, etc.

#### *Viral shedding and transmission during suppression therapy*

Acyclovir, valacyclovir and famcyclovir all suppress symptomatic and asymptomatic viral shedding. Interestingly, partial suppression of viral shedding does not necessarily correlate with reduced transmission. However, it has been shown that suppressive therapy with valacyclovir 500 mg a day (in those with 10 or fewer recurrent episodes per year), significantly reduces transmission in serodiscordant couples (24), thus, it should be considered in addition to the use of condoms and selective sexual abstinence.

#### **Management of HSV in immunocompromised and HIV positive patients**

##### *Management of the first episode of HSV*

In patients with advanced HIV infection (not in HIV positive patients with normal CD4+ T lymphocyte

counts), or in those in whom new lesions continue to form from 3 to 5 days, a higher dose should be considered. Treatment should be given for 5-10 days, or at least until all lesions have re-epithelialized which will often exceed the usual 10 day treatment that is given to HIV negative patients. If fulminant disease occurs than intravenous aciclovir should be administered. The recommended initial doses are given in Table 2. (11).

##### *Management of recurrent disease*

Standard doses of antiviral drugs should be effective in those without evidence of immune failure. In those with advanced disease, it may be necessary to double the standard dose and to continue therapy beyond 5 days. The recommended doses are given in Table 2. (11).

##### *Suppressive therapy*

Suppressive antiviral therapy for HSV is effective and well tolerated. Standard suppressive doses of acyclovir are effective. Valacyclovir is more effective when given twice daily, compared to once daily dose (1000 mg) (25). If these agents are not successful in controlling the disease, then famciclovir 500 mg twice a day should be tried (Table 2.).

Table 2. Antiviral therapy in the management of immunocompromised and patients with advanced HIV and genital herpes

Therapy	Duration		Drug		
	Course	Days	Acyclovir	Valacyclovir	Famcyclovir
Genital herpes					
First-episode				Daily regimen	
	10-day course	5 - 10	200-400 mg x 5 400-800 mg x 3	500-1000 mg x 2	250-500 mg x 3
Recurrent					
	10-day course	5 - 10	400 mg x 5 800 mg x 3		
	Suppression	≤ 365	400 mg x 2	500 mg x 2	500 mg x 2

#### *Management of recalcitrant herpes in immunocompromised individuals*

Being rare in immunocompetent individuals, clinically refractory lesions of genital HSV represent a major problem in patients with severe immunodeficiency. Algorithms for treatment in such situations include the following: confirmation of genital herpes by PCR or culture; increased dose of acyclovir to 800 mg 5x daily, or orally taken valacyclovir of 1000 mg twice daily, or famciclovir of 750 mg twice daily; isolation of virus by culture and sensitivity testing.

In patients with drug resistant genital herpes and accessible lesions, topical trifluridine or topical cidofovir gel should be given 3 times daily until complete healing. Alternatively, imiquimod cream three times weekly or topical foscarnet (2.4%) during 20 minutes twice daily should be advised. In patients with drug resistant genital herpes and non-accessible lesions, intravenous foscarnet 40 mg/kg/BW every eight hours during 2-3 weeks or until lesions heal, should be commenced (11).

#### **HSV suppression to limit HIV progression**

According to a recent randomized placebo-controlled trial in individuals with early HIV (those individuals not on HAART and with CD4+ T lymphocyte counts above 350), dually infected with HIV-1 and herpes simplex virus type-2, the standard doses of suppressive antiviral therapy (acyclovir 400 mg bid), sustained CD4+ T lymphocyte counts above accepted treatment levels, reduced the need for HAART for 2 years by 16% in the treatment group (26).

#### **Partner management**

When partner counseling, it is worth to follow the further topics: role of asymptomatic shedding in

transmission of genital herpes; partner notification after type-specific antibody testing; recognition of genital herpes recurrences after counseling, which can substantially reduce HSV transmission; reduction of transmission by using condoms in association with suppressive antiviral treatment (11).

#### **Management of pregnant women with first episode of genital herpes**

Though acyclovir administration during pregnancy has not been associated with any consistent fetal/neonatal adverse effects other than transient neutropenia, the use of acyclovir or any other antiviral drug, has not been licensed during pregnancy. Since valacyclovir is the l-valine ester, safety data for acyclovir may be transferred in late pregnancy to valacyclovir (27). Famciclovir should currently be avoided (11).

#### *First and second trimester acquisition*

Management of pregnant women with first episode of genital herpes in the first or second trimester includes oral or intravenous acyclovir therapy in standard doses. Daily suppressive therapy with acyclovir will provide anticipation of vaginal delivery and prevent the need for delivery by Caesarean section if starts from 36 weeks gestation (Table 3) (11).

#### *Third trimester acquisition (IV, C)*

Management of pregnant women with first episode of genital herpes during the third trimester includes Cesarean section that should be considered in all women taking oral or intravenous acyclovir suppressive therapy that should start at 36 weeks gestation (Table



Table 3. Antiviral therapy in the management of pregnant women with first episode genital herpes

Therapy	Strategy	Duration	Drug	Delivery
Genital herpes I episode	Course	Days	Acyclovir	
			Daily regimen	
I or II trimester	5-day course	5	200 mg x 5 400 mg x 3	
	Suppression	Start at 36 weeks gestation	400 mg x 3	Vaginal
III trimester	5-day course	5	400 mg x 3	
	Suppression	Start at 36 weeks gestation	400 mg x 3	Cesarean section

3.). This may prevent HSV lesions at term. The risk of viral shedding during delivery is very high, especially in pregnant women developing symptoms within 6 weeks prior to delivery. If vaginal delivery cannot be avoided, then acyclovir given during delivery intravenously to the mother and subsequently to the baby, may be considered and the pediatrician should be informed (11).

#### *Management of pregnant women with recurrent genital herpes*

The risk of neonatal herpes is low in women with recurrent genital herpes and they should be informed about it.

If there are no genital lesions at delivery, there are no indications for Cesarean section (to prevent neonatal herpes), and vaginal delivery is indicated. If there are genital lesions at delivery, there are also no indications for Caesarean section (to prevent neonatal herpes), and vaginal delivery is indicated. However, this can only be approved if fully agreed by obstetricians, neonatologists, and local medico-legal advice.

If there is a history of HSV lesions at the onset of delivery, daily suppressive acyclovir in standard doses, from 36 weeks gestation may prevent HSV lesions at term, as well as the need for delivery by Cesarean section (Table 4.) (11).

#### *Management of recurrent HSV in early pregnancy*

Administration of acyclovir for suspected acquisition of genital herpes in early pregnancy is widely advocated, despite the fact that the safety of acyclovir has not fully been established. Contrary to this, in recurrent genital herpes continuous or episodic therapy is not

recommended in early pregnancy and should be avoided. Newer antivirals should also be avoided. Rarely, in severe and complicated cases, administration of acyclovir cannot be avoided, and an individual assessment should be made.

#### **Management of HIV positive women with recurrent HSV infection**

There is some evidence that HIV antibody positive women with genital HSV ulcerations may be more likely to transmit HIV infection during pregnancy than others (28). These women should be advised to take daily suppressive acyclovir from 32 weeks gestation that would reduce the risk of transmission of HIV-1 infection and increased possibility of preterm labour (Table 5.) (11).

#### **Preventing acquisition of infection**

Any strategy for prevention of neonatal herpes must involve both parents and include the following issues:

- at the first antenatal visit, all women should be asked if they, or their partner, have had genital herpes;
- female partners of men with genital herpes, but with no personal history of genital herpes, should be advised about using condoms during pregnancy especially in the last trimester of pregnancy, including abstinence from sex at the time of lesional recurrences and in the last six weeks of pregnancy;
- the effectiveness of suppressive treatment of the male partner has not been evaluated so far, thus currently it can only be recommended;
- all pregnant women should be advised to avoid orogenital contact, especially in the last trimester of

Table 4. Antiviral therapy in the management of pregnant women with recurrent genital herpes

Therapy	Strategy	Duration	Drug	Delivery
Recurrent genital herpes	Course	Days	Acyclovir	
Daily regimen				
Early pregnancy				
III trimester	5-day course	5	400 mg x 3	Vaginal
History of lesions on delivery	Suppression	Start at 36 weeks gestation	400 mg x 3	Vaginal
Lesions on delivery				Cesarean section
No lesions on delivery				Vaginal

pregnancy;

- all women should undergo careful vulva inspection at the onset of delivery ;
- all persons, including mothers, with active oral HSV lesions or herpetic whitlow should avoid direct contact between lesions and the neonate.

**Management of the neonate**

If the baby was born to mother with first-episode genital herpes at the onset of labour, the following instructions should be followed after delivery:

- HSV culture of urine and stool, from the babies oropharynx, eyes and surface sites, should be taken;
- the potential benefits and risks of starting intravenous acyclovir without waiting for the results of these cultures should be discussed;
- if acyclovir is not started immediately, the neonate should be closely monitored for signs of lethargy, fever, poor feeding or lesions.

If the baby was born to mother with recurrent genital herpes at the onset of labour, the parents and health care workers should be advised to consider HSV in differential diagnosis by searching for signs of infection on the skin, eyes or mucous membranes, especially during the first two weeks of life (11).

**Prevention**

Biomedical strategies for the control of genital herpes such as therapeutic approaches, abstinence, monogamy, the use of condoms, or vaccination have not given satisfactory results so far, and they are in different phases

of development. The greatest expectancy is developing of efficient vaccines (29).

**Immunoprophylactic HSV-2 vaccines**

Production of vaccines against HSV infection has been slowed down because of their ineffectiveness in men and in HSV-1 (+) women (30). Investigations conducted so far have resulted in mass vaccination among women with HSV-1,-2 (31).

Antigens for prophylactic vaccines are viral membrane glycoproteins HSV-1 gB8 and HSV-2 gD. The produced antibodies are neutralizing and protective (31).

Prophylactic HSV-2 gD2-alum-MPL vaccine consists of HSV-2 gD, alum, and MPL adjuvant (3-de-0-acyl monophosphoryl lipid A). In phase I/II, and phase III of clinical trials the vaccine has been administered intramuscularly according to -0, -1, and -6 months schedule. High safety level and high tolerance of the vaccine have been reported. Prevention of genital HSV-2 symptoms has been achieved in 73% to 74% of HSV (-) women and prevention of HSV-2 infection in 39% to 46% of HSV (-) women. Further investigations are needed to explain the role of adjuvant and sex in vaccine efficacy (31, 32).

Because the average efficacy of the vaccine in the prevention of HSV-2 infection is only 42%, it raises the question of whether partial efficacy can be beneficial. In mathematical model considering the natural course and dynamics of HSV-2 transmission, the fulfillment of two conditions is necessary to answer the questions: 1. if vaccination reduces disease transmission through

Table 5. Antiviral therapy in the management of HIV positive pregnant women with recurrent genital herpes

Therapy	Strategy	Duration	Drug	Delivery
HIV-positive and HSV-1 and/or HSV-2 positive	Course	Days	Acyclovir	
No history of genital herpes				Vaginal
History of genital herpes	Suppression	Start at 32 weeks gestation	400 mg x 3	Vaginal
Lesions on delivery				Cesarean section
No lesions on delivery				Vaginal

reducing the number of carriers, then it may have the main role in the control of HSV-2 infection; 2. universal vaccination of the female population aged 10 to 12 years, would reduce HSV-2 among general population, including men (30, 33, 34).

The perspective of prophylactic HSV-2 vaccines lies in successful termination of phase III clinical trials and their approval.

The vaccine is expected to fulfill the above-mentioned conditions having in mind that HSV-2 infection has a small probability of transmission along with a long-term infectivity (33).

#### Immunotherapeutic HSV-2 vaccines

The recombinant gD2-alum vaccine demonstrated fewer recurrences in a double-blind, placebo-controlled clinical trial, fewer viral culture-proven genital HSV recurrences per month, and a lower average number of recurrences during the year of the study in the vaccinated group (35).

In a double-blind, placebo-controlled clinical trial, the ICP10DPK vaccine completely prevented HSV-2 recurrences in 37.5% of patients in the vaccinated group, while 100% of patients in the placebo group had at least one recurrence 6 months after vaccination (36).

#### Experimental HSV-2 vaccines

Recombinant adenovirus vaccine rAdgB8 is in experimental phase of investigation on laboratory animals. The vaccine is administered intranasally and it induces good mucous immunity (37).

Vaccines HSV-2 dl5-29 and HSV-2 dl5-29-41L are also in experimental phase of investigation on laboratory animals (38).

Intranasal immunization with a proteoliposome-derived cochleate containing recombinant gD protein (AFCo1gD) conferred protective immunity against genital herpes in mice. These data may be useful in the development of a mucosal vaccine against genital herpes (39).

#### Final observations

Thirty years ago, in the absence of reliable serological tests and highly effective medications for diagnosis and treatment of genital herpes, herpes was defined as "Today's Scarlet Letter". In 2000, apart from virus isolation in cell culture, that has long been regarded as the diagnostic gold standard (70% sensitivity), type-specific serologic tests and highly effective antiviral agents have been developed. However, the following questions were impuited: should we routinely recommend serologic testing in asymptomatic patients; does antiviral therapy reduce asymptomatic shedding of the virus; is sexual transmission of infection reduced by antiviral therapy; does antiviral therapy reduce the acquisition of viral copathogens? Ten years later, we now know the answers. Type specific HSV DNA detection by real-time PCR assays (100% sensitivity) is the diagnostic test of choice for every person with recurrent genital ulcers of unknown etiology that last more than 4 days, and must be available in those laboratories currently performing a significant number of PCR investigations for different purposes. Type specific gG serology testing is indicated in all asymptomatic persons who are at increased risk for HSV infection. For those sexually active patients experiencing  $\geq 6$  recurrences per year, daily suppressive dose of acyclovir, valacyclovir or famciclovir should be discontinued after a maximum of a year of continuous



antiviral therapy to reassess recurrence frequency. If necessary, the therapy should be restarted after at least two recurrences. In order to prevent transmission and the acquisition of viral copathogens, therapy must suppress simultaneous HSV reactivations from bilateral sacral ganglia. With such a variety of testing modalities and more aggressive therapy, we can now define genital herpes not as a “Scarlet Letter”, but as the “Widespread Untoward Consequence of Human Sexuality” (1).

## References

- Hook E W III. An evolving understanding of genital herpes pathogenesis: is it time for our approach to therapy to change as well? *Editorial. J Infect Dis* 2010;201:486–7.
- Le Cleach L, Trinquart L, Lebrun-Vignes B, Giraudeau B, Chosidow O. Oral antiviral therapy for prevention of genital herpes outbreaks in immunocompetent and nonpregnant patients (Protocol). *The Cochrane Library* 2011;3 [serial on the Internet]. 2011[cited 2011 Apr 15];3. Available from: [http://onlinelibrary.wiley.com/doi/cochrane/clsystrev/articles/CD009036/pdf\\_fs.html](http://onlinelibrary.wiley.com/doi/cochrane/clsystrev/articles/CD009036/pdf_fs.html)
- Gupta R, Warren T, Wald A. Genital herpes. *Lancet* 2007;370(9605):2127-37.
- Scoular A, Norrie J, Gillespie G, et al. Longitudinal study of genital infection by herpes simplex virus type 1 in Western Scotland over 15 years. *BMJ* 2002;324:1366–7.
- Pen KC, Adelson ME, Mordechai E, and ohn. Blaho JA. Genital Herpes Simplex Virus Type 1 in Women: Detection in Cervicovaginal Specimens from Gynecological Practices in the United States. *J Clin Microbiol* 2010;48(1):150–3.
- Looker KJ, Garnett PG, Schmid GP. An estimate of the global prevalence and incidence of herpes simplex virus type 2 infection. *Bull World Health Organ* 2008;86(10):805-12.
- Leone P, Fleming DT, Gilsenan AW, Li L, Justus S. Seroprevalence of herpes simplex virus-2 in suburban primary care offices in the United States. *Sex Transm Dis* 2004; 31(5):311–6.
- Wald A, Zeh J, Selke S, et al. Reactivation of genital herpes simplex virus type 2 infection in asymptomatic seropositive persons. *N Engl J Med* 2000;342(12):844–50.
- Tata S, Johnston C, Huang ML, Selke S, Margaret A, Corey L, et al. Overlapping reactivations of herpes simplex virus type 2 in the genital and perianal mucosa. *J Infect Dis* 2010;201:499–504.
- Zhu J, Koelle DM, Cao J, Vazquez J, Huang ML, Hladik F, et al. Virus specific CD8<sup>+</sup> T cells accumulate near sensory nerve endings in genital skin during subclinical HSV-2 reactivation. *J Exp Med* 2007;204(3):595-603.
- Patel R, Alderson S, Geretti A, Nilsen A, Foley E, Lautenschlager S, et al. 2010 European guideline for the management of genital herpes. [cited 2011 Apr 15]. Available from: [http://www.iusti.org/regions/europe/Euro\\_guideline\\_HSV\\_2010.pdf](http://www.iusti.org/regions/europe/Euro_guideline_HSV_2010.pdf)
- Sen P, Barton SE. Genital herpes and its management. *BMJ* 2007;334(7602):1048-52.
- Domeika M, Bashmakova M, Savicheva A, Kolomiec N, Sokolovskiy E, Hallen A, et al. Eastern European Network for Sexual and Reproductive Health (EE SRH Network). Guidelines for the laboratory diagnosis of genital herpes in eastern European countries. *Eurosurveillance* [serial on the Internet] 2010 [cited 2011 Apr 15];44:1-7. Available from: <http://www.eurosurveillance.org/images/dynamic/EE/V15N44/art19703.pdf>
- Corey L, Wald A. Genital herpes. In: KK Holmes, PF Sparling, WE Stamm, P Piot, J W Wasserheit, L Corey, et al, editors. *Sexually transmitted diseases* 4th ed. New York: McGraw Hill; 2008. p. 399-437.
- Engelberg R, Carell D, Krantz E, Corey I, Wald A. Natural history of genital herpes simplex virus type 1 infection. *Sex Transm Dis* 2003;30(2):174-7.
- Saeed K, Pelosi E. Comparison between turnaround time and cost of herpes simplex virus testing by cell culture and polymerase chain reaction from genital swabs. *Int J STD AIDS* 2010;21:298-9.
- Gerreti AM, Brown DW. National survey of diagnostic services for genital herpes. *Sex Transm Infect* 2005;81:316-7.
- Goldman B D. Herpes Serology for Dermatologists *Arch Dermatol* 2000;136:1158-61
- Morrow R, Friedrich D. Performance of a novel test for IgM and IgG antibodies in subjects with culture-documented genital herpes simplex virus-1 or -2 infection. *Clin Microbiol Infect* 2006;12:463-9.
- Cowan FM, Johnson AM, Ashley R, Corey L, Midel A. Relationship between antibodies to herpes simplex virus (HSV) and symptoms of HSV infection. *J Infect Dis* 1996;174:470-5.
- Munday PE, Vuddamalay J, Slomka MJ, Brown DW. Role of type specific herpes simplex virus serology in the diagnosis and management of genital herpes. *Sex Transm Infect* 1998;74:175-8.
- Ashley RL, Eagleton M, Pfeiffer N. Ability of a rapid serology test to detect seroconversion to herpes simplex virus type 2 glycoprotein G soon after infection. *J Clin Microbiol* 1999;37:1632-3.
- Laderman EI, Whitworth E, Dumauel E, Jones M, Hudak A, Hogrefe W, et al. Rapid, sensitive, and specific lateral-flow immunochromatographic point-of-care device for detection of herpes simplex virus type 2-specific immunoglobulin G antibodies in serum and whole blood. *Clin Vaccine Immunol* 2008;15(1):159–63.
- Corey L, Wald A, Patel R, et al. Once-daily valaciclovir to reduce the risk of transmission of genital herpes. *N Engl J Med* 2004;350:11-20.
- Conant MA, Schacker TW, Murphy RL, Gold J, Crutchfield LT, Crooks RJ; International Valaciclovir HSV Study Group. *Int J STD AIDS* 2002 Jan;13(1):12-21.
- Lingappa, JR; Baeten, JM; Wald, A; Daily aciclovir for HIV-1 disease progression in people dually infected with HIV-1 and herpes simplex virus type 2: a randomized placebo-controlled trial. *Lancet* 2010; 375:9717:824-33.
- Sheffield JS, Hill JB, Hollier LM, Laibl VR, Roberts SW, Sanchez PJ, Wendel GD Jr Valacylovir prophylaxis to prevent recurrent herpes at delivery: a randomised clinical trial. *Obstet Gynecol* 2006;108:141–7.
- Drake AL, John-Stewart GC, Wald A et al. Herpes simplex virus type 2 and the risk of intrapartum human immunodeficiency virus transmission. *Obstet Gynecol* 2007; 10;403-9.
- Jovanović M, Karadagić Đ, Golušin Z, Brkić S, Poljački M. Experimental vaccines for prevention sexually transmitted infections. [Eksperimentalne vakcine za prevenciju polno prenosivih infekcija]. *Med Pregl* 2009;62:42-8..
- Garnett GM. Role of herd immunity in determining the effect of vaccines against transmitted disease. *J Infect Dis* 2005;191(Suppl 1):S97-106.
- Rupp R, Stanberry LR, Rosenthal SL. *New biomedical*

approaches for sexually transmitted infection prevention: vaccines and microbicides. *Adolesc Med Clin* 2004;15:393-407.

32. Stanberry LR, Spruance SL, Cunningham AL, Bernstein DI, Mindel A, Sacks S, et al. Glycoprotein-D-sdjuvant vaccine to prevent genital herpes. *N Eng J Med* 2002;347:1652-61.

33. Rupp R, Stanberry LR, Rosenthal SL. Vaccines for sexually transmitted infections. *Pediatr Ann* 2005;34(10):818-24.

34. Garnett GP, Dubin G, Slaoui M, Darcis T. The potential epidemiological impact of a genital herpes vaccine for women. *Sex Transm Infect* 2004;80:24-9.

35. Straus SE, Corey L, Burke RL, et al. Placebo-controlled trial of vaccination with recombinant glycoprotein D of herpes simplex virus type 2 for immunotherapy of genital herpes. *Lancet* 1994; 343: 1460-1463.

36. Casanova G, Cancela R, Alonzo L, et al. A double-blind study

of the efficacy and safety of the ICP10deltaPK vaccine against recurrent genital HSV-2 infections. *Curtis* 2002; 70: 235-239.

37. Gallichan WS, Rosenthal KL. Specific secretory immune response in the female genital tract following intranasal immunization with a recombinant adenovirus expressing glycoprotein B of herpes simplex virus. *vaaccine* 1995;13:1589-95.

38. Hoshino Y, Pesnicak L, Dowdell KC, Lacayo J, Dudek T, Knipe DM, et al. Comparison of immunogenicity and protective efficacy of genital herpes vaccine candidates herpes simplex virus 2 dl5-29 and dl5-29-41L in mice and guinea pigs. *Vaccine* 2008;26:4034-40.

39. Campo JD, Lindqvist M, Cuello M, Bäckström M, Cabrera O, Persson J, et al. Intranasal immunization with a proteoliposome-derived cochleate containing recombinant gD protein confers protective immunity against genital herpes in mice. *Vaccine* 2010; 28:1193-200.

## Genitalni herpes

### Sažetak

**Definicija:** Danas se genitalni herpes definiše kao unilateralna ili bilateralna hronična, uglavnom kontinuirano aktivna infekcija (jednog ili više) senzornih gangliona sakralnog plexusa (S2,S3,S4), izazvana herpes simpleks virusom (HSV).

**Epidemiologija:** Genitalni herpes predstavlja jednu od najučestalijih seksualno prenosivih infekcija i najčešći uzrok anogenitalnih ulceracija u opštoj populaciji razvijenih zemalja. U 60-80% slučajeva izazivač je HSV tip-2 (HSV-2), a njime je inficirano 15-25% odraslih osoba u SAD, preko 29 miliona muškaraca i 12,3 miliona žena u zemljama Istočne Evrope i Azije. U Velikoj Britaniji u 50% slučajeva izazivač je HSV tip-1 (HSV-1), a isti tip je odgovoran za razvoj 30% svih slučajeva neonatalnog herpesa. Dok se prisustvo anti HSV-2 antitela u serumu značajno (ali ne i isključivo) povezuje sa postojanjem genitalne infekcije, anti HSV-1 antitela mogu biti prisutna i kod orolabijalnog herpesa.

**Etiopatogeneza:** U 60-80% slučajeva izazivač genitalnog herpesa je HSV tip-2 (HSV-2). Kod 72% osoba bez simptoma, HSV-2 je izolovan iz genitalne regije. Primarna infekcija se najčešće odvija u koži i sluznicama. Iako apsolutna podela ne postoji, primarna infekcija izazvana virusom tip 1 se najčešće manifestuje orofacijalno, gingivostomatitisom, keratokonjunktivitisom, znatno ređe encefalitisom, a infekcija virusom tip 2 genitalnim ulceracijama. Do infekcije dolazi nakon bliskog kontakta sa sluznicama, lediranom kožom i mukoznim sekretima osobe koja ima genitalne lezije ili rasipa HSV asimptomatski. Na mestu kontakta virus ulazi u epitelne ćelije, da bi potom ascedento putem senzornih nervnih završetaka dostigao do senzornih gangliona. Virus zatim ostaje nereaktivan

u ćelijama gangliona, tip 1 najčešće trigeminalnog, a tip 2 sakralnog. Do reaktivacije virusa dolazi kod oko 90% inficiranih osoba. Tokom reaktivacije HSV-2 koja se simultano ili sukcesivno dešava u jednom ili više uni/bilateralnih sakralnih gangliona, virus putuje descendno duž senzornog neurona ka odgovarajućoj mukokutanoj regiji. Nakon tzv. litičke replikacije virusa u epitelnim/epidermalnim ćelijama, započinje rasipanje virusa sa velike površine genitalne/analne regije, koje je u skoro 50% trajanja asimptomatsko, i može se okarakterisati kao pretežno kontinuirano. Najčešće se rasipanje virusa odvija sa vulve, cerviksa i perianalne regije kod žena. Rezultati novijih istraživanja pokazuju da se reaktivacija HSV-2 odvija sukcesivno ili istovremeno unutar većeg broja gangliona uni/bilateralno. Do infekcije kontralateralnog gangliona može doći za vreme primarne ali i rekurentne epizode genitalnog herpesa.

Tokom reaktivacije, lokalni imunološki odgovor (koji za cilj ima odstranjenje HSV), na mestu reaktivacije (genitoanalna regija) pospešuje prenošenje infekcije HSV i virusom humane imunodeficijencije tip-1 (HIV-1). Metu za privlačenje i prodor HIV predstavlja infiltracija CD4+ limfocita u herpetične lezije. U uslovima supkliničkog rasipanja u toku HSV-2 reaktivacije, utvrđena je akumulacija za HSV specifičnih citotoksičnih CD8+ limfocita oko završetaka senzornih nervnih vlakana u mukokutanim genitalnim regijama. Štaviše, specifični citotoksični CD8+ limfociti mogu perzistirati u blizini genitalnih ulceracija tokom vremenskog perioda dužeg od šest meseci čime se može objasniti zašto pojedine epizode rasipanja HSV protiču asimptomatski i traju samo nekoliko časova, dok u drugim lezije progrediraju do ulceracija.

**Kliničke manifestacije:** Primarna HSV genitalna infekcija nastaje u slučaju da prethodno HSV seronegativna osoba postane inficirana HSV-1 ili HSV-2, i u najvećem broju slučajeva predstavlja i najtežu manifestaciju infekcije. Primarnu HSV genitalnu infekciju odlikuje pojava mukokutanih vezikula lokalizovanih u genitalnoj regiji, do kojih dolazi 4 do 7 dana posle seksualnog kontakta. Vezikule potom prelaze u erozije i kraste, a spontana sanacija nastaje nakon 5-10 dana. Primarna HSV genitalna infekcija može proticati i asimptomatski. Nakon primarne infekcije HSV-1, deca mogu razviti težak oblik orofaringitisa. Ova epizoda zaceljuje spontano, ali se mogu javiti recidivi (infekcija perzistira u cervikalnom ganglionu). Analogno ovome, ukoliko odrasla osoba nije bila u detinjstvu inficirana HSV-1 ona može razviti teške genitalne lezije ukoliko do infekcije HV2 dođe u kasnijem životu. Primarna infekcija HSV-2 takođe zaceljuje spontano, ali se mogu javiti recidivi (infekcija perzistira u sakralnim ganglionima).

U slučaju početne, ali ne i primarne infekcije, koja nastaje u slučaju da prethodno HSV-1 seropozitivna osoba postane inficirana HSV-2, genitalna infekcija je po pravilu blaža ali se takođe mogu razviti recidivi.

Inkubacioni period u HSV-1 i HSV-2 infekciji obično traje od 10 dana do 4 nedelje. U najvećem broju slučajeva (80-90%), bolest progredira supklinički, ali može postati simptomatska u bilo kom vremenskom trenutku. Stoga, prva epizoda može označiti novonastalu ali i već dugo prisutnu infekciju.

Glavni klinički simptomi i znaci kod osoba ženskog pola su dizurija, dispareurija, pojačan vaginalni i cervikalni sekret, osećaj težine u ingvinumu, papulo-vezikulozni osip u predelu vulve, perineuma, nadkolenica, uretritis, hiperemija vaginalne sluznice, cervicitis.

Glavni klinički simptomi i znaci kod osoba muškog pola su disurija, bol u predelu perineuma, ureteralni iscedak, papulo-vezikulozni osip na butinama, penisu, perineumu, i pojava genitalnih ulceracija.

Glavni klinički simptomi i znaci kod novorođenčadi/male dece su blaga pireksija, letargija, vezikulozna oспа, keratokonjunktivitis i konvulzije.

Glavne kliničke komplikacije koje se mogu javiti kod obolelog od genitalnog herpesa su virusni meningitis, radikulomijelopatija sa zahvatanjem sakralnih nerava, ekstenzivni vezikulozni osip po koži i povećani rizik od nastanka HIV infekcije. Kod novorođenčadi, glavne kliničke komplikacije su generalizovana vezikulozna oспа po koži, encefalitis i smrt. Najteže komplikacije koje se mogu javiti u toku genitalnog herpesa su neonatalni herpes sa razvojem neonatalnog encefalitisa, kao i nastanak HIV infekcije sa posledničnim rasipanjem HIV.

Recidivi: Recidivantne epizode su posledica reaktivacije

virusa i u početku one se javljaju mesečno. Lokalizacija lezija najčešće se podudara sa lokalizacijom promena u primarnoj epizodi. I oralni i genitalni herpes prolaze kod različit broj reciva do kojih dolazi nakon reaktivacije virusa koji ostaje prisutan u tzv. epizodnoj formi (bez replikacija) u jedrima neurona koja se nalaze unutar ganglionu. U klasičnim slučajevima, svaku epizodu recidiva karakteriše pojava lokalizovanog pločastog crvenila sa sledstvenim razvojem papula. Vezikule su ispunjenje bistrim sadržajem i u njima se nalaze hiljade infektivnih partikula virusa. Nakon prskanja vezikula, za njima ostaju erozije, ulceracije, a potom kraste i spontano isceljivanje bez ožiljavanja. Dužina trajanja epizode recidiva je oko 10 dana, ali ona može biti znatno veća ukoliko se radi o imunokompromitovanoj osobi ili o nastaloj sekundarnoj bakterijskoj infekciji. U 20-50% svih slučajeva, recidivi protiču simptomatski. Ukoliko se radi o genitalnoj regiji, broj recidiva je veći kod HSV-2 nego kod HSV-1 infekcije. U slučaju genitalnog herpesa izazvanog HSV-1, prosečan broj recidiva iznosi 1,3 godišnje, dok je kod HSV-2 infekcije prosečan broj recidiva oko 4 u toku prve godine posle infekcije. Po pravilu recidivi protiču sa blažom kliničkom slikom u odnosu na primarnu epizodu, bez sistemskih znakova infekcije, a karakteriše ih pojava ograničenog broja manje bolnih, uni/bilateralnih lezija. Vremenom godišnja stopa recidiva opada, ali kod 30% može rasti. Imunosuprimirane osobe imaju klinički teže epizode i višu stopu recidiva u odnosu na imunokompetentne.

**Dijagnoza:** Nedijagnostikovani genitalni herpes se širi epidemijski. Samo 9% HSV-2 seropozitivnih osoba zna da je inficirano. Značaj postavljanja tipski specifične dijagnoze ima veliki edukativni značaj, s obzirom da 60% osoba bez simptoma nauči da prepozna i prijavi recidiv. Značaj specifične tipizacije ima veliki prognostički značaj, s obzirom da do reaktivacije HSV-2 u genitalnom traktu dolazi kod 90% svih inficiranih a da je broj recidiva genitalnog herpesa u prvoj godini posle primarne infekcije 5x veći u odnosu na HSV-1. Pre trideset godina, u odsustvu relevantnih seroloških testova i efikasne terapije, o problemu genitalnog herpesa pisano je kao o gorućem problemu, crvenim slovima (eng. *Scarlet Letter*). Kultivacija HSV (70% senzitivnost), tipski specifične serološke reakcije i antivirusna terapija označili su početak novog milenijuma ali i nametnuli sledeća pitanja: da li treba uvesti rutinsko testiranje; da li supresivna terapija prevenira transmisiju; da li supresivna terapija smanjuje rizik od HIV infekcije? Deset godina kasnije, mi imamo odgovor na ova pitanja. Zlatni dijagnostički standard za svaku osobu sa rekurentnim genitalnim ulceracijama nepoznate etiologije koje traju više od 4 dana, jeste tipski specifičan PCR u realnom vremenu (100% senzitivnost), koji mora da obezbedi svaki centar koji raspolaze ovom tehnikom. Svaku osobu za koju se



danas smatra da poseduju povišen rizik za dobijanje HSV infekcije a koja ne daje anamnezne podatke o genitalnom herpesu treba serološki testirati tipski specifičnim, tzv. gG testovima. Trenutno, nekoliko testova (senzitivnost > 95%) je komercijalno dostupno: *Focus HerpeSelect ELISA* i *Immunoblot*; *Katon HSV-2* test. Brzi tipski specifični testovi kao što je to *Biokit HSV-2 assay*, ranije dostupan kao *POCKit™ HSV-2*, (senzitivnost i specifičnost > 92%, rezultat dostupan posle nekoliko minuta), danas imaju prednost s obzirom da se mogu izvoditi izvan laboratorija. Prvi brzi test koji je 1999. godine bio odobren od strane FDA (eng. *Food and Drug Administration*) agencije je *POCKit™ HSV-2*. Nova generacija brzih tipski specifičnih gG testova zasniva se na upotrebi nativnog gG-2 antigena, npr. LFIA test (eng. *lateral-flow immunochromatographic assay*), koji predstavlja brz, pouzdan, visoko senzitivni i specifičan metod za dokazivanje HSV-2 specifičnih IgG antitela u serumu I u punoj krvi. Senzitivnost *HSV-2 LFIA* u odnosu na *HerpeSelect ELISA* (koji koristi rekombinantni gG-2 antigen) je u jednoj studiji iznosila 100% a specifičnost 97,3%. Iako serološko testiranje predstavlja koristan dijagnostički metod, ono nije rutinski indikovano kod svakog pacijenta koji nema simptome infekcije. Prema evropskom vodiču iz 2010. godine, testiranju podležu sledeće osobe:

1. pacijenti koji daju anamnestičke podatke o rekurentnim ili atipičnim ulceracijama nepoznate etiologije, kada se metodama direktnog dokazivanja nije utvrdilo prisustvo virusa u leziji;
  2. pacijenti u prvoj epizodi genitalnog herpesa u trenutku pojave prvih simptoma, kada je potrebno razlikovati primarnu od ustaljene infekcije, što ima veliki terapijski značaj (odsustvo HSV IgG protiv tipa virusa koji je izolovan iz genitalne lezije, potvrđuje primarnu infekciju);
  3. seksualni partneri osoba koje imaju genitalni herpes, ukoliko postoji povećan rizik za transmisiju;
  4. asimptomatske trudnice čiji partneri daju anamnestičke podatke za genitalni herpes, s obzirom da u vreme porođaja klinički postavljena dijagnoza genitalnog herpesa ne pokazuje značajnu korelaciju sa direktnom detekcijom (kako putem PCR tako i kultivacijom), virusa u genitalnoj regiji, što u tom trenutku otežava tj. onemogućuje identifikaciju žene koja asimptomatski rasejava virus;
  5. osobe sa visoko rizičnim seksualnim ponašanjem;
- Rutinski testirati sve HIV-om inficirane osobe i HIV-om inficirane trudnice nije opravdano.

**Lečenje u prvoj epizodi genitalnog herpesa:** Često dolazi do pojave opštih i lokalnih komplikacija, iz tog razloga lečenje treba započeti odmah i kod postojanja isključivo klinički postavljene sumnje na genitalni herpes. Primenom antivirusnih lekova aciklovira, valaciclovira ili famciclovira

može se isključivo smanjiti težina i/ili broj recidiva. Njih treba početi uzimati oralnim putem odmah, unutar prvih 5 dana prve epizode ili sve dok se stvaraju nove promene. Intravenski se antivirusni lekovi daju samo ukoliko pacijent otežano guta ili povraća, lokalno ne treba primenjivati antivirusnu terapiju. U slučaju održavanja sistemskih simptoma i znakova, pojave novih lezija ili komplikacija, lečenje treba nastaviti i posle petog dana lečenja, a preporučeni terapijski protokoli su izneti u Tabeli 1.

**Lečenje recidiva:** Lečenje može biti isključivo zasnovano na lokalnoj nezi (kupke u slanim rastvorima; aplikacija petrolej želea) ili se može uključiti i antivirusna terapija, kratkotrajna epizodna ili dugotrajna supresivna, koja se pokazala bezbednom i nakon 18 godina kontinuirane primene. Supresivna terapija se daje najčešće osobama sa  $\geq 6$  recidiva godišnje. Nakon najdužeg perioda od godinu dana kontinuirane terapije, treba je prekinuti a ukoliko se proceni racionalnim, ponoviti je tek pošto uslede najmanje dva nova recidiva. Supresivni efekat se može postići tek nakon petog dana lečenja. Optimalna ukupna dnevna doza aciklovira koja ima supresivni efekat iznosi 800 mg, ali se pri tome supresivni efekat ne može postići jednokratnim već dvokratnim ili višekratnim davanjem aciklovira (Tabela 1).

**Lečenje imunosuprimiranih i HIV pozitivnih osoba:** Kod osoba sa težim stepenom imunosupresije lečenje treba da traje duže od 5 dana a standardne doze za lečenje primarne epizode i standardne doze za lečenje recidiva treba povećati pa i udvostručiti (Tabela 2). Supresivna terapija je efikasna u standardnim dozama, s tim što je valaciclovir efikasniji kod dvokratnog davanja a ukoliko terapija ne da zadovoljavajući efekat, može se dati famciclovir (Tabela 2). Terapijska tvrdokornost: U slučaju da se sumnja na postojanje genitalnog herpesa rezistentnog na primenjenu terapiju, treba potvrditi postojanje infekcije metodom PCR ili kulturom, povisiti dozu aciklovira na 800 mg 5x dnevno i, nakon izolacije virusa, izvesti testiranje osetljivosti. Ukoliko se potvrdi rezistencija, tada se na promene ukoliko su dostupne aplikuje trifluridin ili cidofovir gel 3x dnevno do kompletnog isceljenja. Alternativno se može dati imikviimod krem 3x nedeljno ili minutna lokalna primena foscarneta 2,4% u trajanju od po 20 minuta 2x dnevno. Ukoliko promene nisu dostupne, foscarnet se daje intravenski u dozi od 40 mg/kg/TT svakih 8 časova tokom 2-3 nedelje sve do potpunog izlečenja.

**Lečenje prve epizode genitalnog herpesa kod trudnica:** Iako nije zvanično odobrena primena nijednog antivirusnog leka u trudnoći, aciklovir se koristi za lečenje prve epizode genitalnog herpesa za vreme čitave trudnoće, valaciclovir u kasnoj trudnoći, dok primena famciclovira u trudnoći valja izbegavati. Ukoliko do infekcije dođe u prvom ili drugom trimestru trudnoće, lečenje se zasniva na davanju aciklovira

u standardnim dozama. Supresivna dnevna terapija aciklovirom, ukoliko započne od 36. gestacijske nedelje, može da prevenira pojavu genitalnih lezija u vreme porođaja i tako omogući vaginalni porođaj (Tabela 3). Ukoliko do infekcije dođe u trećem trimestru, opasnost od rasipanja virusa za vreme porođaja je velika i u svim slučajevima bi porođaj trebalo obaviti carskim rezom. Supresivna dnevna terapija aciklovirom, ukoliko započne od 36. gestacijske nedelje, može da prevenira pojavu genitalnih lezija u vreme porođaja (Tabela 3). Ukoliko se trudnica ipak porodi vaginalnim putem, lečenje se zasniva na davanju u toku porođaja aciklovira intravenski i majci i novorođenčetu.

#### **Lečenje recidiva genitalnog herpesa kod trudnica:**

Trudnici sa recidivantnim genitalnim herpesom na prvom mestu treba predočiti da je rizik od razvoja neonatalnog herpesa mali i da se porođaj može obaviti vaginalnim putem. U slučaju da je trudnica u prethodnim trudnoćama u vreme porođaja imala promene nalik na genitalni herpes, supresivna dnevna terapija aciklovirom, ukoliko započne od 36. gestacijske nedelje, može prevenirati promene za vreme porođaja i potrebu za carskim rezom (Tabela 4).

Lečenje recidiva genitalnog herpesa aciklovirom u ranoj trudnoći nije poželjno i treba ga izbeći, a to se odnosi i na ostale antirusne lekove.

HIV-pozitivnoj trudnici sa recidivantnim genitalnim herpesom supresivna dnevna terapija aciklovirom ukoliko započne od 32 gestacijske nedelje može prevenirati prevremeni porođaj i smanjiti rizik od prenošenja HIV infekcije (Tabela 5).

**Prevenција neonatalnog herpesa:** Algoritam za prevenciju perinatalne infekcije moraju biti uključena oba partnera i on podrazumeva sledeće:

- U toku prve prenatalne kontrole, svaku trudnicu treba pitati za ličnu i partnerovu anamnezu o postojanju genitalnog herpesa;
- Trudnicama koje nemaju ličnu anamnezu o genitalnom herpesu, ali čiji partneri imaju genitalni herpes, treba predočiti potrebu za upotrebom kondoma za vreme trudnoće, naročito tokom poslednjeg trimestra, i apstinencije od seksa za vreme recidiva herpetičnih promena i tokom poslednjih šest nedelja trudnoće;
- Sve trudnice treba da izbegavaju orogenitalne

kontakte naročito tokom poslednjeg trimestra;

- Ukoliko je trudnica HSV seronegativna, u nedostatku opsežnijih ispitivanja terapijske efikasnosti, supresivna antivirusna terapija ostaje samo preporuka muškom partneru koji ima genitalni herpes;
- Svakoј trudnici treba obaviti detaljnu inspekciju vulvarne regije u vreme porođaja;
- Sve osobe, uključujući i porodilju, koje imaju aktivne oralne herpetične lezije ili herpetične promene lokalizovane na drugim delovima tela uključujući i prste, treba instruisati da izbegavaju direktan kontakt između lezija i novorođenčeta.

Ukoliko je trudnica u fazi prve epizode genitalnog herpesa porođena vaginalnim putem, predloženi algoritam podrazumeva sledeće:

- Dokazivanje HSV u urinokulturi, koprokulturi i kulturama briseva uzetih iz orofaringsa, konjunktiva i kože novorođenčeta;
- Procenu koristi i rizika od započinjanja intravenskog davanja aciklovira novorođenčetu pre dobijanja rezultata traženih kultura;
- Intervenciju u slučaju postojanja letargije, groznice, odbijanja hrane ili lezija suspektih na genitalni herpes kod novorođenčeta, ukoliko davanje aciklovira nije odmah započeto.

Ukoliko je trudnica u fazi rekurentne epizode genitalnog herpesa porođena vaginalnim putem, potrebno je uputiti roditelje i nadležne zdravstvene radnike da kod novorođenčeta, naročito tokom prve dve nedelje života, obrate posebnu pažnju na svaki eventualno prisutni znak koji bi ukazivao na infekciju kože, očiju ili vidljivih sluznica, te da isključe HSV infekciju.

**Prevenција:** Matematički model predviđa da će HSV univerzalna vakcinacija svih devojčica uzrasta od 10 do 12 godina redukovati prevalenciju genitalnog i neonatalnog herpesa u opštoj populaciji.

**Zaključak:** Sa ovom doktrinom koja prvenstveno podrazumeva dijagnostički imperativ i agresivnije lečenje, mi danas ne govorimo o genitalnom herpesu kao „gorućem problemu“, nego kao „masovnoj posledici ljudske seksualnosti“.

## **Ključne reči**

Genitalni herpes + dijagnoza + medikamentna terapija + epidemiologija + etiologija + terapija + prevencija + kontrola + vakcinacija; Znaci i simptomi; Serološki testovi; Lančana reakcija polimeraze; Novorođenčce; Komplikacije u trudnoći; Aciklovir; Antivirusni lekovi

## Extensive lichenoid type of Cutaneous sarcoidosis - A case report

Lidija KANDOLF SEKULOVIĆ<sup>1\*</sup>, Miroslav DINIĆ<sup>1</sup>, Tatjana RADEVIĆ<sup>1</sup>,  
Radoš ZEČEVIĆ<sup>1</sup>, Lidija ZOLOTAREVSKI<sup>2</sup>, Vukojica KARLIČIĆ<sup>3</sup>,

<sup>1</sup>Department of Dermatology and Venereology, Military Medical Academy, Belgrade, Serbia

<sup>2</sup>Center of Pathology and Forensic Medicine, Military Medical Academy, Belgrade, Serbia,

<sup>3</sup>Clinic of Pulmonology, Military Medical Academy, Belgrade, Serbia

\*Lidija Kandolf Sekulović, E-mail: sekulovi@eunet.rs

UDC 616.5-002.7-07/-08

### Abstract

Cutaneous manifestations of sarcoidosis are present in up to 25% of patients. The manifestations can be very variable, making this disease one of the „great imitators“ in dermatology. One of its clinical variants is lichenoid sarcoidosis, which is more commonly described in children. We report an adult patient with extensive lichenoid sarcoidosis with a personal history of treated pulmonary tuberculosis, without any evidence of actual pulmonary involvement with sarcoidosis. The main differential diagnosis of lichenoid sarcoidosis of lichen scrofulosorum, so thorough examinations, to exclude active tuberculosis, are essential in these cases. The patient was successfully treated with antimalarial drugs, and low-dose systemic corticosteroids.

### Key words

Sarcoidosis; Lichenoid Eruptions; Skin Diseases; Signs and Symptoms; Antimalarials; Glucocorticoids

Sarcoidosis is a multisystem granulomatous disease of unknown etiology, where pulmonary and lymph node involvement are the most frequent manifestations. Cutaneous involvement in sarcoidosis is reported in 9-37% of patients (1, 2). Being a multisystem disorder it may involve almost any organ. Clinical manifestations may be very variable, making cutaneous sarcoidosis one of the „great imitators“ in dermatology.

The most common cutaneous manifestation of acute sarcoidosis is erythema nodosum, a non-specific manifestation, while in chronic disease there are various clinical forms, most of them specific, i. e. with noncaseating granulomas on histopathological analysis of tissue samples. There are classic papular, nodular and plaque forms of sarcoidosis, and in the largest series of cutaneous sarcoidosis reported so far, the most common types were lupus pernio, scar sarcoidosis and plaque type, while papular lesions were relatively uncommon (3). However, other authors

describe papular eruptions on the periorbital region, face and neck, as the most frequent type (1, 4). Scar sarcoidosis is also common, while lupus pernio is one of the most distinctive forms of cutaneous sarcoidosis. Lichenoid sarcoidosis is a subset of the papular form of the disease, but frequently with extensive skin involvement and lichenoid appearance of individual lesions (5, 6). It is estimated that lichenoid sarcoidosis accounts for 1-2% of all cases of cutaneous sarcoidosis (6). It is more commonly reported in children (7, 8). We report an adult patient with extensive lichenoid sarcoidosis, who was successfully treated with antimalarial agents and low-dose corticosteroids.

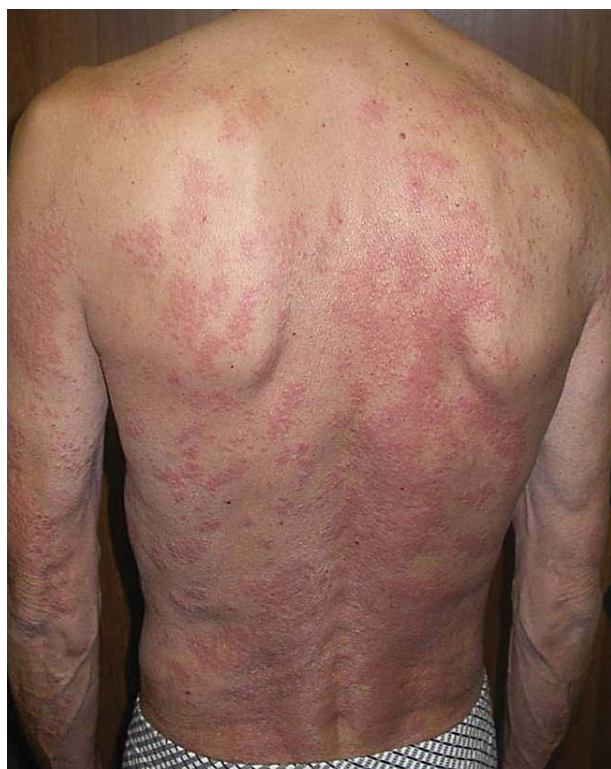### Case report

A fifty-three-year-old man was admitted to our department due to multiple asymptomatic papules and hyperpigmented macules with scales on the trunk and extremities that appeared one year before. He was

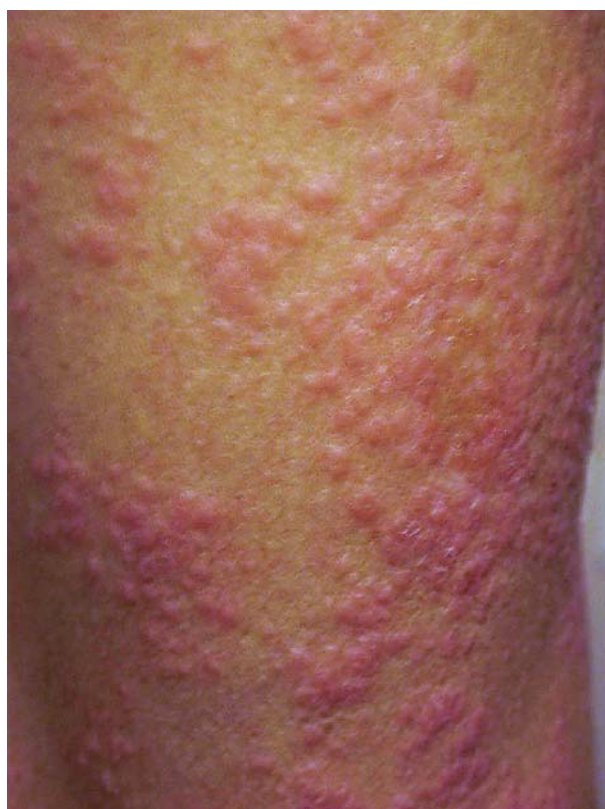

treated with a topical corticosteroid, without effects. His personal history was remarkable for pulmonary tuberculosis that was treated several years before.

On examination, multiple livid and erythematous papules, 3-5 mm in diameter, with whitish scales, were located on the trunk and extremities, with confluence of lesions and formation of plaques and brownish macules with desquamation on the upper legs (Figures 1 and 2). The face and neck were spared of skin lesions. Laboratory analyses that were within physiologic range included: erythrocyte sedimentation rate (ESR), complete blood count (CBC), blood biochemistry (glucose, urea, creatinine, total bilirubin, total protein, albumin, cholesterol, triglycerides), liver enzymes (AST, ALT, LDH,  $\gamma$ GT), immunoglobulines - IgG, IgA, IgM and routine urinalysis. Angiotensin-converting enzyme (ACE), serum calcium, calcium in 24 h-urine were also within normal limits. The intradermal tuberculin (PPD) test was negative. Skin biopsy was performed and on histopathologic analysis perivascular noncaseating epithelioid sarcoid granulomas were found within the dermis, while epidermal changes were minimal

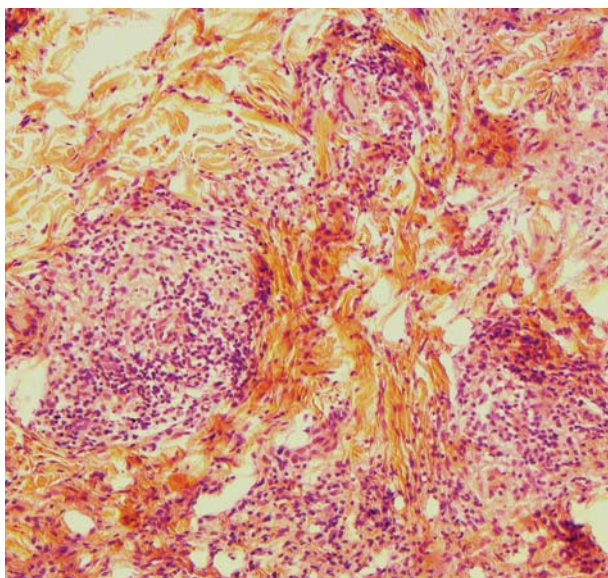


**Figure 1.** Multiple livid and erythematous papules with whitish scales on the trunk and upper limbs



**Figure 2.** Multiple lichenoid papules, 3-5 mm in diameter

(Figure 3). Acid fast bacilli and fungal cultures were not found on histopathological examination. Direct immunofluorescence (DIF) test of skin lesions revealed rare, individual IgM colloid bodies in the papillary dermis and small discrete deposits of the discontinued C3 at the basement membrane zone. Abdominal ultrasound showed normal findings. Ophthalmologic findings were normal. Chest radiography revealed circular shadows on both sides corresponding to pleural calcification, further proven by CT. Spirogram and co-transfer factor were within normal limits. Multislice computed tomography (MSCT) of the chest revealed fibrotic (scar) changes in the upper lobes and perihilar dotted calcifications; in the apical segment of the right upper lobe, a stellate formation, 3x5 cm in size, was found corresponding to sarcoidosis or tuberculosis; also, mediastinal lymph nodes up to 1 cm in diameter were detected. Bronchoscopy was performed and the patient had no macroscopical lesions. On cytological examination of bronchial aspirate, cylindrical cells, lymphocytes and red blood cells were found. Histopathological findings of transbronchial biopsy



**Figure 3.** Perivascular noncaseating epithelioid sarcoid granulomas within the dermis (H&E, x10).

specimens revealed atypical bronchoalveolar epithelial hyperplasia, and chronic nonspecific bronchitis. On direct Ziehl-Neelsen stained samples acid-resistant bacilli were not found, and they were not cultivated on three consecutive cultivations on Loewenstein. PCR analysis for *Mycobacterium tuberculosis* in sputum sample was also negative, as well as three times repeated urine cultivation on Loewenstein. Consultant pulmonologist concluded that pulmonary findings were the consequence of scar changes due to previous pulmonary tuberculosis, and also that there was no pulmonary involvement with sarcoidosis; follow-up was recommended, and treatment with corticosteroids was approved for cutaneous lesions. Treatment with oral chloroquine 250 mg/d, and depot betamethasone once every 3 weeks for three weeks time led to complete resolution of skin lesions.

## Discussion

Sarcoidosis of the skin is found in 25% of patients with sarcoidosis. It manifests with various skin lesions, with papular and plaque lesions which are the most prevalent (1-4). Papular sarcoidosis is often manifested with discrete flesh-colored papules on the head and neck, particularly in the periorbital region. These papules eventually coalesce to form annular lesions or plaques. In our patient, however, the lesions were mainly distributed on the trunk and extremities, while

the head and neck were spared. The individual lesions were erythematous papules with lichenoid appearance and whitish scales (Figure 1). These manifestations correspond to lichenoid sarcoidosis, which is the subset of papular sarcoidosis, more frequently reported in children (5-8). The main differential diagnosis of lichenoid sarcoidosis is lichen scrofulosorum, which is found in tuberculosis. In our patient, tuberculosis was not evident, based on cultivation and direct examination of the sputum samples, histopathological analysis of the lung tissue, and negative PPD intradermal test. Also, histopathological analysis of perivascular noncaseating granulomas were found in our patient, in contrast to perifollicular granulomas that are found in lichen scrofulosorum.

The etiology of sarcoidosis has not been revealed yet. It is considered to be an immunological reaction to yet unidentified antigen/s, characterized with Th1 cellular immune reaction, increased B-cell activity, persistent macrophage activation, causing granuloma formation (1-4). Among the possible etiologic agents of sarcoidosis, *Mycobacterium tuberculosis*, *Propionibacterium acnes*, *Mycoplasma* species, *Borrelia burgdorferi*, viral infections (hepatitis C, herpes viruses and others) and certain metal and other particles (beryllium, zirconium, aluminium) were all examined, but the results of various studies are conflicting (1, 9-12). It is possible that in susceptible persons (i.e. with certain HLA alleles linked to sarcoidosis susceptibility) several different antigens lead to the development of sarcoidosis. Personal history of pulmonary tuberculosis, without evidence of active disease at the time of diagnosis of cutaneous sarcoidosis, points to the possible role of *Mycobacterium tuberculosis* antigens and their fragments in the pathogenesis of the disease in our patient. Mycobacterial DNA sequences were found in the skin, lymph nodes and lung tissue of sarcoidosis patients in some studies, but these results were not confirmed in other studies (1, 10). Also, based on bronchoalveolar lavage, histopathology analysis of the transbronchial biopsy, lung sarcoidosis was ruled out, and follow-up was recommended by a consultant pulmonologist.

## Conclusion

In conclusion, lichenoid sarcoidosis with extensive involvement of the skin is not a common clinical



presentation. Skin biopsy and thorough laboratory analyses, radiological and histopathological examinations are necessary to rule out tuberculosis. The treatment can be successful by using antimalarials and low-dose systemic corticosteroids, as was proven in our patient. Other agents that can be used in the treatment of cutaneous sarcoidosis are: methotrexate, thalidomide, azathioprine, chlorambucil, minocycline, pentoxifylline, allopurinol, isotretinoin, etc. Also, infliximab, adalimumab, PUVA and UVA1 phototherapy were used in single case reports in recalcitrant cases (1).

## References:

- White HA Jr. Non-infectious granulomas. In: Bologna J, Jorizzo J, Rapini R, eds. Dermatology. London, England: Mosby; 2008. p. 1455-70.
- Tchernev G, Patterson JW, Nenoff P, Horn LC. Sarcoidosis of the skin: a dermatological puzzle: important differential diagnostic aspects and guidelines for clinical and histopathological recognition. J Eur Acad Dermatol Venerol 2010;24:125-37.
- Veien NK, Stahl D, Brodthagen H. Cutaneous sarcoidosis in Caucasians. J Am Acad Dermatol 1987;16:534-40.
- Collin B, Rajaratnam R, Lim R, Lewis H. A retrospective analysis of 34 patients with cutaneous sarcoidosis assessed in a dermatology department. Clin Exp Dermatol 2010;35:131-4.
- Nakahigashi K, Kabashima K, Akiyama H, Utani A, Miyachi Y. Refractory cutaneous lichenoid sarcoidosis treated with tranilast. J Am Acad Dermatol 2010;63:171-2.
- Garrido-Ruiz MC, Enguita-Valls AB, de Arriba MG, Vanaclocha F, Peralto JL. Lichenoid sarcoidosis: a case with clinical and histopathological lichenoid features. Am J Dermatopathol 2008;30:271-3.
- Seo SK, Yeum JS, Suh JC, Na GY. Lichenoid sarcoidosis in a 3-year-old girl. Pediatr Dermatol. 2001;18:384-7.
- Tsuboi H, Yonemoto K, Katsuoka K. A 14-year-old girl with lichenoid sarcoidosis successfully treated with tacrolimus. J Dermatol 2006;33:344-8.
- Ramos-Casals M, Mana J, Nardi N, et al. Sarcoidosis in patients with chronic hepatitis C virus infection: analysis of 68 cases. Medicine (Baltimore) 2005;84:69-80.
- Fite E, Fernandez-Figueras MT, Prats R, et al. High prevalence of Mycobacterium tuberculosis DNA in biopsies from sarcoidosis patients from Catalonia, Spain. Respiration 2006;73:20-6.
- Di Alberti L, Piatelli A, Artese L, et al. Human herpes virus 8 variants in sarcoid tissues. Lancet 1997;350:1655-61.
- Furukawa A, Uchida K, Ishige Y, Ishige I, Kobayashi I, Takemura T, et al. Characterization of Propionibacterium acnes isolates from sarcoid and non-sarcoid tissues with special reference to cell invasiveness, serotype, and trigger factor gene polymorphism. Microb Pathog 2009;46: 80-7.

## Ekstenzivna lihenoidna saroidoza kože

### Sažetak

Uvod: Sarkoidoza se na koži javlja kod 25% obolelih, a njene različite kliničke manifestacije čine je jednim od najvećih imitatora u dermatologiji. Jedna od varijanti kutane sarkoidoze je lihenoidna, koja se češće opisuje kod dece. Prikazujemo odraslog pacijenta sa lihenoidnom varijantom kutane sarkoidoze, sa generalizovanim promenama, uspešno lečenim antimalarikom i niskim dozama sistemskih kortikosteroida.

Prikaz slučaja: Muškarac starosti 53 godine, pre 20 godina lečen zbog plućne tuberkuloze, hospitalizovan je zbog brojnih generalizovanih zagasito eritematoznih glatkih papula sa beličastom skvamom, lihenoidnog izgleda, grupisanih na trupu, gornjim i donjim ekstremiteta. Promene na koži susejavile godinu dana pre hospitalizacije, a lečen je bez uspeha topijskim kortikosteroidima.

Histopatološkom analizom uzorka kože postavljena je dijagnoza kutane sarkoidoze. Na osnovu laboratorijskih analiza, radioloških pretraga i histopatološkim analizama transbronhijalne biopsije pluća, isključena je aktivna tuberkuloza pluća, a nije dokazana ni sarkoidoza pluća. Započeto je lečenje hlorkvinom 250 mg/d, uz depo preparat kortikosteroida, što je dovelo do povlačenja promena na koži.

Zaključak: Glavna diferencijalna dijagnoza lihenoidne sarkoidoze je *lichen scrofulosorum*, zbog čega je neophodno pre započinjanja lečenja isključiti tuberkuloznu etiologiju promena na koži. Antimalarici sa niskim dozama ili bez niskih doza sistemskih kortikosteroida predstavljaju terapiju prvog izbora kod generalizovanih promena u kutanoj sarkoidozi.

### Cljučne reči

Sarkoidoza; Lihenoidne erupcije; Bolesti kože; Znaci i simptomi; Antimalarici; Glukokortikoidi

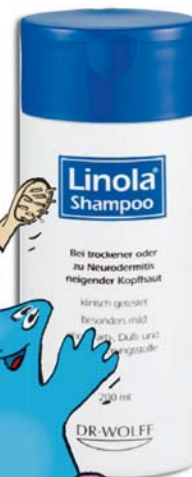

# Linola®

## Nega pre svega Vaša koža zaslužuje najbolje.

### Linola® Shampoo

- \* Sadrži izuzetno blage supstance za pranje na bazi glukoze
- \* Sprečava iritaciju i isušivanje osetljive kože glave
- \* Pogodan za svakodnevno pranje kose i za sve uzraste
- \* Bez alergena, boja i mirisa



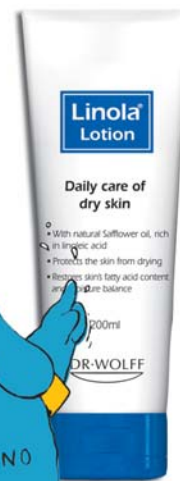### Linola® Dusch & Wasch

- \* Gel za svakodnevno tuširanje i kupanje.
- \* Istovremeno čisti i štiti kožu.
- \* Ima neutralan pH i antibakterijsko dejstvo.



### Linola® Lotion

- \* Mleko za telo za svakodnevnu negu suve i osetljive kože.
- \* Sadrži linolnu kiselinu i čičkovo ulje.
- \* Sprečava isušivanje i iritaciju kože.



**Jedinstvena nega i zaštita  
sa linolnom kiselinom  
od Dr. Wolff-a.**

 **MSFPHARM**  
Aesthetics of Derma.

Ekskluzivni zastupnik **DR WOLFF** preparata  
Orlovića Pavla 4, 11000 Beograd,  
tel.: +381 11 38 36 588, 38 36 589, 38 36 590  
info@msfpharm.com , www.msfpharm.com

**DR·WOLFF**  


## Bullous lichen planus in childhood – A case report

Biljana ARSOV<sup>1\*</sup>, Svetlana POPADIĆ<sup>1,2</sup>, Miloš NIKOLIĆ<sup>1,2</sup>

<sup>1</sup> Pediatric Dermatology Unit, Clinic of Dermatovenereology, Clinical Center of Serbia, Belgrade, Serbia

<sup>2</sup> Faculty of Medicine, University of Belgrade, Serbia

\*Correspondence: Dr. Biljana Arsov, E-mail: arsovbiljana@gmail.com

UDC 616.516-002.-1-08

### Abstract

In Europe, only 1% of all patients with lichen planus are children. We report a case of lichen planus in a 5-year-old boy with blisters developing on papules. There was no history of Hepatitis B virus vaccination in the past 12 months. Routine laboratory analyses showed no abnormalities. Hepatitis B surface antigen and anti-Hepatitis C virus antibodies were negative. Our patient had disseminated and coalesced papules on the trunk and extremities with vesicles and bullae on the hands and feet. Histopathology confirmed the diagnosis of lichen planus and bullous lichen planus. Negative direct immunofluorescence test excluded lichen planus pemphigoides. The boy was treated with prednisone 1 mg/kg/day (the dose was gradually tapered and discontinued over the next 1.5 month), ultraviolet B phototherapy, fluocinolon acetonide, and topical pimecrolimus 1% cream till complete remission after 2.5 months. Bullous form of lichen planus is seen in 1-16% of all children with lichen planus. Two months upon the completion of therapy, there were no signs of relapse. In our case, short course of systemic corticosteroids and ultraviolet B phototherapy have been safe and effective. This was the only pediatric case of bullous lichen planus treated in our Clinic in the last 20 years. Long-term prognosis of childhood lichen planus is not predictable, and there is no consensus regarding the treatment of childhood lichen planus.

### Key words

Child, Preschool; Skin Diseases, Vesicobullous; Lichen Planus; Prednisone; Phototherapy

The term “lichen” describes discrete flat skin eruptions, or an aggregate of papules, giving a patterned configuration resembling lichens commonly found growing on rocks. Lichen planus (LP), first described in 1869 by Wilson, characteristically consists of very itchy eruptions containing flat-topped, polygonal and violaceous papules with fine linear white scales, referred to as Wickham’s striae. The mucous membranes, especially the oral mucosa, may be affected. There are many clinical variants of LP: actinic, annular, atrophic, LP hypertrophic (LPH), guttate, linear, LP pigmentosus, erosive (ulcerative), follicular (lichen planopilaris), bullous LP and LP *pemphigoides* (LPP).

The etiology of LP remains unclear, although there are many theories: autoimmune mechanisms, association with certain HLA haplotypes and liver

disease - Hepatitis C virus (HCV) infection (1) and Hepatitis B virus (HBV) vaccine (2, 3).

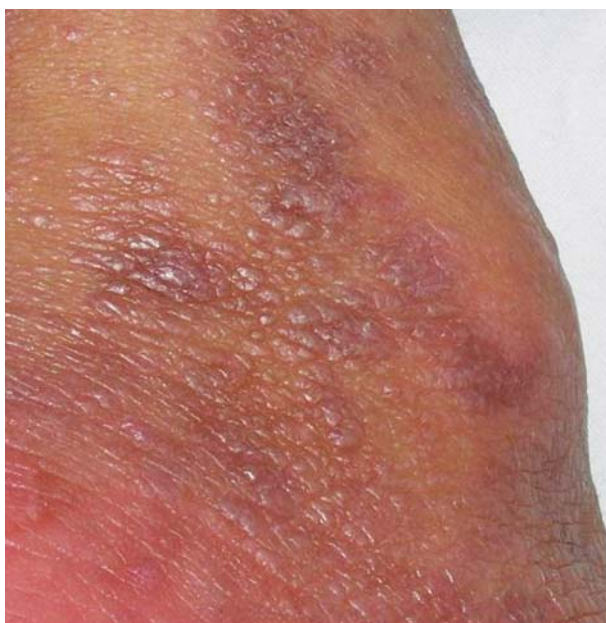### Case report

We report a case of a 5-year-old boy with a history of atopic dermatitis since the age of 3. A month and a half before admission, the first lesions appeared on the trunk and extremities. Otherwise, the boy was in good general health. Immunization was performed regularly, but not in the last 12 months. The family history was negative for LP. On admission, the lesions were disseminated all over the skin, except on the face and oral mucous membranes, with bilaterally symmetrical distribution. The eruptions consisted of flat-topped, polygonal, violaceous papules with Wickham’s striae (Figure 1). They were a few millimeters in size, coalesced into plaques, predominantly on lower back,

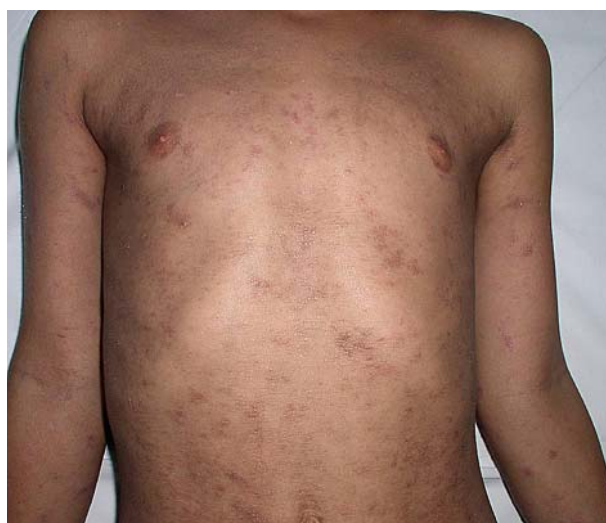dorsal parts of hands and lower legs. Scalp skin was involved with whitish non-adherent scales. On several regions, linear papules (Koebner phenomenon) were noticed (Figure 2, 4). On hands and feet, bullae developed on papules and plaques (Figure 3). Bullae were hemorrhagic on the palmar surfaces (Figure 4).

Routine laboratory tests showed no abnormalities. HBsAg and anti-HCV antibodies were negative. Histopathologic examination revealed orthohyperkeratosis with hypergranulosis, irregular acanthosis with „sawtoothing“ of the rete ridges, vacuolization of the basal cell layer, with Civatte bodies, and a dense, band-like infiltrate (Figure 5). Pigmentary incontinence was conspicuous under the epidermo-dermal junction (Figure 5, 6). In some segments, Max-Joseph spaces were progressing into frank subepidermal bullae (Figure 6). Direct immunofluorescence (DIF) test was negative.

The boy was treated with prednisone 1 mg/kg/day, broad band ultraviolet B (BB-UVB) radiation 4 times a week, (cumulative dose of 1145mJ/cm<sup>2</sup>), topical fluocinolone acetonide ointment (0.025% and 0.2%) and pimecrolimus 1% cream. Prednisone dose was gradually tapered and discontinued over the next 1.5 month, but topical therapy was continued for one more month, until complete regression of lesions. The last check-up was performed 2 months



**Figure 1.** Flat-topped, polygonal, violaceous papules with Wickham's striae.

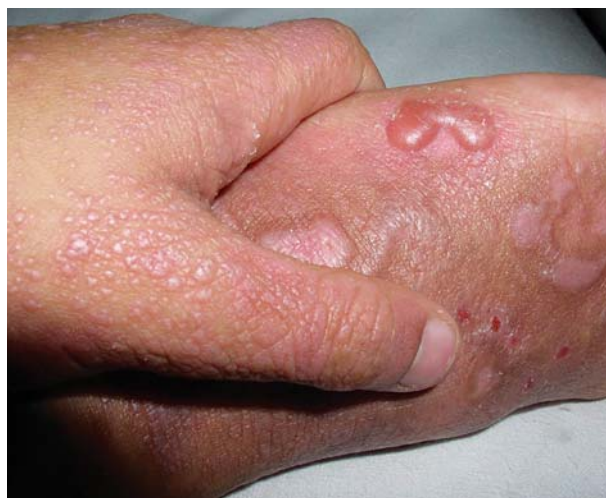

**Figure 2.** Disseminated violaceous papules and Koebner phenomenon on the trunk and arms.

after discontinuation of complete therapy, and until now, the boy presented no signs of relapse.

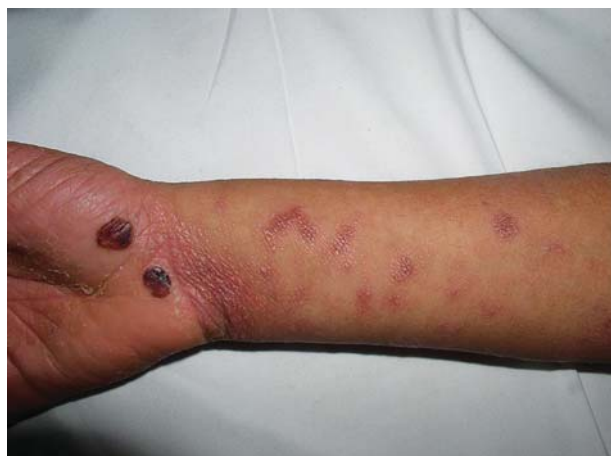## Discussion

LP is an uncommon skin disease in childhood. It is most frequently found in patients aged 30 - 60 years (4). There are only a few studies about childhood LP. In Kanwar's study (5), the earliest age of onset was 2 weeks of age. According to major published studies, the age of onset varied from 5 months to 13 years (6-8), with slight male predominance 1.1 - 3 : 1 (5, 6, 9). LP starting in childhood accounts for 1% in London



**Figure 3.** Papules on the hand, bullae surmounting papules on the foot.

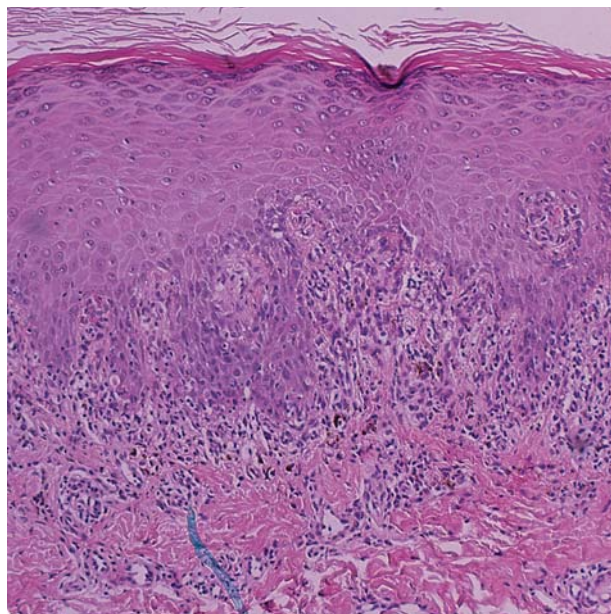




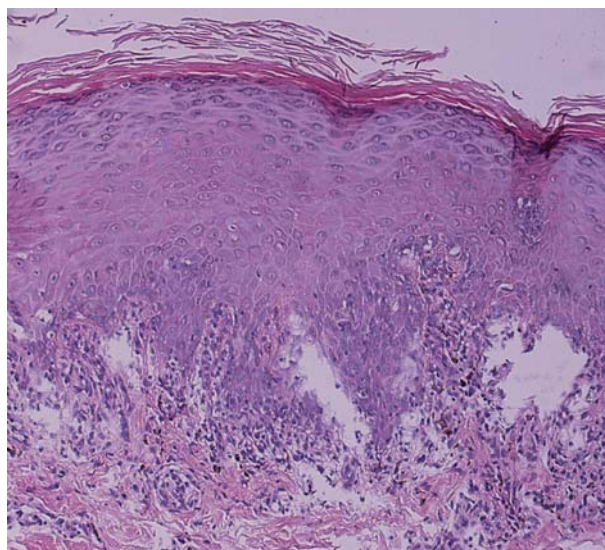
**Figure 4.** Hemorrhagic bullae on the palmar surface.

(10), 7.5% among Libyans (11), and 17.2% in India (12). Most studies of LP in children have been from India. There is an increased incidence of childhood LP in the Tropics and Subtropics (7, 12-14). Bullous LP occurs in 1 - 16% of all children with LP (5, 6, 15).

Due to the lack of long-term follow-up, often seen in retrospective studies, it is difficult to draw an inference about the most effective treatment and long-term prognosis of LP in children. Topical corticosteroids remain the treatment of choice in most patients with



**Figure 5.** Orthohyperkeratosis, hypergranulosis, irregular acanthosis, vacuolization of the basal cell layer, pigmentary incontinence and a dense band-like infiltrate (H&E, x100)



**Figure 6.** Subepidermal blister formation and dense band-like infiltrate with pigmentary incontinence (H&E, x100)

localized lesions (5, 16). The UVB phototherapy (8) is safe and effective in children with acute widespread LP. Oral corticosteroids (prednisolone 1 mg/kg/day) are given to patients with extensive/eruptive lesions (5, 6, 17). Dapsone is useful in patients with chronic, recurrent LP, and in disease control after the activity of disease is controlled by systemic corticosteroids (5, 18). Currently, the first-line treatment of mucosal lesions and localized cutaneous LP consists of potent topical corticosteroids, although recent clinical reports indicate that topical tacrolimus might be an effective treatment alternative (19, 20). Tazarotene gel 0.05% (5) is used topically on the periungual folds if few nails are involved. In contrast, due to the lack of controlled clinical trials, generalized eruptions or more severe types of cutaneous LP are still treated with a broad spectrum of various systemic agents, acitretin and oral corticosteroids (21). Furthermore, immunosuppressants e.g., mycophenolate mofetil (22), azathioprine (21), methotrexate (23), PUVA (24), low-molecular-weight heparin (25), and T-cell receptor mimic peptides (26) have been successfully used in adults. Still, it is important to keep in mind that the disease may have a spontaneous remission.

Bullous eruptions in LP were first described in 1892 by Kaposi (27), and since then, two distinct forms of LP with bullae have been described. Bullous LP is characterized by blister formation on LP lesions,

caused directly by upper dermal inflammation and liquefactive degeneration of the basal cell layer. By contrast, *lichen planus pemphigoides* (LPP) is marked by bullous eruptions on both LP lesions and normal skin. On direct immunofluorescence (DIF), histopathology of LPP reveals sub-epidermal blisters with linear deposition of IgG and/or C3 along the dermal-epidermal junction. In addition, circulating autoantibodies against epidermal basement membrane zone (BMZ) components are often found using indirect immunofluorescence (IIF) (28). In bullous LP, DIF does not show deposition of antibodies along BMZ, but IIF, using patient serum and autologous perilesional skin, may show deposition of IgG and IgA in the stratum granulosum and stratum spinosum (29 - 31). Our patient had a typical clinical presentation, and representative histopathology of bullous LP (9, 32). Negative DIF test excluded lichen planus pemphigoides.

The long-term prognosis of childhood LP is uncertain. It is limited by a small number of reported cases. Handa and Sahoo analyzed records of 87 children with LP, and most patients with classical LP showed clearance of lesions within 6 months, except for postinflammatory pigmentation that persisted in all patients (6). Uncommon variants, such as mucosal (buccal) LP, LPH, and lichen planopilaris, required a prolonged therapy up to 1 year (6). In the study of Sharma and Maheshwari, the majority of patients (97.8%) cleared in less than 1 year (9). Only one child had recurrent relapses during the follow-up period of 6 months (9).

In our population, bullous lichen planus in children seems to be very rare, since in the last 20 years we had only one patient with this presentation.

## Conclusion

LP, especially bullous LP, is a rare disease during childhood. There are few studies about LP in childhood, its therapy and outcome. We presented a 5-year-old boy with bullous LP, who responded well to a short course of systemic corticosteroid therapy, and ultraviolet B phototherapy. We believe that any information about treatment outcome of bullous LP during childhood should be widely reported in order to achieve consensus on the treatment protocol for this uncommon form of the disease.

## References

1. Birkenfeld S, Dreier J, Weitzman D, Cohen A. A study on the association with hepatitis B and hepatitis C in 1557 patients with lichen planus. *J Eur Acad Dermatol Venereol* 2011;25:436-40.
2. Limas C, Limas CJ. Lichen planus in children: a possible complication of hepatitis B vaccines. *Pediatr Dermatol* 2002;19:204-9.
3. Miteva L. Bullous lichen planus with nail involvement induced by hepatitis B vaccine in a child. *Int J Dermatol* 2005;44:142-4.
4. Kyriakis KP, Terzoudi S, Palamaras I, et al. Sex and age distribution of patients with lichen planus. *J Eur Acad Dermatol Venereol* 2006;20:625-6.
5. Kanwar AJ, De D. Lichen planus in childhood: report of 100 cases. *Clin Exp Dermatol* 2010;35:257-62.
6. Handa S, Sahoo B. Childhood lichen planus: a study of 87 cases. *Int J Dermatol* 2002;41:423-7.
7. Kanwar AJ, Handa S, Ghosh S, Kaur S. Lichen planus in childhood: a report of 17 patients. *Pediatr Dermatol* 1991;8:288-91.
8. Nanda A, Al-Ajmi HS, Al-Sabah H, Al-Hasawi F, Alsaleh QA. Childhood lichen planus: a report of 23 cases. *Pediatr Dermatol* 2001;18:1-4.
9. Sharma R, Maheshwari V. Childhood lichen planus: a report of fifty cases. *Pediatr Dermatol* 1999;16:345-8.
10. Samman PD. Lichen planus: an analysis of 200 cases. *Trans St Johns Hosp Dermatol Soc* 1961;46: 36-8.
11. Kanwar AJ, Belhaj MS. Lichen planus among Arabs: a study from Libya. *J Dermatol* 1984;11:93-6.
12. Dostrovsky A, Sagher F. Lichen planus in subtropical countries: study of an annular type with inverse localization (uncovered surfaces of the skin). *Arch Dermatol Syphilol* 1949;59:308-28.
13. Kumar V, Garg BR, Baruah MC, Vasireddi SS. Childhood lichen planus (LP). *J Dermatol* 1993;20:175-7.
14. Singh OP, Kanwar AJ. Lichen planus in India: an appraisal of 441 cases. *Int J Dermatol* 1976;15:752-6.
15. Rybojad M, Moraillon I, Laglenne S, et al. Lichen planus in children: 12 cases. *Ann Dermatol Venereol* 1998;125:679-81.
16. Sun A, Chiang CP, Chiou PS, et al. Immunomodulation by levamisole in patients with recurrent aphthous ulcers or oral lichen planus. *J Oral Pathol Med* 1994;23:172-7.
17. Lin AN. Innovative use of topical calcineurin inhibitors. *Dermatol Clin* 2010;28:535-45.
18. Basak PY, Basak K. Generalized lichen planus in childhood: is dapsone an effective treatment modality? *Turk J Pediatr* 2002;44:346-8.
19. Cribier B, Frances C, Chosidow O. Treatment of lichen planus: an evidence-based medicine analysis of efficacy. *Arch Dermatol* 1998;134:1521-30.
20. Hodgson TA, Sahni N, Kaliakatsou F, Buchanan JA, Porter SR. Long-term efficacy and safety of topical tacrolimus in the management of ulcerative/erosive oral lichen planus. *Eur J Dermatol* 2003;13:466-70.
21. Verma KK, Mittal R, Manchanda Y. Azathioprine for the treatment of severe erosive oral and generalized lichen planus. *Acta Derm Venereol* 2001;81:378-9.
22. Frieling U, Bonsmann G, Schwarz T, Luger TA, Beissert S.

Treatment of severe lichen planus with mycophenolate mofetil. *J Am Acad Dermatol* 2003;49:1063-6.

23. Nylander LE, Wahlin YB, Hofer PA. Methotrexate supplemented with steroid ointments for the treatment of severe erosive lichen ruber. *Acta Derm Venereol* 2002;82:63-4.

24. Kerscher M, Volkenandt M, Lehmann P, Plewig G, Rocken M. PUVA-bath photochemotherapy of lichen planus. *Arch Dermatol* 1995;131:1210-1.

25. Ferahbas A, Uksal U, Kutlugun C, Kontas O. Low-molecular-weight heparin (enoxaparin) in the treatment of lichen planus. *J Eur Acad Dermatol Venerol* 2003;17:604-5.

26. Gollner GP, Muller G, Alt R, Knop J, Enk AH. Therapeutic application of T cell receptor mimic peptides or cDNA in the treatment of T cell-mediated skin diseases. *Gene Ther* 2000;7:1000-4.

27. Kaposi M. Lichen ruber pemphigoides. *Arch Dermatol Syphilol* 1892;24:343-6.

28. Cohen DM, Ben-Amitai D, Feinmesser M, Zvulunov A. Childhood lichen planus pemphigoides: a case report and review of the literature. *Pediatr Dermatol* 2009;26:569-74.

29. Camisa C, Neff JC, Rossana C, Barrett JL. Bullous lichen planus: diagnosis by indirect immunofluorescence and treatment with dapsone. *J Am Acad Dermatol* 1986;14:464-9.

30. Handa S, Kanwar AJ. Bullous lichen planus. *Pediatr Dermatol* 1993;10:393-4.

31. Kwee DJ, Dufresne RG, Ellis DL. Childhood bullous lichen planus. *Pediatr Dermatol* 1987;4:325-7.

32. Ellis FA. Histopathology of lichen planus based on analysis of one hundred biopsies. *J Invest Dermatol* 1967;48:143-8.

## Abbreviations

LP - Lichen planus

LPP - *Lichen planus pemphigoides*

HCV - Hepatitis C virus

HBV - Hepatitis B virus

BLP - Bullous lichen planus

DIF - Direct immunofluorescence test

UVB - Ultraviolet B phototherapy

BMZ - Basement membrane zone

IIF - Indirect immunofluorescence

## Acknowledgement

This study was partly supported by the Ministry of Science of the Republic of Serbia, grant N°175065 and grant N° 175038.

# Bulozni lichen planus u dečijem uzrastu

## Sažetak

Uvod: U Evropi, samo 1% obolelih od lichen planusa su deca. Bulozna forma se viđa kod 1-16% obolele dece. Prikaz obolelog: Prikazujemo dečaka uzrasta 5 godina obolelog od lichen planusa, kod koga je na papulama došlo do razvoja bula. U prethodnih 12 meseci nije bio vakcinisan protiv hepatitisa B. Rutinske laboratorijske analize bile su normalne. Hepatitis B površinski (eng. *surface*) antigen i antitela protiv Hepatitisa C virusa su bili negativni. Papule su bile diseminovane na trupu i ekstremitetima, sa tendencijom da se slivaju u plakove. Na šakama i stopalima su postojale vezikule i bule na papulama i malim plakovima.

Histopatološka analiza: Histopatologija je potvrdila dijagnozu buloznog lichen planusa. Negativni test direktne

imunofluorescencije je isključio lichen planus pemphigoides. Lečenje: Dečak je lečen prednizonom u dozi 1 mg/kg (doza je postepeno snižavana do isključenja nakon 1,5 mesec), UVB fototerapijom, lokalno fluocinolon acetomidom i pimekrolimus 1% kremom do potpune remisije posle 2,5 meseca. Dva meseca po završetku terapije nije bilo znakova relapsa.

Zaključak: U našem slučaju primena opšte kortikosteroidne terapije i UVB fototerapije pokazale su se uspešnim i bezbednim. Ovo je jedini slučaj buloznog lichen planusa, u dečjem uzrastu koji je lečen u našoj klinici za proteklih 20 godina. Dugoročna prognoza lichen planusa, u dečjem uzrastu nije poznata. Ne postoji konsenzus o terapiji lichen planusa, u dečjem uzrastu.

## Ključne reči

Predškolsko dete; Vezikulobulozne bolesti kože; Lichen planus; Prednizon; Fototerapija



# One Hundred Years of Dermatovenereology in the Serbian Army

Miroslav Ž. DINIĆ\*, Lidija KANDOLF-SEKULOVIĆ, Radoš D. ZEČEVIĆ

Department of Dermatology and Venereology, Military Medical Academy, Belgrade, Serbia

\*Correspondence: Miroslav Ž. DINIĆ, E-mail: miroslavdinic@hotmail.com

616.5+616.97]:355.721(497.11)(091)

## Abstract

One hundred years of dermatovenereology of the Serbian Army was celebrated on November 7, 2009, in the amphitheatre of the *Military Medical Academy* (MMA). The oldest document in possession of the *Serbian Armed Forces Medical Services* is dated on St. George's Day, May 6<sup>th</sup>, 1869 and represents a "Daily report of military hospitals". This document clearly shows the number of patients, and what they suffered from. Moreover, this document shows, among other things, how many patients were suffering from "venereal diseases, red wind, mechanical injuries, base wounds, ulcers, lichen and mange". Until 1909, the *Department of Dermatovenereology* did not exist as an independent. Today, the Clinic has 2 divisions (a total of 36 beds), as well as the *Laboratory for immunodermatology, Surgical unit, General Dermatology Outpatient Clinic, Allergology Section, Phototherapy Section, Dermoscopy and Melanoma Outpatient Clinic*. The Clinic is the leader in the treatment of psoriasis, autoimmune skin diseases (pemphigus, pemphigoid), severe forms of atopic dermatitis, erythroderma, skin lymphomas and cutaneous manifestations of connective tissue diseases (lupus, dermatomyositis, sclerodermia), and a dermatologic oncology section is being developed, where systemic therapy of melanoma and follow-up of these patients will be done. Regarding the vision of the future, the main task of the Clinic is to ensure continuous improvement in the field of dermatology in Serbia. The plan is to develop the area of photodiagnostics and phototherapy, which are insufficient in the region. Also, further development of dermatological surgery is planned. Further development of Allergology Service is mandatory, as well as establishment of Pediatric Dermatology, Phlebology and Trichology Outpatient Clinic. Continued scientific research is essential for the development of an academic institution and a prerequisite for continuous diagnostic and therapeutic progress, and a permanent pursuit.

## Key words

Dermatology + history; Venereology + history; Hospitals, Military + history; Military Personnel; History, 19th Century

One hundred years of dermatovenereology of the Serbian Army was celebrated on November 7, 2009, in the amphitheatre of the Military Medical Academy (MMA). It was an opportunity to review and remind ourselves of the history of dermatovenereology in the military health care in Serbia.

## Military medicine in Serbia in the 19th century

In 1830, Serbia was recognized by hatiserif (Sultan's Edict) and given autonomy under Turkish rule, allowing foundation of hospitals in Serbia. The first Serbian constitution, "*Sretenje Constitution*", was proclaimed in 1835, when Prince Miloš Obenović

founded the first Serbian military units. The Constitution included a paragraph: "Taking care of funds for maintenance of hospitals and soldiers' health ...". Military doctors were employed in the same year, and in 1836, the first military hospitals were founded in Kragujevac and Požarevac, while in the Belgrade district Savamala, a small military hospital unit was founded, which was soon relocated to a part of Palilula Barrack (opposite the present Belgrade Botanical Garden). *Military hospital of Palilula* had "two rooms for patients with mange (scabies)", on the ground floor, and on the first floor a "sickroom for patients with internal conditions, and a room for convalescents". These are the first data showing that

soldiers-patients with skin diseases were separated from the others, and collectively treated as “mangy”.

By the Decree of Prince Alexander Karadjordjević, signed on March 2<sup>nd</sup>, 1844, the first *Central Military Hospital* was established. This Decree represented the beginning of the new period in Serbian military medicine, and this date is still celebrated as the Day of the *Military Medical Academy*. The hospital was built in place of today's Belgrade Flower Square, and it was finished in 1848. *The Military hospital of Palilula* was relocated into the new building. The hospital gradually became a permanent military hospital, the *Danube military hospital* with 150 beds

and two departments: *Department of internal diseases*, and *Department of external diseases*, i.e. skin diseases.

The oldest document in possession of the *Serbian Armed Forces Medical Services* is dated on St. George's Day, May 6<sup>th</sup>, 1869 and represents a “Daily report of military hospitals”. This document clearly shows the number of patients, their gender and rank, if they were in the internal or external department, and what they suffered from. Patients with skin diseases were placed in the Department for external diseases, and this document shows, among other things, how many patients were suffering from “venereal diseases, red wind, mechanical injuries, base wounds, ulcers, lichen and mange” (Figure 1).

The document is a handwritten report on a grid. The title is "ДНЕВНИЙ РАПОРТЪ ВОЕНЕ БОЛНИЦЕ" (Daily Report of Military Hospitals) with the date "6 Мая 1869 года". Below the title, it says "КОЛИКО БОЛЕЗНЕВНА" (Number of Diseases) and lists categories: "У БОЛНИЦЕ" (In Hospital), "ИЗШЛО ИЗЪ БОЛНИЦЕ" (Discharged from Hospital), "ЗА ОСТАЛО У БОЛНИЦЕ" (Remained in Hospital), "КОГЪ РОДА ВОЙСКЕ" (By Regiment), and "КОГЪ ЧИНА" (By Rank). The grid contains handwritten numbers and names of regiments and ranks. At the bottom, there is a section "Примѣба:" (Note) with further handwritten text.

**Figure 1.** The oldest document in possession of the Serbian Armed Forces Medical Archives: “Daily report of the military hospital”

## Formation of the organized Dermatovenereology Service in the Serbian Army

The *Danube military hospital* facilities eventually became insufficient for the admission of the Danube Division soldiers and troops from other garrisons from Serbia, and a decision was made at the suggestion of the Chief of the Medical Corps, Colonel Dr. Mihajlo Marković, to build a new and bigger hospital in the Belgrade district, Western "Vračar". At that point, on November 1<sup>st</sup>, 1909, the *General Military Hospital* started working (Figure 2). The hospital had 400 beds and several departments: Department of Internal Diseases, where mental patients and patients with infectious diseases were treated, Surgery Department, Eye and Dermatovenereology Departments. The hospital also had a radiographic laboratory and a dental service.

Therefore, until 1909, the *Department of Dermatovenereology* did not exist as an independent Department, but dermatovenereological diseases were treated in the *Danube Military Hospital* at the Department of External Diseases by skin and venereal diseases specialists: 1st class captain Dr. Milutin Pop Jovanović, who was the first Chief of the *Department*



**Figure 2.** The main building of the General Military Hospital, established in 1909 at Western Vračar, Belgrade district

of *Dermatology* of the *General Military Hospital*. Due to his illness in 1911, he was replaced by a 2<sup>nd</sup> class captain Dr. Toma Leko.

During the Balkan Wars and the First World War, the Department was conducted by a reserve lieutenant colonel Dr. Milan Radovanović, who was also the Head of the *General Military Hospital*. Immediately after the First World War, the Department was directed by Major Dr. Božidar Janković, and in 1921, Major Dr. Milivoje Pantić was appointed the Head of the Department, and he kept this position until the beginning of the World War II, when he became a brigadier general. Initially, the Department had 40 beds, and since 1929, 96 beds. Only military personnel were treated at the Department.

During the Second World War, the Department did not work as such, and mostly returnees from nazi camps in Germany were hospitalized. At the end of 1944, *Dermatovenereology Section* of the *Main Military Hospital of the Yugoslav Army* was reopened, headed by Col. Dr. Jezdimir Jovanović. At the beginning of 1946, Major Dr. Miladin Gilić was appointed the Head of the Department. In 1949, the *Main Military Hospital* changed its name to *Military Medical Academy* (MMA), and in 1960 the Section became the *Clinic of dermatology and venereology* of the MMA, where Dr. Miladin Gilić, Head of the Clinic and associate professor, stayed until his retirement in 1963. At that time the Clinic had 60 beds. With a modest inventory, an *Outpatient Allergology Clinic* was established in 1955, and it was directed by Colonel Branislav Hrnjiček. Since 1960, a histopathological laboratory was established and directed by Col. Dr. Slavko Arnerić. Since 1963, the Head of the Clinic was Colonel and Associate Professor Dr. Radovan Krunic. Col. Ass. Prof. Dr Slavko Arnerić was appointed the Head of the Clinic in 1970, and he remained at this position until 1984, when Colonel Professor Dragomir Janković became the Head of the Clinic.

After the formation of MMA, the Clinic included the *Department of Skin Diseases*, *Department of Venereal Diseases*, *Outpatient Ambulance*, *Section for Physical Therapy* and a *Laboratory of Biochemistry*. Since 1972, the Clinic established a *Laboratory of Immunodermatology* (or *Laboratory of Immunopathology*), in which direct and indirect immunofluorescence examinations of the skin



specimens and sera were examined. The Laboratory was commissioned by Colonel Professor Zvonimir Stefanović. There was also a *Therapeutic Dermatology Section* where phototherapy, skin electrosurgery and cryotherapy were performed. Professor Dragomir Janković, Head of the *Therapeutic Dermatology Section* replaced Col. Professor Zvonimir Stefanović in 1992, and since 1994, Col. Professor Đordije Karadaglić became the Head of the Department. In 2000, a capital textbook of dermatovenereology in Serbian language was published, entitled "Dermatology", whose editor was Professor Karadaglić. The textbook was in two volumes, with participation of nearly 50 Serbian and foreign dermatovenereologists and doctors of other specialties, as authors and coauthors. Since 2002, the Head of the Clinic is Colonel Professor Radoš D. Zečević.

### Clinic of Dermatology and Venereology of MMA today

Today, Clinic has 2 divisions (a total of 36 beds), a *Laboratory for immunodermatology*, *Surgical unit*, *General Dermatology Outpatient Clinic*, *Allergology Section*, *Phototherapy Section*, *Dermoscopy and Melanoma Outpatient Clinic*. The Clinic is the leader in the treatment of psoriasis, autoimmune skin diseases (pemphigus, pemphigoid), severe forms of atopic dermatitis, erythroderma, skin lymphomas and cutaneous manifestations of connective tissue diseases (lupus, dermatomyositis, scleroderma), and a dermatologic oncology section is being developed,

where systemic therapy of melanoma and follow-up of these patients will be done.

Annually, about 800 patients are supervised at the Clinic, of which 50% the citizenry. The most common clinical conditions include: psoriasis (11%), hives (10%), melanoma (7.68%), contact dermatitis (7.68%), lupus erythematosus (5.2%), pemphigus/pemphigoid (5.2%) and cutaneous lymphomas (2.6%). The Clinic has a Theatre for dermatosurgery, where biopsies of skin and subcutaneous tissues are performed for diagnostic purposes as well as surgical removal of benign and malignant skin changes, electrosurgery with radiofrequency devices and cryosurgery (liquid nitrogen). On an annual basis, there are about 550 different interventions. The *Laboratory for immunodermatology*, unique in Serbia, uses methods of direct and indirect immunofluorescence, for immunoserological and immunohistological diagnosis (anti-nuclear, anti-mitochondrial, anti-smooth muscle and antiparietal antibodies, antibodies to the basement membrane zone, autoantibodies and pemphigus autoantibodies etc.) – and performs over 1000 analyses per year. In the Outpatient Clinic and its sections, where outpatient examinations are performed, skin ultrasound examinations, Wood's light examinations, dermoscopy, allergy tests with standard and non-standard batteries of allergens, photodynamic therapy and the last generation of radiofrequency and diode laser treatment of leg veins and skin rejuvenation (diode laser) are available,



**Figure 3.** Department of Dermatology of the General Military hospital, Western Vračar, Belgrade district

as well as the the latest generation of photoherapy equipment with narrow band UVB and UVA devices. In the Outpatient Clinic, more than 30.000 patients are examined annually. At the Clinic of Dermatology and Venereology, residency in dermatovenerology is available for military personnel, as well as for civilians, but also specialist trainings for other health centers in immunodermatology.

Ongoing scientific research is done in cooperation with the *Institute for Medical Research of MMA* and *Institute of Pathology and Forensic Medicine* of MMA. Several scientific publications, in the field of connective tissue diseases, cutaneous lymphoma and photodermatology, the present project study of genetic alterations in skin cancers and melanoma, as well as the research project on the subclinical atherosclerosis and metabolic syndrome in patients with psoriasis are under way. So far, the current personnel of the Clinic has published 51 articles in scientific periodicals, out of which nearly two thirds were published in foreign journals.

Every other November, the Clinic is the organizer and the host of the *Belgrade Dermatological Days*, the most important national dermatology meeting, which brings together more than 300 dermatovenerologists from our country and abroad, and once a year it is the organizer and the host of the Meeting of the Dermatovenerology Section of the *Serbian Medical Society*.

### **Clinic of Dermatology and Venereology of MMA – the vision of the future**

Regarding the vision of the future, the main task of the Clinic is to ensure continuous improvement in the field of dermatology in Serbia.

The plan is to develop the area of photodiagnosics and phototherapy, which are insufficient in the region. Also, further development of dermatological surgery is planned, since it is the integral part of dermatology in the USA, and most of the European countries. This will allow more comprehensive monitoring of patients with skin tumors in the diagnosis and treatment.

Development of esthetic dermatology, for which there is a great need in recent years, would offer cosmetic dermatological services, and provide continuous funding of all segments of dermatological services. Further development of Allergology Service is mandatory, as well as establishment of Pediatric Dermatology, Phlebology and Trichology Outpatient Clinic. Continued scientific research is essential for the development of an academic institution and a prerequisite for continuous diagnostic and therapeutic progress, and a permanent pursuit.

Current development of dermatology requires revision of previous plans of specializations, and better training in internal medicine and surgery, which will be tasks in education of new generations of dermatologists.

### **References**

1. Ignjatović M. Formiranje vojne sanitetske službe u Srbiji sredinom XIX veka [Establishment of the military healthcare service in Serbia in the middle of the XIX century]. *Vojnosanit Pregl* 2003;60(4): 509-15.
2. Dnevni raport vojne bolnice od 06. maja 1869. godine [Daily report of the military hospital, May 6<sup>th</sup>, 1869]. Beograd: Vojnosanitetski arhiv Vojske Srbije; 1869.
3. Pantelić D, urednik. Vojnomedicinska akademija JNA: Jubilarna monografija. [Military Medical Academy of the Yugoslav National Army - YNA: An anniversary monograph]. Beograd: Vojnomedicinska akademija; 1985.

## **Sto godina detmatologije u srpskoj vojsci**

### **Sažetak**

Jubilarna godišnjica: U novembru 2009. godine u Vojnomedicinskoj akademiji je obeleženo 100 godina dermatovenerologije u Vojski Srbije. To je bila prilika da se osvrnemo na istorijat dermatovenerologije, pored sagledavanja aktuelnog trenutka i ideja za budućnost. Dan osnivanja: Prvi vojni lekari se raspoređuju u vojnim bolnicama 1835. godine. Odlukom knjaza

Aleksandra Karađorđevića od 02. marta 1844. godine planirano je osnivanje „Vojnog špitalja centralne vojske“, a taj dan se slavi kao dan osnivanja Vojnomedicinske akademije. Na osnovu najstarijeg dokumenta Vojnosanitetskog arhiva „Dnevni raport vojne bolnice“, datiranog na Đurđevdan 1869. godine, bolesnici sa obolelom kožom su smeštani u spoljašnje

odeljenje bolnice, a zabeleženo je i koliko obolelih je bilo od „venerija, crvenog vetra, rana mehaničkih, rana prostih, čireva, uboja, lišja i šuge“.

Kožno-venerično odeljenje: U okviru Opšte vojne bolnice od 1909. godine postoji i samostalno Kožno-venerično odeljenje, čiji je prvi načelnik bio kapetan I klase dr Milutin Pop Jovanović. Odeljenje je radilo i tokom Balkanskih ratova i Prvog svetskog rata, a posle Drugog svetskog rata ponovo se otvara Kožno-venerično odeljenje Glavne vojne bolnice Jugoslovenske armije. Odeljenje prerasta u Kliniku za kožne i polne bolesti VMA 1960. godine.

Kliniku za kožne i polne bolesti: Od 1972. godine u sastavu Klinike je i Laboratorija za imunopatologiju. Danas, Klinika čiji je načelnik pukovnik profesor dr Radoš D. Zečević, raspolaže sa 2 odeljenja, Laboratorijom za imunodermatologiju

i salom za dermatohirurgiju, uz ambulantu za opštu dermatologiju i alergologiju, fototerapiju, dermoskopiju i ambulantu za melanome. Klinika je lider u lečenju psorijaze, autoimunih buloznih dermatoza, teških oblika atopijskog dermatitisa, eritrodermijskih stanja, kutanih limfoma i kutanih manifestacija sistemskih bolesti vezivnog tkiva, a razvija se i osek dermatološke onkologije. Klinika je osnivač i domaćin Beogradskih dermatoloških dana, najvažnijeg nacionalnog stručnog skupa.

Budući razvoj: Planovi za budućnost uključuju razvoj na polju fotodijagnostike i fototerapije, alergologije, kao i razvoj dermatohirurgije kao integralnog dela dermatologije. U planu je osnivanje ambulanti za pedijatrijsku dermatologiju, flebologiju i trihologiju. Kontinuirani naučno-istraživački rad ostaje kao trajni zadatak.

## Ključne reči

Dermatologija + istorija; Venerologija + istorija; Bolnice, vojna + istorija; Vojno osoblje; Istorija, 19. veka



## Activities of the Dermatovenereology Section of the Serbian Medical Society in 2010

The first accredited course of Continuing Medical Education (CME), in the scope of *Dermatovenereology Section (DVS)* of the *Serbian Medical Society (SMS)*, was held on March 2, 2010, in Sava Center in Belgrade. It was organized by the *Institute of Dermatovenereology (IDV)* of the *Clinical Center of Serbia (CCS)* under the theme Genodermatoses – Current concepts.

### Lectures:

- Molecular Basis of Genodermatoses - Prof. Dr. Ljiljana Luković
- Epidermolysis bullosa hereditaria - What do we Know Today? - Prof. Dr. Ljiljana Medenica
- Sclerosis tuberosa - Clinical Symptoms and Diagnostic Criteria - Prof. Dr. Sonja Vesić
- Neurofibromatosis - Clinical Types and Diagnostic Criteria – Assist. Prof. Dr. Jelica Vukićević
- Netherton Syndrome – What's New? - Assist. Prof. Dr. Zorana Đjaković
- Incontinentia pigmenti - Ass. Dr. Snežana Minić
- Keratoderma palmo-plantaris hereditaria - Ass. Dr. Mirjana Milinković
- Gorlin-Goltz Syndrome - Ass. Dr. Dušan Škiljević
- Darier's Disease - Clinico-Epidemiological Aspects - Ass. Dr. Dubravka Živanović
- Ichthyosis – a Group of Diseases - Ass. Dr. Svetlana Popadić

*Dermatovenereology Section (DVS)* of the *Serbian Medical Society (SMS)* organized a course at the *Clinic of Dermatovenereology Diseases of the Military Medical Academy (MMA)* in Belgrade on April 9, 2010, accredited by the *Health Council of the Republic of Serbia*.

The introductory lecture was delivered by Dr. Željko Mijušković: "Determination of the Genetic Polymorphism in GST Genes and IL-10, and

PCTH Gene Mutation in Patients with Vasocellular Carcinoma."

Panel: Cyclosporine in the Treatment of Psoriasis, Atopic Eczema and Chronic Urticaria (Radoš D. Zečević, Lidija Kandolf Sekulović, Željko P. Mijušković).

### Case Reports:

- Pyoderma Gangrenosum – Dr. Miroslav Dinić
- Wegener's Granulomatosis – Dr. Miroslav Dinić
- Sarcoidosis Cutis – Dr. Miroslav Dinić
- Slowly Progressive Systemic Mastocytosis - Assist. Prof. Dr. Lidija Kandolf Sekulović
- Acute Generalized Exanthematous Pustulosis due to Diltiazem - Assist. Prof. Dr. Lidija Kandolf Sekulović
- Erythrokeratoderma Variabilis – Dr. Adrijana Kiš
- Paget's Disease – Dr. Tatjana Radević
- Eruptive Xanthoma – Dr. Dušan Šofranac
- Morphea Profunda and Cutaneous B-Cell Lymphoma - Prim. Dr. Zorica Perić Hajzler
- Juvenile Bullous Pemphigoid – Dr. Kristina Kostić
- Granulocytic Sarcoma – Dr. Kristina Kostić

Spring meeting of the DVS of the SMS was organized by the *Clinic of Dermatovenereology Diseases, Clinical Center of Niš* and the *Dermatovenereology Section of the Serbian Medical Society's Branch of Niš* in Prolog Banja from May 7-9, 2010. It was accredited by the Health Council of the Republic of Serbia as a I Category Course with the topic: "Cutaneous Lymphomas."

### Lectures:

- Epidemiology and Classification of Primary Cutaneous Lymphomas - Prof. Dr. Milenko Stanojević
- Mycosis Fungoides – Prof. Dr. Ljiljana Spalević
- Sézary Syndrome - Prof. Dr. Dragan Jovanović
- Primary Cutaneous CD30+ Lymphoproliferative Disorders – Prof. Dr. Jelica Todorović
- Extranodal NK/T-Cell Lymphoma, Nasal Type - Prof. Dr. Jelica Todorović
- Primary Cutaneous B-Cell Lymphomas - Prof. Dr. Lana Golubović-Maćukanović

- Pseudolymphomas Dr. Sci .Med Viktor Lazarević
- Diagnosis of Primary Cutaneous Lymphomas – Ass. Dr. Miodrag Vučić
- Pathohistological Characteristics of Primary Cutaneous Lymphomas - Prof. Dr. Dragan Mihailović
- Therapy of Primary Cutaneous Lymphomas – Assist. Prof. Dr. Ivica Pejčić

Educational meeting of the CME was held at the joint session of the DVS of the SMS and the DVS of the SPHV of the SMS with the topic: History of Dermatovenereology and Mycology on the Territory of Vojvodina, which was accredited by the *Health Council of the Republic of Serbia* as a meeting of the Association. It was held in Novi Sad, on October 15th, 2010, in the *Home of the Army*.

Lectures:

- Dr. Zoran Golušin, Clinic of Dermatovenereology Diseases of the CCV Novi Sad

- History of Dermatovenereology in Vojvodina
- Dr. Siniša Tasić, Clinic of Dermatovenereology Diseases of the CCV Novi Sad
- Medical Mycology, Achievements and Perspectives

Case Reports

- Turner's Syndrome Associated with Lichen Planus – Dr. Jasmina Jovanović Ljubičić
- Nodular Vasculitis – Dr. Aleksandra Petrović
- Rare Presentations of Melanoma – Dr. Tatjana Roš
- Multiple Basocellular Skin Cancer – Dr. Milana Ivkov Simić

Sonja VESIĆ

President of the Dermatovenereology Section of the  
Serbian Medical Society

Correspondence: Sonja VESIĆ  
E-mail: sonja.vesic@gmail.com

## 2010 Annual report on the work of the Dermatovenereology Section of the Society of Physicians of Vojvodina of the Serbian Medical Society

Each year, the *Dermatovenereology Section of the Society of Physicians of Vojvodina* (SPHV) of the *Serbian Medical Society* (SMS), organizes professional and scientific meetings.

This year, the first professional meeting was held in March, in Sremski Karlovci, with the theme set in the field of pediatric dermatology. Introductory lectures on "Clinical Guidelines in Pediatric Dermatology" were delivered by our colleagues Sonja Prčić and Anica Radulović from the *Institute of Child and Adolescent Health Care* in Novi Sad, after which

case reports followed. The meeting was attended by many dermatovenereologists, but also by pediatricians in primary health care.

Chronic venous insufficiency was the topic of the next scientific meeting of the *Dermaovenereology Section* of the SPHV of the SMS, which was held in May 2010. The lecturers were dermatovenereologists from the *Clinic od Dermatovenereology Diseases, Clinical Center of Vojvodina*: Prof. Dr. Verica Đuran, Assist. Prof. Dr. Milan Matić, Ass. Dr. Novak Rajić, and a surgeon from the *Clinic of Vascular and Transplantation Surgery*, Assist. Prof. Dr. Vladan Popović.

The regular scientific meeting of the *Dermatovenereology Section* of the SMS was held in October 2010, and it was organized by the *Dermatovenereology Section* of the SPHV of the SMS in Novi Sad. Two lectures were delivered: "History of Development of the Dermatovenereology Service in Vojvodina" which was delivered by Ass. Dr. Zoran Golušin, and "Medical Mycology: Achievements and Perspectives" by Prim. Dr. Siniša Tasić. Lectures were followed by case reports.



**Figure 1.** The Annual Award for Scientific Research of the Society of Physicians of Vojvodina of the Serbian Medical Society, was presented at the Annual Meeting to Prof. Dr. Marina Jovanović



Our active members, Prim. Dr. Siniša Tasić and Ass. Dr. Zoran Golušin, participated in the work of the Symposium which was held in Vrbas, on the occasion of two centuries since birth of the founder and a distinguished expert in medical mycology, Dr. David Gruby, who was born in Bačko Dobro Polje. The Symposium was organized by the *Historical Branch* of the *Academy of Medical Sciences* of the SMS and the *Municipal Assembly of Vrbas*.

Spring Symposium of the *European Academy of Dermatology and Venereology* (EADV), held in Cavtat (Croatia) in May 2010, was attended by a number of our members, and so was the 19th Congress of EADV in Gothenburg, which was held in the beginning of October and where our members were active participants.

On the first weekend of June 2010, Terme Olimia (Slovenia) was the host for dermatovenereologists from Macedonia, Montenegro and Serbia. The theme of the meeting was «Hair and Nails». Representatives from all Health Centers in Vojvodina attended this meeting: Ljilja Trklja, Vesna Ćosić, Nevenka Mijatović, Assist. Prof. Dr. Zora Gajinović, Milica Subotić, Prof. Dr. Verica Đuran, Olga Vlaov Žarkov and Zoran Nedić.

In the last few years, good cooperation with colleagues from Romania was established, and this year in September, our members: Zoran Nedić, Gabriela Čolak and Josa Lotrean also attended their National Congress in Bucharest.

Zoran Nedić, Zoran Golušin and Sneža Radanović attended a Congress in Athens, organized by the Greek Association of Dermatovenereologists.

Dr. Novak Rajić, from the *Clinic of Dermatovenereology Diseases, Clinical Center of Vojvodina*, Novi Sad, gained title of a Primarius.

The Annual Award for Scientific Research of the *Society of Physicians of Vojvodina of the Serbian Medical Society*, was presented at the Annual Meeting to Prof. Dr. Marina Jovanović, from the *Clinic of Dermatovenereology Diseases, Clinical Center of Vojvodina* (Figure 1).

Olga VLAOV ŽARKOV

Secretary of the Dermatovenereology Section of the  
Society of Physicians of Vojvodina of the Serbian  
Medical Society

Correspondence: Olga VLAOV ŽARKOV,  
E-mail: bzarkov@open.telekom.rs

**FORTHCOMING EVENTS**

## Dermatology and Venereology Events 2011

DATE	MEETINGS, CONGRESSES, SYMPOSIA	ABSTRACT SUBMISSION DEADLINE	MORE INFORMATION AT
24-29 May, 2011	22nd World Congress of Dermatology, Seoul, Korea	31 <sup>st</sup> October, 2010	www.wcd2011.org
11-15 June, 2011	30th Congress of the European Academy of Allergy and Clinical Immunology (EAACI), Istanbul, Turkey	1 <sup>st</sup> April, 2011	www.eaaci.2011.com
16-19 June, 2011	1st Congress of the Montenegrin Association of Dermatovenereologists, Bečići - Budva	30 <sup>th</sup> April, 2011	e-mail: dr.stilet@t-com.me
20-23 June, 2011	7th Congress of the European Association of Dermato-Oncology (EADO), Nantes, France	11 <sup>th</sup> March, 2011	www.eado2011.com
24-29 July, 2011	2nd Munich International Summer Academy of Practical Dermatology (ISA), Munich, Germany	No abstract submission	www.isa2011.com
1-3 September, 2011	2nd 5-Continent Congress-Lasers and Aesthetic Medicine, Cannes, France	30 <sup>th</sup> June, 2011	www.5-cc.com
31 August – 3 September, 2011	32nd Symposium of the International Society of Dermatopathology, Geneva, Switzerland	No abstract submission	www.isdpssdv2011.com
7-10 September, 2011	41st Annual ESDR Meeting (European Society for Dermatological Research), Barcelona, Spain	20 <sup>th</sup> May, 2011	www.esdr2011.org
8-10 September, 2011	26th IUSTI Europe Congress, Riga, Latvia	1 <sup>st</sup> June, 2011	www.iusti-europe2011.org
15-17 September, 2011	2nd 5-Continent-Congress for Lasers and Aesthetic Medicine, Cannes, France	31 <sup>st</sup> March, 2011	www.5-cc.com
22-24 September, 2011	32nd Annual Meeting of the International Society for Dermatologic Surgery, Heidelberg, Germany	No abstract submission	www.isdsworld.com
30 September – 1 October, 2011	7th European Masters in Aesthetic and Anti-Ageing Medicine, Paris, France	30 <sup>th</sup> May, 2011	www.euromedicom.com
20-24 October, 2011	20th Congress of the European Academy of Dermatology and Venereology, Lisbon, Portugal	20 <sup>th</sup> March, 2011	www.eadvlisbon2011.org
2-5 November, 2011	12th IUSTI World Congress, New Delhi, India	15 <sup>th</sup> June, 2011	www.iusti2011.org
1-3 December, 2011	6th International Congress of Psoriasis, London, UK	1 <sup>st</sup> August, 2011	www.psoriasisg2c.com
31 January - 4 February 2012	8th World Congress of the International Academy of Cosmetic Dermatology, (IACD), Cancun, Mexico	1 <sup>st</sup> September, 2011	www.wcocd2012.com

Prepared by: Dr. Tatjana Roš, Clinic of Dermatovenereology Diseases, Clinical Center of Vojvodina, Novi Sad, Serbia

## AUTHOR GUIDELINES

Serbian Journal of Dermatology and Venereology is a journal of the *Serbian Association of Dermatologists and Venereologists*. The journal is published in English, but abstracts will also be published in Serbian language. The journal is published quarterly, and intended to provide rapid publication of papers in the field of dermatology and venereology. Manuscripts are welcome from all countries in the following categories: editorials, original studies, review articles, professional articles, case reports, and history of medicine.

### Categories of Manuscripts

1. **Editorials** (limited to 5 pages) generally provide commentary and analyses concerning topics of current interest in the field of dermatology and venereology. Editorials are commonly written by one author, by invitation.
2. **Original studies** (limited to 12 pages) should contain innovative research, supported by randomized trials, diagnostic tests, outcome studies, cost-effectiveness analysis and surveys with high response rate.
3. **Review articles** (limited to 10 pages) should provide systemic critical assessment of literature and other data sources.
4. **Professional articles** (limited to 8 pages) should provide a link between the theory and practice, as well as detailed discussion or medical research and practice.
5. **Case reports** (limited to 6 pages) should be new, interesting and rare cases with clinical significance.
6. **History of medicine** (limited to 10 pages) articles should be concerned with all aspects of health, illness and medical treatment in the past.

The journal also publishes book reviews, congress reports, as well as reports on local and international activities, editorial board announcements, letters to the editor, novelties in medicine, questions and answers, and "In Memoriam". All submitted manuscripts will undergo review by the editor-in-chief, blind review by members of the manuscript review panel or members of the Editorial Board. Manuscripts submitted to this journal must not be under simultaneous consideration by any other publisher. Any materials submitted will NOT BE RETURNED to the author/s.

All manuscripts should be submitted to the **Editor in Chief: Prof. Dr. Marina Jovanović**, Clinic of Dermatovenereologic Diseases, Clinical Center of Vojvodina, Hajduk Veljkova 1-3, Novi Sad, Serbia, by mail to: [serbjdermatol@open.telekom.rs](mailto:serbjdermatol@open.telekom.rs).

Manuscripts for submission must be prepared according to the guidelines adopted by the International Committee of Medical Journal Editors ([www.icmje.org](http://www.icmje.org)). Please consult the latest version of the Uniform Requirements for Manuscripts Submitted to Biomedical Journals.

### 1. Manuscript Preparation Guidelines

The manuscript should be written in English, typed in double spacing throughout on A4 paper, on one side only; Use Times New Roman, font size 12, with 30 lines and 60 characters per line. Articles must be written clearly, concisely and in correct English. Accepted manuscripts in need of editing will be returned after editing to the corresponding author for approval. When preparing their manuscripts, authors should follow the instructions given in the *Categories of Manuscript*: the number of pages is limited (including tables, figures, graphs, pictures and so on to 4 (four)), and all the pages must be numbered at the bottom center of the page.

For manuscript preparation, please follow these instructions:

#### 1.1. Title page

The title page should include the following information:

- The title of the article, which should be informative, without abbreviations and as short as possible;
- A running title (limited to 30 characters);
- Authors' names and institutional affiliations;
- The name, mailing address, telephone and fax numbers, and email of the corresponding author responsible for correspondence about the manuscript. Furthermore, authors may use a footnote for acknowledgements, information and so on.

#### 1.2. Abstracts

A structured abstract in English (limited to 150 words) should follow the title page. The abstract should



*provide the context or background for the study, as well as the purpose, basic procedures, main findings and principal conclusions. Authors should avoid using abbreviations.*

*- An abstract in Serbian language, (limited to 150 words) should follow the second page. It should contain a briefing on the purpose of the study, methods, results and conclusions, and should not contain abbreviations.*

### 1.3. A list of abbreviations

*Use only standard abbreviations, because use of non-standard abbreviations can be confusing to readers. Avoid abbreviations in the title, abstract and in the conclusion. A list of abbreviations and full terms for which they stand for should be provided on a separate page. All measurements of length, height, weight, and volume should be reported in the metric units of the International System of Units – SI, available at <http://www.bipm.fr/en/si/>.*

### 1.4. Cover Letter

*Manuscripts must be accompanied by a cover letter, which should include a date of submission, statement that the manuscript has been read and approved by all the authors and that the authorship requirements have been met. It should also include the name, address, and telephone number of the corresponding author, who is responsible for communicating with other authors about revisions and final approval of the proofs. The original copy of the cover letter, signed by all authors, should be enclosed with the manuscript.*

## 2. Tables and illustrations

*Tables should capture information concisely and precisely. Including data in tables, rather than in the text, reduces the length of the article itself.*

*- Submit tables in separate files, not included in the manuscript. Tables are to be double spaced and numbered sequentially, with Arabic numbers (Table 1, Table 2, etc.), in order of text citation. Each column, including the first, must have a heading. Provide a brief title for each table. Put all explanatory matter in footnotes, including any nonstandard abbreviations used in the table.*

*- Figures should be submitted in a separate file, not included in the manuscript document. Cite figures consecutively, as they appear in the text, with Arabic numbers (Fig. 1, Fig. 2, Fig. 3, etc.). Each figure must be assigned a title, as well as a legend. Legends should appear on a separate page, not with each figure. The **Legend Page** is to be numbered in sequence after the last page of the references list. Figures should be professionally drawn, as sharp black-and-white or color photographs. If photographs of persons are used, either the subjects must not be identifiable, or their pictures must be accompanied by written permission to use them.*

## 3. References

References in the text, tables and legends should be identified by Arabic numerals in parentheses. Number references consecutively in the order in which they are first mentioned in the text. The *Vancouver System* of referencing should be used. List each author's last name and initials; full first names are not included. List all authors, but if the number exceeds six, give the first six followed by „et al.” National journals, which are not indexed in *Index Medicus*, should be abbreviated according to the style in the *List of Abbreviated Titles of Yugoslav Serial Publications* available on <http://vbsw.vbs.rs>. For further information please visit [www.ICMJE.org](http://www.ICMJE.org).

## 4. Additional information

*Accepted manuscripts are edited and returned to the corresponding author for approval. Then a final version of the manuscript will be requested in a defined period of time. Authors will be notified of acceptance or rejection by email, within approximately 4 weeks after submission.*

*- Open access: Every article published in the **Serbian Journal of Dermatology and Venereology** will immediately be accessible on [www.udvs.org](http://www.udvs.org) to everyone at no charge.*

*For further information please contact the Editorial Office (Tel: +381 21/484 35 62) or visit our web site: [www.udvs.org](http://www.udvs.org).*

CIP – Каталогизacija y publikaciji  
Народна библиотека Србије, Београд

616.5(497.11)

SERBIAN Journal of Dermatology and  
Venereology / editor-in-chief Marina  
Jovanović. - Vol. 1, no. 1 (january 2009)-  
. - Belgrade (Pasterova 2) : The Serbian  
Association of Dermatovenereologists, 2009-  
(Beograd : Zlatni presek). - 30 cm

Tromesečno  
ISSN 1821-0902 = Serbian Journal of  
Dermatology and Venereology  
COBISS.SR-ID 156525836



## Vrhunska zaštita od sunca koja dubinski jača kožu

Nova Eucerin linija proizvoda za zaštitu od sunca dubinski jača kožu i sprečava nastanak oštećenja pod uticajem sunčevih zraka. Pored visoko efikasne UVA i UVB zaštite, prirodni



likokalkon pruža i biološku zaštitu. Kao snažan antioksidans skladišti se u koži i sprečava dejstvo slobodnih radikala nastalih pod uticajem UV zračenja. Formulacija koja brzo prodire kroz kožu štiti i površinske i dubinske slojeve kože - za potpuno opuštanje na suncu.

[www.EUCERIN.com](http://www.EUCERIN.com)

# Eucerin®

NAUKA U SLUŽBI ZDRAVE KOŽE  
Samo u apotekama





Cover figure: Christ Healing Ten Lepers, Christ's Miracles, XIVth century, The monastery Visoki Dečani, Serbia, Kosovo

**Published by the  
Serbian Association of Dermatovenereologists**