

Serbian Journal of Dermatology and Venereology

ISSN 1821-0902

UDC 616.5(497.11)

Volume 4, Number 1, March 2012

REVIEW ARTICLE
BASAL CELL CARCINOMA:
A FREQUENT CHALLENGE

PROFESSIONAL STUDY
BASAL CELL CARCINOMA:
A CLINICOPATHOLOGICAL ANALYSIS

CASE REPORT
GRANULOMA FACIALE

HISTORY OF MEDICINE
QUACKERY IN THE TREATMENT
OF SYPHILIS IN SERBIA

REPORT

FORTHCOMING EVENTS



CONTENTS

Serbian Journal of Dermatology and Venereology 2012; 4 (1):1-56.

REVIEW ARTICLE

- 5 **BASAL CELL CARCINOMA: A FREQUENT CHALLENGE**

*Tatjana ROŠ, Branislava GAJIĆ, Novak RAJIĆ,
Milana IVKOV SIMIĆ, Zorica GAJINOV*

PROFESSIONAL STUDY

- 18 **BASAL CELL CARCINOMA: A RETROSPECTIVE CLINICOPATHOLOGICAL
ANALYSIS OF 100 CASES DERIVED FROM THE HISTOPATHOLOGICAL
REGISTRY OF THE INSTITUTE OF PATHOLOGY IN NIŠ**

Khair Fadel Merei AL JUNIDI, Mirjana PARAVINA, Vuka KATIĆ, Pasxalina MITSA

CASE REPORT

- 32 **GRANULOMA FACIALE- A DIFFICULT DIAGNOSIS? - A CASE REPORT**

Suzana NIKOLOVSKA, Đorđi GOCEV, Katerina DAMEVSKA

HISTORY OF MEDICINE

- 39 **QUACKERY IN THE TREATMENT OF SYPHILIS IN SERBIA**

Bosiljka M. LALEVIĆ-VASIĆ

REPORT

- 48 **A REPORT ON THE 1st CONGRESS OF THE MONTENEGRIN
ASSOCIATION OF DERMATOVENEREOLOGISTS**

Marina JOVANOVIĆ

FORTHCOMING EVENTS

- 51 **DERMATOLOGY AND VENEREOLOGY EVENTS**

Basal cell carcinoma: a frequent challenge

Tatjana ROŠ*, Branislava GAJIĆ, Novak RAJIĆ, Milana IVKOV-SIMIĆ, Zorica GAJINOV

Clinic of Dermatovenereology Diseases, Clinical Center of Vojvodina, Novi Sad, Serbia

*Correspondence: Tatjana ROŠ, E-mail: t.rosh@nscable.net

UDC 616.5-006.6

Abstract

Basal cell carcinoma is a slow-growing, malignant epidermal tumor predominantly affecting sun exposed areas in Caucasians, accounting for up to 80% of all diagnosed skin cancers, with a rising incidence. Chronic UV radiation, in association with constitutional factors, plays the main role in its etiology. Inappropriate activation of the hedgehog signaling pathway seems to be a key pathogenesis mechanism. Basal cell carcinoma metastases are extremely rare, but it is a locally invasive tumor that can cause significant destruction of the surrounding tissues, with their functional and esthetic impairment. There are four main clinical types of basal cell carcinoma, although clinical classification is of poor prognostic significance. Preselection of suspicious lesions and treatment planning include noninvasive diagnostic techniques: dermoscopy, confocal microscopy and ultrasound imaging, yet histopathology remains the "gold standard" of basal cell carcinoma diagnosis. In terms of the histological growth pattern, which is essential for the prognosis, basal cell carcinoma may be divided into circumscribed or diffuse types. Surgical excision is considered to be a first line treatment option, but there are numerous less invasive treatment modalities for low-risk basal cell carcinoma. Prevention strategies are focused on behavioral modifications, regular follow up and use of chemopreventive agents in high-risk patients.

Key words

Carcinoma, Basal Cell + diagnosis + classification + therapy + surgery; Risk Factors; Combined Modality Therapy; Neoplasm Recurrence, Local; Diagnosis; Treatment Outcome

Basal cell carcinoma (BCC) is a slow-growing, malignant epidermal tumor predominantly affecting sun exposed areas in Caucasians. Jacobs was the first to describe the lesion called »rodent ulcer« in 1827, and in 1900 Krompecher first identified it as an epithelial carcinoma, after histopathological examination (1, 2).

Epidemiology and risk factors

Basal cell carcinoma is the most frequent skin malignancy, accounting for up to 80% of all diagnosed skin cancers, and its incidence keeps rising. Older patients, after the 5th decade of life, are mainly affected, although endogenous and lifestyle factors may contribute to BCC appearance in younger population.

Great Britain annually registers about 30000 new cases of BCC, but it is estimated that the real incidence is even higher, because the notification system registers patients, instead of the number of lesions; also some patients are treated by non-surgical methods, without histopathological confirmation and registration. Bath Hextall et al. analyzed the period between 1996 and 2003, and reported an average annual BCC incidence growth of 3%, with a relative maximum in the population aged 30-39 years (3). In the same study, female patients were more frequently affected if younger than 50 years of age, while males were predominant if older than 55 years. Yet another conclusion was that the younger the patient, the more aggressive BCC appeared, as well as a higher relative risk of developing another BCC (3). The

There are four main clinical types of BCC, but clinical classification is of little or no importance for the prognosis:

1. Nodular BCC is a pinkish or flesh colored papule, translucent, often with visible telangiectasias, with pearly borders (Figure 1a) and a tendency to ulcerate and bleed (Figure 1b). Differential diagnosis includes: fibrous papule, sebaceous hyperplasia, dermal nevus, seborrheic keratosis, adnexal tumors (mostly trichoepitheliomas), amelanotic melanoma;

2. Pigmented BCC is a sub-type of nodular BCC which exhibits bluish to brownish color (Figure 2), resembles a melanoma, pigmented seborrheic keratosis, angiokeratoma or traumatized nevus;

3. Superficial BCC is an erythemosquamous patch (Figure 1c) which should be differentiated from eczema, psoriasis, dermatophytosis, actinic keratosis, Bowen's disease and extramammary Paget's disease. In 2010, Popadić et al. reported a patient with penile superficial BCC (10). Although such occurrence is extremely rare, it is important to know that BCC may affect areas seldom exposed to sunlight;

4. Morpheiform BCC appears like a scar or circumscribed scleroderma (Figure 1d).

The prognosis of basal cell carcinoma is closely related to its size. Giant BCC is defined as a tumor larger than 5 cm in diameter, that generally has the worst prognosis (2).

A rare distinct clinical entity is a nevoid basal cell carcinoma syndrome, also known as Gorlin-Goltz syndrome, an autosomal dominant hereditary disorder caused by a mutation of tumor suppressor PTCH gene. The prevalence is variable, from 1:56000 in UK, and 1:256.000 in Italian population, to 1:13 million in Korea. Main skin manifestations include multiple BCCs, benign dermal cysts and palmoplantar pits. It involves other organ systems such as jaws (odontogenic keratocysts), skeleton (rib, vertebral and skull abnormalities), ocular, auditory, cardiovascular, genitourinary, respiratory, gastrointestinal and the central nervous system. The main cause of early mortality in 5-10% of patients is medulloblastoma. Diagnostic criteria were defined by Evans et al. in 1993, and modified by Kimonis et al. in 1997 (11).

Noninvasive diagnosis of basal cell carcinoma

Naked-eye skin examination is often insufficiently sensitive, so clinical preselection of suspicious BCC lesions and treatment planning relies upon noninvasive diagnostic techniques: dermoscopy, confocal microscopy and ultrasound imaging.

Dermoscopy is widely used owing to its simplicity and affordable equipment. Hand-held dermoscopes allow optical magnification of 10x,

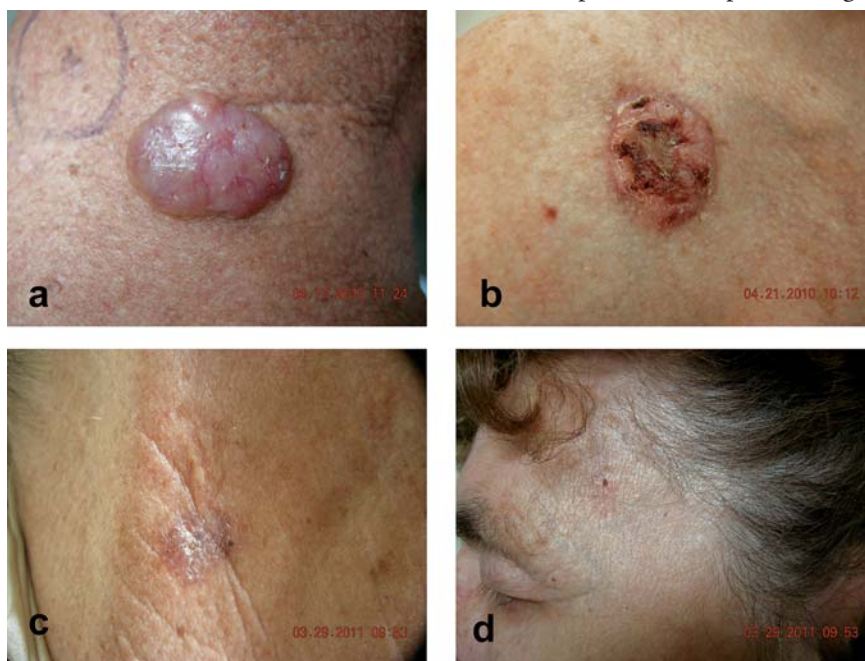

Figure 1. Main clinical types of BCC: a) nodular; b) nodular ulcerated; c) superficial; d) morpheiform

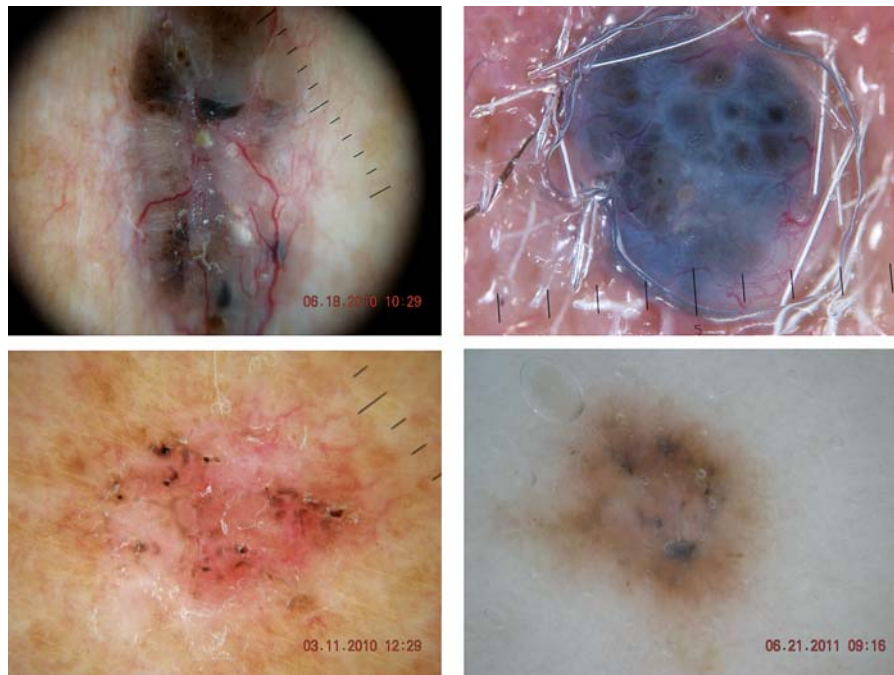


Figure 3. Dermoscopic features of pigmented BCCs

basaloid cells of the interfollicular epidermis (2). Predecessor stem cells are passing through the differentiation process along the follicular lines, so BCCs differentiate toward benign or malignant hair follicle tumors, sebaceous gland tumors, or apocrine gland tumors (19).

There is no unique and generally accepted classification of BCC, but most authors use two basic classification criteria for BCC: histological growth pattern, and histological differentiation (20).

In 2006, WHO published a classification of skin tumors which recognizes 8 histological types of BCC: superficial, nodular, micronodular, infiltrating, fibroepithelial, basosquamous, keratotic and basal cell carcinoma with adnexal differentiation (21).

According to the existing histological growth pattern, which is essential for prognosis, BCCs may be divided into circumscribed (low-risk) or diffuse (high-risk) types. High-risk types have greater probability of subclinical spread, aggressive local behavior, more frequent incomplete excision and local recurrence. Nodular BCC is a circumscribed undifferentiated tumor, while diffuse undifferentiated BCCs are superficial, infiltrative and micronodular (1, 20). Differentiated BCCs show a variety of specific cell lineage differentiation features that do not impact clinical behavior and prognosis (2).

Nodular BCCs consist of large aggregates of basaloid cells without adnexal differentiation. Basaloid cells are uniform in size with large nuclei; usually desmosomes can even be detected by light microscopy. At the periphery of aggregates cells have a parallel alignment, in a picket fence arrangement called palisading. The surrounding stroma shows myxoid changes, while tissue processing creates artificial slit-like retractions between nests of tumor cells and the stroma (1).

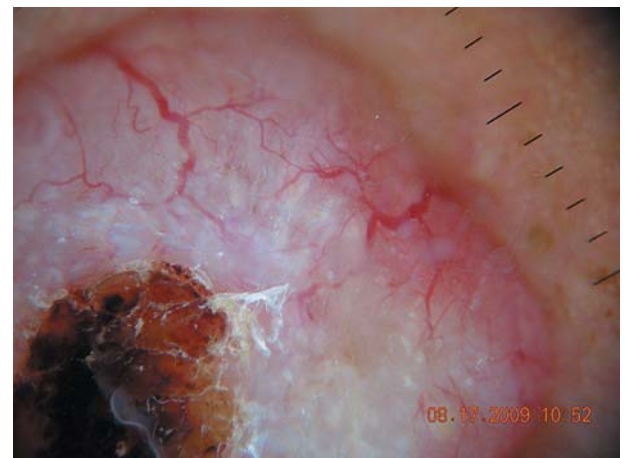


Figure 4. Dermoscopic features of nonpigmented nodular BCCs

number of tumors, and whether the tumor is primary or recurrent (1).

Treatment outcome depends on the immunological status of the patient, biological behavior of the tumor, and chosen treatment modality (25). Treatment modalities may be administered as mono therapy or combined therapy. The following treatment options are currently recognized:

Surgical excision (Figure 6) is considered to be a first line treatment option; the percentage of recurrences varies between 2-10% in different studies and depends on the histological type of the tumor (25). The recommended surgical margins for primary BCC of less than 20 mm in diameter are 3-5mm. For larger and recurrent lesions and for aggressive histological subtypes, the margins are wider – 10 mm into healthy tissue (1).

Tumor margins are marked with a skin marker prior to injection of the local anesthetic, as sometimes this makes valid detection of margins difficult (1). The sample is fixated in 10% formalin solution. In the pathology laboratory a paraffin mold is made, then sliced in vertical sections and formed into slides that are examined by a pathologist who reports the type of tumor and extension of tumor to the free margins.

Vertical sections are the standard of histology examination in surgical excision, but depending on the sectioning method used – e.g. bread loafing, they allow only representative parts of the sample to be examined, which is not more than 50% of the total depth and lateral margins of the tumor. This explains the recurrence of adequately treated BCC with the histology report of uninvolved free margins (26, 27).

In cases of incomplete excision histology reports, the analysis on the palisading pattern of tumor can help in making a decision pro or against reexcision. It was found that BCC with a histologically regular palisading pattern very rarely metastases even if incompletely excised (26).

Complications of surgical (“cold steel”) excision are: bleeding, infection, suture reaction, hypersensitivity, contact dermatitis, dehiscence, necrosis, surface contour irregularity, nerve injury, milia, telangiectasias, hypergranulation, pruritus, ectropion, eclabium, chondritis, scarring. Serious postoperative complications arising from dermatologic surgery are generally uncommon. Surgical complications are anticipated and addressed as soon as surgical treatment is determined to be necessary, usually during the preoperative consultation (28).

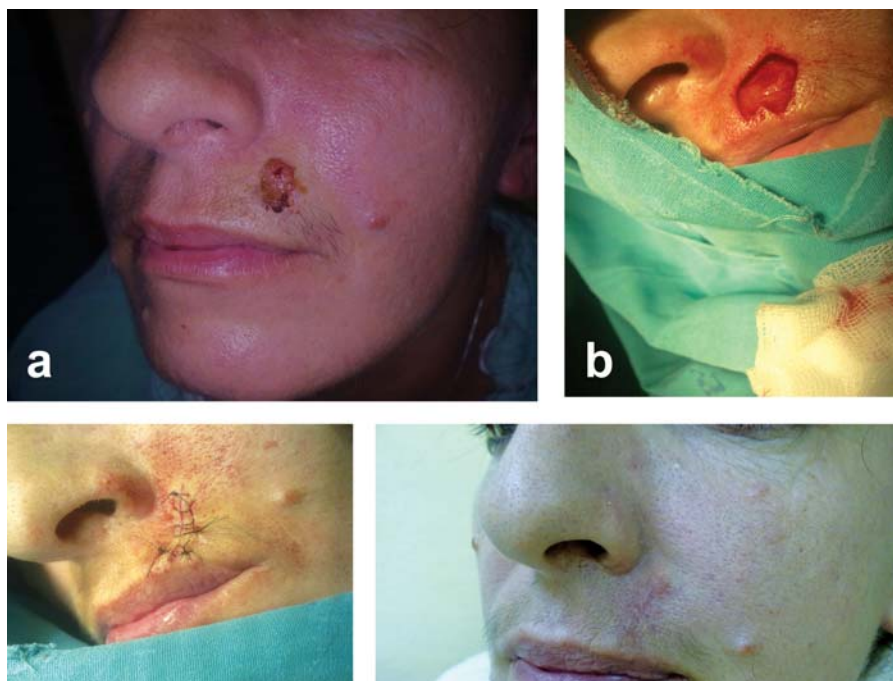


Figure 6. A patient with nodular BCC a) before; b) during; and c) after surgical excision using M-plasty technique; d) one week following suture removal

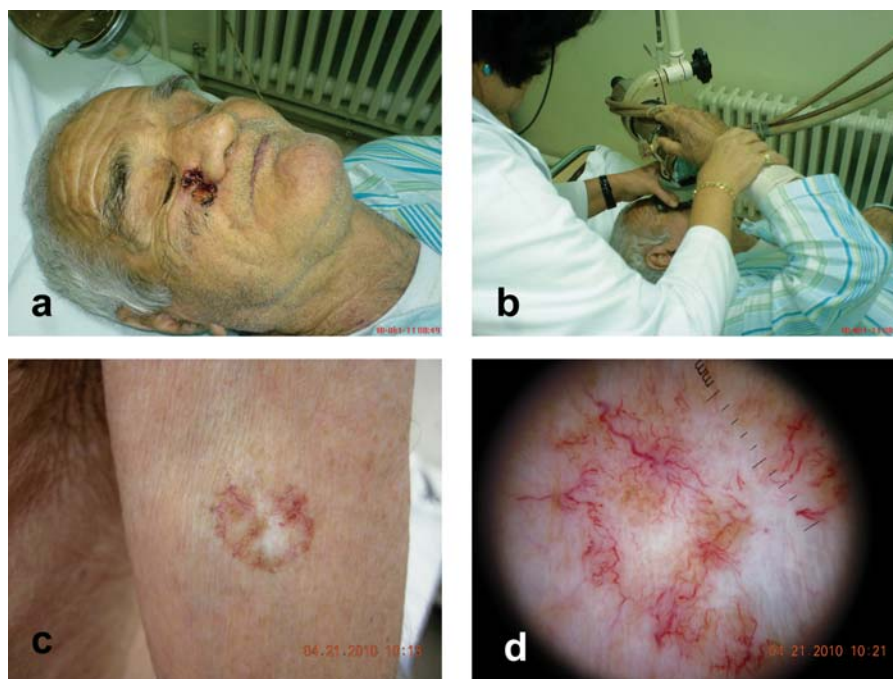

Figure 7. Superficial X-ray therapy tube application (a,b). Postirradiation scarring, atrophy and telangiectasias – c) clinical; and d) dermoscopic view

PDT demonstrated excellent cosmetic results and is useful in the treatment of multiple lesions. So far, results demonstrated safety in the treatment of superficial BCC, but some studies reported success of ALA-PDT in treating nodular BCCs with a mandatory prior curettage. PDT is contraindicated in patients with porphyria and patients with photosensitivity to wave lengths of applied light sources (26, 27, 34).

Pharmacological treatment refers to topical application of 5% imiquimod cream during several weeks (six to twelve). This immune response modifier is currently officially accepted in the treatment of superficial BCCs, with recommended dose regimen: once a day (in the evening) during five successive days of the week, within a six week period. Imiquimod cream may be combined with other treatment options (in order to decrease the tumor size, and thereby decrease postoperative deficits). Topical 5% imiquimod application causes tissue inflammatory reactions, such as: erythema, erosions, crusts, sometimes accompanied itching or burning sensations (26, 35).

Most severe cases of non-treated or inadequately treated aggressive BCCs at risky locations may lead to invasion of orbital region, ethmoid or frontal sinus, and finally to lethal outcome. Treatment of such cases

includes systemic chemotherapy, as a palliative method or preoperative multidisciplinary approach. The most effective chemotherapeutic agent appears to be cisplatin, with an average therapeutic response of about 70%, but the number of reported cases is rather small (36).

Hopes for successful treatment of advanced BCCs are invested in vismodegib (GDC-0449), a small, orally administrable molecule belonging to 2-arylpyridine class molecule, acting as a competitive antagonist of the smoothed receptor (SMO) which is a part of the hedgehog (HH) signaling pathway, pathogenetically relevant in most basal-cell carcinomas (37, 38).

Other treatments, in the phase of investigation, are topical usage of 0.005% solasodine glycoalkaloids, 0.1% tazarotene, destruction of BBC with hyperthermia produced by continual Nd:Yag laser, and intralesional bleomycin injection followed by local electric pulses to the tumor (39, 40, 41, 42).

Prevention

The primary prevention strategies for BCC, and for skin cancers in general, are focused on behavioral modifications to minimize exposure to risk factors, especially UV radiation, including sun avoidance, use

14. Argenziano G, Zalaudek I, Corona R, Sera F, Cicale L, Petrillo G, et al. Vascular structures in skin tumors: a dermoscopy study. *Arch Dermatol* 2004;140(12):1485-9.
15. Scalvenzi M, Lembo S, Francia MG, Balato A. Dermoscopic patterns of superficial basal cell carcinoma. *Int J Dermatol* 2008;47:1015-8.
16. Ulrich M, Astner S, Stockfleth E, Rowert-Huber J. Noninvasive diagnosis of non-melanoma skin cancer: focus on reflectance confocal microscopy. *Expert Rev Dermatol* 2008;3(5):557-67.
17. Desai TD, Desai AD, Horowitz DC, Kartono F, Wahl T. The use of high-frequency ultrasound in the evaluation of superficial and nodular basal cell carcinoma. *Dermatol Surg* 2007;33:1220-7.
18. Mogensen M, Jemec GBE. Diagnosis of nonmelanoma skin cancer/keratinocyte carcinoma: a review of diagnostic accuracy of nonmelanoma skin cancer diagnostic tests and technologies. *Dermatol Surg* 2007;33:1158-74.
19. Fitzpatrick JE, Whalen EA. Basal cell carcinoma or not? Histological variants and mimics of the most common cutaneous malignancy. *Semin Cutan Med Surg* 1999;18(1):15-24.
20. Vantuchova Y, Curik R. Histological types of basal cell carcinoma. *Scr Med (BRNO)* 2006;79(5-6):261-70.
21. LeBoit PE, Burg G, Weedon D, Sarasin A, eds. *World Health Organisation Classification of tumors: pathology and genetics of skin tumors*. Lyon: IARC Press; 2006. p. 10-33.
22. Constantino D, Lowe L, Brown DL. Basosquamous carcinoma – an under-recognized, high risk cutaneous neoplasm: case study and review of the literature. *J Plast Reconstr Aesthet Surg* 2006;59:424-8.
23. Leibovitch I, Huilgol SC, Selva D, Richards S, Paver R. Basosquamous carcinoma treatment with Mohs micrographic surgery. *Cancer* 2005;104(1):170-5.
24. Hussain SI, Hussain AS. Baso-squamous cell carcinoma: a case report. *J Pak Med Assoc* 2004;54(1):30-2.
25. Cohen PR, Schulze KE, Nelson BR. Basal cell carcinoma with mixed histology: a possible pathogenesis for recurrent skin cancer. *Dermatol Surg* 2006;32:542-51.
26. Telfer NR, Colver GB, Morton CA. Guidelines for the management of basal cell carcinoma. *Br J Dermatol* 2008;159:35-48.
27. Ceilley RI, Del Rosso JQ. Current modalities and new advances in the treatment of basal cell carcinoma. *Int J Dermatol* 2006;45:489-98.
28. Semchyshyn NL, Sengelmann RD. Surgical complications. *Medscape.com* [homepage on the Internet]. New York: Medscape, LLC; © 1994-2012 [cited 2012 Jan 9]. Available from: <http://emedicine.medscape.com/article/1128404-overview>.
29. Steinman HK. Indications for Mohs surgery. In: Gross KG, Steinman HK, Rapini RP, eds. *Mohs surgery: fundamentals and techniques*. St Louis (Missouri): Mosby Inc; 1999. p. 4-14.
30. Goncalves JC, Martins C. Debulking of skin cancers with radio frequency before cryosurgery. *Dermatol Surg* 1997;23(4):253-6.
31. Patidar S. Excision of basal cell carcinoma with radio frequency ablation. *J Cutan Aesthet Surg* 2008;1(1):29-30.
32. Barlow RJ. Lasers and flashlamps in the treatment of skin disorders. In: Burns T, Breathnach S, Cox N, Griffiths C, eds. *Rook's textbook of dermatology*. 6th ed. Oxford: Blackwell Publishing Ltd; 2010. Chapter 78; p. 1-15.
33. Sedda AF, Rossi G, Cipriani C, Carozzo AM, Donati P. Dermatological high-dose-rate brachytherapy for the treatment of basal and squamous cell carcinoma. *Clin Exp Dermatol* 2008;33:745-9.
34. Foley P, Freeman M, Menter A, Siller G, El-Azhary RA, Gebauer K, et al. Photodynamic therapy with methyl aminolevulinic acid for primary nodular basal cell carcinoma: results of two randomized studies. *Int J Dermatol* 2009;48:1236-45.
35. Torres A, Niemeyer A, Berkes B, Marra D, Schanbacher C, Gonzales S, et al. 5% Imiquimod cream and reflectance-mode confocal microscopy as adjunct modalities to Mohs micrographic surgery for treatment of basal cell carcinoma. *Dermatol Surg* 2004; 30:1462-9.
36. Meads SB, Greenway HT. Basal cell carcinoma associated with orbital invasion: clinical features and treatment options. *Dermatol Surg* 2006;32(3):442-6.
37. Dirix L, Migden MR, Oro AE, Hauschild A, Lewis K, Mueller AB, et al. A pivotal multicenter trial evaluating efficacy and safety of the hedgehog pathway inhibitor (HPI) vismodegib in patients with advanced basal cell carcinoma (BCC). *Eur J Cancer* 2011;47(Suppl 2):2.
38. De Smaele E, Ferretti E, Gulino A. Vismodegib, a small-molecule inhibitor of the hedgehog pathway for the treatment of advanced cancers. *Curr Opin Inves Drugs* 2010;11(6):707-18.
39. Punjabi S, Cook LJ, Kersey P, Marks R, Cerio R. Solasodine glycoalkaloids: a novel topical therapy for basal cell carcinoma. A double-blind, randomized, placebo-controlled, parallel group, multicenter study. *Int J Dermatol* 2008;47:78-82.
40. Bianchi L, Orlandi A, Campione E, Angeloni C, Costanzo A, Spagnoli LG, et al. Topical treatment of basal cell carcinoma with tazarotene: a clinicopathological study on a large series of cases. *Br J Dermatol* 2004;151:148-56.
41. El-Tonsy MH, El-Domyati MM, El-Sawy AE, El-Din WH, Anbar TEA, Raouf HA. Continuous-wave Nd:Yag laser hyperthermia: a successful modality in treatment of basal cell carcinoma. *Dermatol Online J* 2004;10(2):3.
42. Rodriguez-Cuevas S, Barroso-Bravo S, Almanza-Estrada J, Cristobal-Martinez L, Gonzales-Rodriguez E. Electrochemotherapy in primary and metastatic skin tumors: phase II trial using intralesional bleomycin. *Arch Med Res* 2001;32:273-6.
43. Harris RB, Alberts DS. Strategies for skin cancer prevention. *Int J Dermatol* 2004;43:243-51.
44. Prado R, Francis SO, Mason MN, Wing G, Gamble RG, Dellavalle R. Nonmelanoma skin cancer chemoprevention. *Dermatol Surg* 2011;37(11):1566-78.
45. Otley CC, Stasko T, Tope WD, Phil M, Lebwohl M. Chemoprevention of nonmelanoma skin cancer with systemic retinoids: practical dosing and management of adverse effects. *Dermatol Surg* 2006;32:562-8.
46. Van Iersel CA, Van de Velden HVN, Kusters CDJ, Spauwen PHM, Blokk WAM, Kiemeny LALM, et al. Prognostic factors for a subsequent basal cell carcinoma: implications for follow-up. *Br J Dermatol* 2005;153:1078-80.
47. McLoone NM, Tolland J, Walsh M, Dolan OM. Follow-up of basal cell carcinomas: an audit of current practice. *J Eur Acad Dermatol Venereol* 2006;20:698-701.

U slučaju inkompletne ekscizije, od pomoći u odluci o potrebi reekscizije može biti analiza izgleda palisadnog sloja tumora – BCK čije su ćelije pravilno palisadnog rasporeda veoma retko recidiviraju, iako nisu kompletno hirurški uklonjeni.

Mohs-ova mikrografska hirurgija predstavlja kompleksnu hiruršku tehniku kojom se ostvaruje maksimalna efektivnost u odstranjivanju tumora uz minimalan gubitak zdravog tkiva. Zasniva se na mikroskopskom pregledu multiplih smrznutih horizontalnih sekcija tumora do dosezanja njegovih krajnjih margina. Ova tehnika zahteva posebno obučeni kadar, opremu i značajan utrošak vremena, što je čini veoma skupom. Najznačajnije indikacije su agresivni, rekurentni ili inkompletno ekscidirani tumori, tumori prečnika preko 20 mm, kao i tumori rizičnih lokalizacija.

Kriohirurški tretman, najčešće sa prethodnom kiretažom tumora, koristi se uglavnom kod nodularnih BCK prečnika do 2 cm, klinički dobro definisanih granica, na lokalizacijama kože iznad kosti ili hrskavice ukoliko tumor nije fiksiran za navedene strukture. Elektrodesikacija sa prethodnom kiretažom tumora najbolje rezultate daje kod BCK prečnika do 1 cm, lokalizovanih na trupu i ekstremitetima.

Novije tehnike u oblasti dermatohirurgije se odnose na primenu radiofrekventne i laserske fotothermalne ablacije.

Radiološka terapija uglavnom je rezervisana za starije pacijente čije opšte zdravstveno stanje ne dozvoljava agresivnije intervencije, velike tumore na lokalizacijama koje se hirurški teško tretiraju. U ovoj oblasti primenu su našle površinska radioterapija (pogodna za lezije do dubine od 6 mm), elektron bima terapija (ima veću dubinu penetracije u tkiva), i brahiterapija (pogodna za lezije na zakrivljenim

površinama). Kontraindikovano je ponavljati zračenje tumora koji su recidivirali nakon radioterapije.

Topikalna fotodinamska terapija i aplikacija 5% imiquimod krema pokazale su odličan kozmetički ishod, pogodne su za tretman multiplih superficijalnih BCK lezija.

U tretmanu najtežih slučajeva BCK, sa invazijom orbite ili sinusa, dolazi u obzir sistemska hemioterapija gde se najefikasnijim pokazao cisplatin.

Tretmani u fazi istraživanja su peroralna primena vismodegiba, lokalna primena 0,005% solasodin glikoalkaloida, lokalna primena 0,1% tazarotena, destrukcija BCC hipertermijom koju produkuje kontinuirani Nd:Yag laser, i tretman tumora električnim pulsevima nakon intralezionalnog ubrizgavanja bleomicina.

Prevenција: Strategije primarne prevencije odnose se na izbegavanje uticaja faktora rizika, naročito prekomerne izloženosti UV zračenju. Sekundarna prevencija označava rano otkrivanje BCK skrining pregledima. Kod pacijenata pod povećanim rizikom nastanka nemelanocitnih karcinoma kože dolazi u obzir hemoprevencija oralnim retinoidima.

Prateće obolevanje: Nakon sprovedene terapije BCK, neophodno je vršiti periodične kontrolne preglede zbog monitoringa mogućih recidiva, rane detekcije novih tumora i edukacije pacijenata. Praksa je različita, na Klinici za kožno-venerične bolesti u Novom Sadu nakon hirurške ekscizije praktikujemo kontrole na 6 meseci tokom prve godine, potom jedanput godišnje tokom ukupno 5 godina.

Zaključak: BCK ne treba potceniti jer predstavlja izazov sa kojim se često susrećemo. Neophodna je osnovna strategija bazirana na prevenciji i ranoj detekciji ovog tumora, kao i dalje istraživanje njegove biologije i efikasnih tretmana.

Ključne reči

Bazocelularni karcinom + dijagnoza + klasifikacija + terapija + hirurgija; Faktori rizika; Kombinovana terapija; Lokalni recidiv neoplazmi; Dijagnoza; Ishod lečenja

Basal cell carcinoma (BCC) is the most common malignant tumor of the skin. It is composed of cells similar to those in the basal area of the epidermis and the matrix cells of the skin appendages. Tumor cells originate from pluripotent cells of the basal layer of the epidermis, of the outer root sheath of the hair follicle, sebaceous and sweat glands (1, 2, 3). BCC is a malignant tumor of the follicular germinative cells (4). BCC is a slow growing neoplasm which shows minimal invasion to the soft tissue. Sometimes, however, BCC is characterized by aggressive growth, deep invasion, local recurrence and metastases (5, 6). Metastatic BCC is extremely rare, occurring in 0.0028% to 0.55% of all BCCs. This low rate is believed to be because the tumor cells require supporting stroma to survive (7). The histological variability originates from the pluripotentiality of immature cells of the epidermis (1).

BCC is more common in males than females: the annual incidence for males and females ranges from 175 to 849 and 124 to 605 per 100000 people, respectively (8,9,10). In Australia, it is three times more common than any other skin cancer (11). The comparison of age-specific incidence rates of BCCs in two studies from Sweden and Australia indicate that its rate in northern Europe is approximately three to four times lower than that estimated in Australian population [11,12,13].

Most investigations indicate that BCCs account for more than 70% of cases of NMSC (non-melanoma skin cancer). In non-immunosuppressed, fair-skinned individuals, a ratio of 4:1 between BCC and SCC (squamous cell carcinoma) incidence rates has been described as a relatively constant, but this ratio differs between countries with low and high ambient sun exposure. With increasing sun exposure, there is a disproportionate increase in SCC in relation to BCC (1).

The prevalence of skin cancer like BCC depends on the population susceptibility, skin type and exposure to ultraviolet radiation (1, 14), but also on other factors such as ionizing radiation, chemical carcinogens (arsenic found in insecticides), scars from previous diseases or burns, long-term ulcers on the lower extremities, some genodermatoses such as albinism, xeroderma pigmentosum, Rombo syndrome (basal cell carcinoma, atrophoderma vermiculata, milia, hypotrichosis, trichoepithelioma, and peripheral vasodilatation), Bazex's syndrome

(basal cell carcinoma, follicular atrophoderma, hypotrichosis, localized anhidrosis), Gorlin's syndrome (basal cell carcinoma, palmoplantar pits, odontogenic keratocysts, bifid ribs, frontal bossing, and central nervous system defects), immunodeficiency, as well as some therapeutic procedures (2, 15-19). The role of human papillomavirus (HPV) in the development of BCC in immunocompromised persons requires further research (20).

Although the exact incidence of BCC is unknown, it clearly differs in regard to geographical regions (21), type of skin, long-term sun exposure and progressive aging of the population (22). According to statistical data, the incidence of BCC in Netherlands in 1999 was 53 men and 38 women per 100000 inhabitants (23), whereas in 2004 it increased to 93 men and 82 women per 100000 inhabitants (24). In France, 70 new cases are registered annually per 100000 inhabitants (25). In Germany, in the period 1998 – 2003, the incidence for men was 112, and 118 for women per 100000 inhabitants (26). The incidence of BCC increases by 10% each year (27).

In 1986, there were 112 (59 male and 53 female) histopathological examinations for BCC at the Institute of Pathology in Niš, whereas in 1996 there were 207 (113 male and 94 female) – nearly double in 10 years time (28). In the municipality of Niš, in 1990 there were 113 (75 male and 38 female) patients with non-melanoma skin cancer, and in 2000, there were 229 (124 male and 105 female) (29). The number is probably much higher, since not all patients were registered.

We may only presume just how high the prevalence of BCC will be, knowing about the depletion of the ozone layer, which is known to absorb most of the harmful ultraviolet B and C radiation (30), while it is estimated that in 2015, in Europe, there will be 50 million people older than 80 years of age (31).

The aim of this clinicohistopathological analysis is to establish clinical and pathological characteristics of basal cell carcinomas diagnosed at the Institute of Pathology of the Clinical Center in Niš.

Material and methods

The study included 100 randomly selected patients out of the total number of out of 263 consecutive patients with histopathologically established basal cell

Table 2. Distribution of basal cell carcinomas by site

Location	Number (n=100)
Continually sun-exposed areas	87
H-zone	48
Nose	29
Periorbital region	10
Ear area	2
Forehead	3
Cheek	2
Lip	1
Chin	1
Face (not specified)	29
Neck	5
Scalp	5
Frequently sun-exposed	2
Dorsal hand surface	1
Shoulder	1
Non-sun-exposed	11
Trunk	4
Lower extremity	1
Back	6

Sun exposure was certainly professional for a great number of examinees, because many of them were employed in factories and worked on farms, but also recreational and/or both.

There were no data about exposition to X-rays and chemicals (except for pesticides and insecticides), burn scars or genodermatoses.

BCCs were most commonly found in continually sun-exposed skin areas (87%), than on the trunk (11%), and on extremities (2%) (Table 2). Head and neck are considered to be continually sun-exposed. The most common site of BCC was the face in 77 persons, mostly in the H-zone in 48 patients (Table 2).

In regions which are frequently, but not continually sun-exposed, BCC was found in 2 patients: on the dorsal hand surface in one patient, and one on the shoulder in another. In non-sun-exposed regions, BCC was found in 11 patients: 4 on the trunk, 1 on

the leg, and 6 on the back. The percentage of patients with BCCs found on continually sun-exposed regions (87%) significantly differed from the percentage of patients with BCCs on non-sun-exposed regions (11%), with high significance ($p < 0.0001$), whereas the percentage of patients in the second group (BCCs on non-sun-exposed regions) was significantly higher than in patients with BCCs in regions which are not frequently, but often sun-exposed (2%), $p < 0.05$.

Table 3. shows the site and age distribution of patients with BCC. There were only 9 patients with BCC under the age of 50 years, and all 9 (100%) had head and/or neck tumors. There were 12/16 (75%) of patients aged 50 – 60 years with BCC, also located on the head and/or neck; 28/36 (77.7%) patients aged 60 – 70 years, 27/27 (100%) aged 70 – 80 years, and 11/12 (91.66%) in the ninth decade of life.

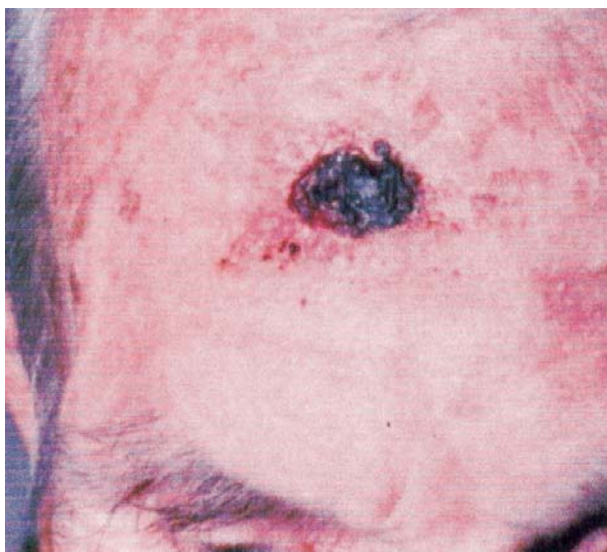

Figure 3. Basal cell carcinoma: ulcerative type

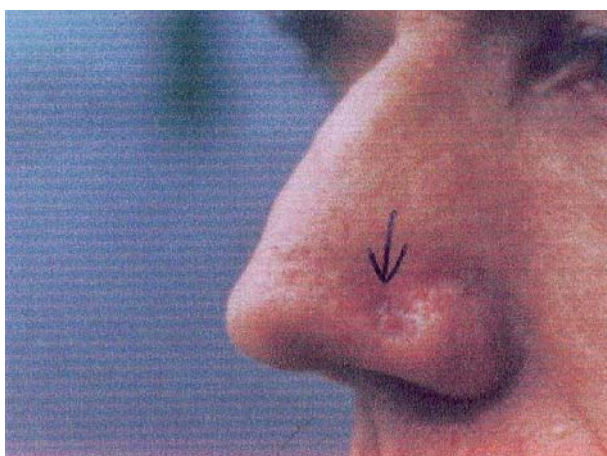


Figure 4. Basal cell carcinoma: ulcerosclerosis type

nodular versus adenoid type of BCCs was statistically significant ($p < 0.0001$), contrary to all nonspecific types together (27%) which is on the borderline of statistical significance ($p = 0.05$)

Tumor process was found on excision margins in 6% of patients (Table 4).

Discussion

This study included 58 men and 42 women selected by random sampling. The sex ratio was 1.4:1 in favour of men ($p < 0.05$), which is in accordance with literature data showing a range of 1.1-1.4 : 1 in favour of men (32, 33, 34).

The average age of examinees was 66.6 ± 12.2 years (range 23 – 90 years), with similar data found in

other studies, where the average age of patients with BCC ranged between 64.5 to 71 years (32, 33, 34, 35, 36).

The employment status was related to the age of the examined patients, but also with the altered demographic structure in the country: workers living in the country, or returned to the country after retirement (37). Taking into consideration the fact that most examinees lived in the country ($p < 0.001$), whether as retired workers, farmers or housewives, and that they were engaged in agriculture, it is easy to assume that UV radiation played a significant role in the development of the disease. According to our results, BCC was most commonly ($p < 0.0001$; 87%) located on continually sun-exposed areas (head including face and scalp, and neck), which is in agreement with literature data showing that BCC commonly affects the head and neck, with a prevalence between 85% and 56.9% (19, 36, 38). Martel (19) described BCC located on the head and neck in 85% of examinees (28% of which were on the nose), while Meneses and associates (36) found them in 74.5% of examinees. Artis and associates reported a lower prevalence (38): in their patients BCC was also most commonly found on the head and neck, but in around half of them (55.9%) on the trunk (33.9%), upper extremities (3.6%), and on lower extremities in 6.0%. According to the results of Dauden and associates (33), BCC was located on the face in 45.8% of patients, on the trunk in 29.3%, upper extremities in 19.5%, and on lower extremities in 4.7%. In our patients BCC was commonly located on the face (77%), and less

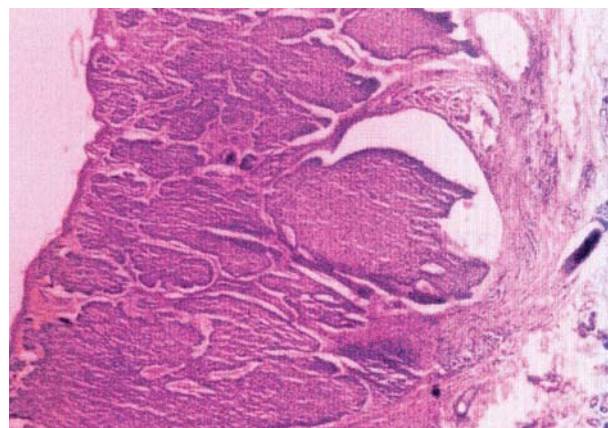


Figure 5. Basal cell carcinoma: histological presentation of the nodular (solid) type (HE staining x100)

completely process data concerning types of skin, in order to obtain adequate and conclusive statistical data.

There are four main clinical types of BCC: nodular, pigmented, superficial, and morpheaform (45). Some authors classify BCCs into 7 clinical types (46), others into 5 (47), or into 5 basic, 2 atypical, and 3 rare clinical types (48), or 10 types (49). None of the classifications coincide completely. Taking into account locations of BCCs in our patients, the most common registered clinical type was nodular (57%), with a significantly higher number of nodular BCCs without than with ulcerations ($p < 0.01$). The clinical classification itself has little or no importance for the prognosis. However, the prognosis of basal cell carcinoma is clearly related to its size (1).

There are also differences among authors when the terminology of histological types is concerned (47, 48, 50, 51, 52, 53), but most of them described the following types: nodular, adenoid, superficial, keratotic, pigmented, morpheaform, infiltrative, cystic, metatypical, fibroepithelioma, and basosquamous carcinoma. There is also a classification of differentiated and non-differentiated types. The differentiation pathway is directed towards cutaneous adnexa (keratotic, cystic, adenoid), while non-differentiated includes the nodular type (46). It is particularly valuable to classify the histologic appearance, because of the existing relationship between histologic subtype and clinical behavior: aggressive histologic variants include the micronodular, infiltrative, morpheaform; basosquamous, and mixed subtypes; nodular and superficial subtypes are characterized with a less aggressive clinical course (52). In 2006, WHO published classification of skin tumors which recognizes 8 histological types of BCC: superficial, nodular, micronodular, infiltrating, fibroepithelial, basosquamous, keratotic and basal cell carcinoma with adnexal differentiation (53). There are still differences in the terminology of histological types (1). Considering the fact that in our patients nodular type of BCC (40%) was most commonly (significantly more often than the second, adenoid type, $p < 0.0001$) diagnosed, it is in accordance with Meneses and associates who analyzed histopathological preparations in 269 patients with BCC, and found the nodular type in most cases (36). Rigell and associates (46) reported the nodular type of BCC in 60% of all histological subtypes, mostly

located on the head and neck, but it may also be found on the trunk and extremities. Meneses and associates found that the next most commonly diagnosed were multifocal, superficial, and adenoid types, whereas morpheaform, metatypical and cystic were rather rare. None of our patients presented with metatypical (basosquamous) basal cell carcinoma. Interesting results were obtained by Aguilar Bernier and associates (21) who conducted a comparative epidemiological study of the differences in the prevalence of certain histological types of BCCs between Spaniards on the one hand, and the Europeans originating from northern and central Europe on the other hand, who were settled on the sunny Riviera, Spanish Costa del Sol. In both examined groups of inhabitants the most common type of BCC was superficial (20.4% and 28.2%), then infiltrative (20.8% and 19.6%), nodular (16.7% and 9.9%), undetermined (7.0% and 10.0%), and micronodular (0.9% and 0.4%). Such a high prevalence of superficial BCCs can be a result of patients' education. In our patients, the superficial type was diagnosed only in 7%.

In Australia, although still less common than the nodular type, compared with Europe, there are proportionately more superficial basal cell carcinomas, and in females the incidence is maximum in the 40–49 years age group (27). According to Raasch and associates, the superficial type of BCC accounts for 25%–26% of all BCCs in sun-exposed Australians, and for 15%–16% of all types in Europe: the most common are located on the trunk and extremities, excluding the population highly exposed to sun, who may have them on the face (27, 54).

Current therapy of BCC includes destructive and surgical procedures (55). Surgical excision is the gold standard for BCC: conventional, conducted in our patients, and Mohs micrographic surgery, which takes a significant place in the treatment of high-risk BCCs (56). When choosing therapeutic modalities, factors that increase the risk of recurrence and/or incidence of metastasis spread should be considered, such as: BCCs at high-risk sites (nasolabial fold, periocular and nose), BCCs greater than 2 cm in diameter, certain histological subtypes (morpheaform, infiltrative, micronodular, basosquamous), and recurrent BCCs (1). According to ANEAS (Agence Nationale d'Accreditation et Evaluation en Santé) (57) moderately risky locations for surgical excision

- transplant recipients: a retrospective case - control series. *J Am Acad Dermatol* 2006;54:290-300.
20. Escutia B, Ledesma E, Serra-Guillen C, Gimeno C, Vilata JJ, Guillen C, et al. Detection of human papilloma virus and nodular basal cell carcinomas in immunocompetent subjects. *J Eur Acad Dermatol Venereol* 2011;25:32-8.
21. Aguilar Bernier M, Rivaz Ruiz F, De Troya M, Blazquez Sanchez N. Comparative epidemiological study of non-melanoma skin cancer between Spanish and North and Central European residents on the Costa del Sol. *J Eur Acad Dermatol Venereol* 2012;26:41-7.
22. Roewert-Huber J, Lange-Asschenfeldt B, Stockfleth E, Kerl H. Epidemiology and aetiology of basal cell carcinomas. *Br J Dermatol* 2007;157(Suppl 2):47-51.
23. Stern RS. The mysteries of geographic variability in nonmelanoma skin cancer incidence. (editorial). *Arch Dermatol* 1999;135:843-4.
24. Madan V, Lear JT, Szeimies RM. Non-melanoma skin cancer. *Lancet* 2010;375: 673-85.
25. Guillaume JC. Carcinomes basocellulaires. In: Saurat JH, Grosshans E, Laugier P, eds. *Dermatologie et infections sexuellement transmissibles*. 4th ed. Paris: Masson; 2004. p. 640-7.
26. Stang A, Ziegler S, Buchner S, Ziegler B, Jockel KH, Ziegler U. Malignant melanoma and nonmelanoma skin cancers in Northrhine-Westphalia, Germany: a patient-vs diagnosis based incidence approach. *Int J Dermatol* 2007;46:564-70.
27. Raasch BA, Buettner PG, Garbe C. Basal cell carcinoma: histological classification and body-site distribution. *Br J Dermatol* 2006;155:401-7.
28. Paravina M. Epidemiologija epitelnih malignih tumora kože [Epidemiology of epithelial malignant tumors of the skin]. Proceedings of the 16th Congress of Yugoslav dermatovenerologists; 2000 Sep 20-23; Igalo. Beograd: Yugoslav Association of Dermatovenerologists; 2000. p. 25. Serbian.
29. Paravina M, Spalević Lj, Janković A, Đokić S. Faktori rizika i neki epidemiološki pokazatelji malignih epitelnih tumora kože [Risk factors and some epidemiological characteristics of malignant epithelial tumors of the skin]. Zbornik rezimea XXXV Dani preventivne medicine [Book of abstracts 35th Days of Preventive Medicine]; 2001. Niš: Medicinski fakultet; 2001. p. 99-100. Serbian.
30. Pons M, Quintanilla M. Molecular biology of malignant melanoma and other cutaneous tumours. *Clin Transl Oncol* 2006;8:466-74.
31. Trakatelli M, Ulrich C, del Marmol V, Euvard S, Stockfleth E, Abeni D. Epidemiology of nonmelanoma skin cancer (NNSC) in Europe: accurate and comparable data are needed for effective public health monitoring and interventions. *Br J Dermatol* 2007;156(Suppl 3):1-7.
32. Mc Loone NM, Tolland J, Walsh M, Dolan OM. Follow-up of basal cell carcinomas: an audit of current practice. *J Eur Acad Dermatol Venereol* 2006;20(6):698-701.
33. Dauden E. Effectiveness and satisfaction with imiquimod for the treatment of superficial basal cell carcinoma in daily dermatological practice. *J Eur Acad Dermatol Venereol* 2011;25:1304-10.
34. Fantini F, Greco A, Dell Giovane C, Cesinaro AM, Venturini M, Zane C, et al. Photodynamic therapy for basal cell carcinoma: Clinical and pathological determinants of response. *J Eur Acad Dermatol Venereol* 2011;25:896-901.
35. Tiftikcaglu JO, Karaaslan D, Aksoy HM, Aksoy B, Koçer U. Basal cell carcinoma in Turkey. *J Dermatol* 2005;32:946-50.
36. Meneses N, Guides R, Moreira A, Mota G, Baptista A. Basal cell carcinoma: epidemiology from 269 cases. *J Eur Acad Dermatol Venereol* 2010;24:1359-60.
37. Paravina M, Jovanović S, Radelović J, Stanojević M, Spalević Lj, Todorović J, i dr. Karcinomi kože: analiza kliničkih i histoloških karakteristika [Skin carcinomas: analysis of clinical and histological characteristics]. *Acta Dermatovenerol Jugosl* 1990;17:157-61.
38. Arits AH, Schlangen MH, Nelemans PJ, Kelleners-Smeets NW. Trends in the incidence of basal cell carcinoma by histopathological subtype. *J Eur Acad Dermatol Venereol* 2011;25:565-9.
39. Abeldano MA, Pincay Cedeno L, Neglia V, Brea P, Retamar R, Kien M, et al. Basal cell epithelioma of atypical localisation. *J Eur Acad Dermatol Venereol* 2001; 15(Suppl 2):167.
40. Gibson GE, Ahmed I. Perianal and genital basal cell carcinoma: a clinicopathologic review of 51 cases. *J Am Acad Dermatol* 2001;45:68-71.
41. Mulayin N, Silver DF, Ocal JT, Babalola E. Vulvar basal cell carcinoma: two unusual presentation and review of the literature. *Gynecol Oncol* 2001;85:531-7.
42. Pisani E, Poggiali S, La de Padova, Andreassi A, Bilenchi R. Basal cell carcinoma of the vulva. *J Eur Acad Dermatol Venereol* 2006;20:446-8.
43. Woo SH, Kim IH, Son SW. Axillary basal cell carcinoma. *J Eur Acad Dermatol Venereol* 2006;20:222-3.
44. Betti R, Crosti C, Moneghini L, Crespi E, Menni S. Axillary basal cell carcinoma: Additional 25 patients and consideration. *J Eur Acad Dermatol Venereol* 2011;25: 858-60.
45. Crowson AN. Basal cell carcinoma: biology, morphology and clinical implications. *Modern Pathol* 2006;19:S127-47.
46. Rigell DS, Cockerell CJ, Caruci J, Wharton J. Actinic keratosis, basal cell carcinoma and squamous cell carcinoma. In: Bologna JL, Jarizzo JL, Rapini RP. *Dermatology*. 2nd ed. St. Louis: Mosby Elsevier; 2008. p. 1641-60.
47. Wolff K, Johnson KA, Suurmond D. *Fitzpatrick's color atlas and synopsis of clinical dermatology*. New York: McGraw-Hill; 2005. p. 282-9.
48. Stojanović S, Poljački M. Klinička slika bazocelularnog karcinoma kože [Clinical picture of basal cell carcinoma of the skin]. In: Poljački M, Ed. *Bazocelularni i spinocelularni karcinom kože* [Basal cell and spinocellular skin cancers]. Novi Sad: Medicinski fakultet; 1997. p. 43-7. Serbian.
49. Višnjic MM. Hirurgija tumora kože i mekih tkiva. [Surgery of skin tumors and soft tissues]. Niš: Prosveta; 1997. str. 16-25.
50. Rippey JJ. Why classify basal cell carcinomas? *Histopathology* 1998;32:393-8.
51. Vučković N, Vučković D. Histogeneza i mikroskopske karakteristike [Histogenesis and microscopic characteristics]. U: Poljački M, Ed. *Bazocelularni i spinocelularni karcinom kože* [Basal cell and spinocellular skin cancers]. Novi Sad: Medicinski fakultet; 1997. p. 35-42. Serbian.
52. Rubin AJ, Chen EH, Ratner D. Basal cell carcinoma. *N Engl J Med* 2005;353: 2262-9.
53. LeBoit PE, Burg G, Weedon D, Sarasin A, eds. *World Health Organisation classification of tumors: pathology and genetics of skin tumors*. Lyon: IARC Press; 2006. p. 10-33.
54. Popadić S, Tanasilović S, Živanović D, Medenica Lj. Genital

karcinom kože je značajno najčešće ($p < 0,0001$) bio lokalizovan na mestima stalno izloženim suncu (glava, tj. lice i pogravina i vrat), što se slaže sa podacima iz literature, prema kojima se bazocelularni karcinom kože najčešće javlja na glavi i vratu, a prevalencija se kreće između 85% i 56,9%. Prema podacima iz literature, bazocelularni karcinom kože lokalizovan na glavi i vratu je u 85–90% slučajeva izazvan sunčanom radijacijom, a na foto-neeksponiranim regijama javlja se retko i može značiti prisustvo nekog drugog etiološkog mehanizma. Kod 11% naših ispitanika, kod kojih je lokalizacija bazocelularnog karcinoma kože bila na fotoneeksponiranim regijama, mi nismo mogli utvrditi podatke o drugim etiološkim faktorima. S obzirom na postojeću hipotezu da smanjeni imunonadzor izazvan ultravioletnom radijacijom na udaljenim mestima, može predstavljati patomehanizam nastanka bazocelularnog karcinoma kože na mestima zaštićenim od sunca, to bi moglo značiti da se i u ovih 11% slučajeva nije mogla u potpunosti isključiti uloga ultravioletnog zračenja.

U literaturi su objavljeni slučajevi bazocelularnog karcinoma kože sa atipičnim i neuobičajenim lokalizacijama – na vulvi i u aksili. Bazocelularni karcinom kože je registrovan na dorzalnoj strani šake kod jedne naše pacijentkinje, što se izuzetno retko viđa, iako je ova regija često izložena suncu, što bi se moglo objasniti malom koncentracijom pilosebacealnih jedinica na toj regiji kože.

Najčešći klinički oblik bio je nodularni (57%), a bili su dijagnostikovani i superficijalni (7%) ulcerozni (5%), ulcerosklerotični tip (4%), pigmentni (1%) i morfeaformni (1%). U 25% slučajeva, u Histopatološkom registru nisu postojali podaci na osnovu kojih bi se mogao tačno odrediti klinički tip bazocelularnog karcinoma kože. Pojedini autori klasifikuju bazocelularni karcinom kože u 7 kliničkih tipova, drugi u 5, ili u 5 osnovnih, 2 atipična i 3 reda klinička tipa, ili u 10 tipova. Nijedna od podela se ne poklapa u potpunosti. S obzirom na lokalizaciju kod naših pacijenata, najčešće je bio registrovan nodularni klinički oblik pri čemu je značajno više bilo nodularnih bez ulceracije nego sa ulceracijom ($p < 0,01$). Sama za sebe, klinička klasifikacija je od malog značaja za prognozu. Veličina lezije predstavlja faktor rizika koji utiče na prognozu.

S obzirom na lokalizaciju i kliničku sliku bazocelularnog karcinoma kože kod naših ispitanika, najčešće

dijagnostikovani histološki tip bio je nodularni, što je u saglasnosti sa rezultatima u literaturi. Smatra se da nodularni histološki tip ovog karcinoma čini do 60% svih histoloških tipova, najčešće se lokalizuje u predelu glave i vrata, ali se može lokalizovati i na trupu i ekstremitetima. Na osnovu rezultata patohistološke analize u našem ispitivanju, pored nodularnog tipa (40%), bili su dijagnostikovani značajno ređe i adenoidni (12%) ($p < 0,0001$), mešoviti tipovi (nodulo-adenoidni, nodulo-adenoidno-fibroblastični i mikstni) (9%), superficijalni (7%), fibroblastični (2%), infiltrativni (1%), pigmentni (1%) i morfeaformni (1%). U 25% slučajeva u Histopatološkom registru nisu postojali podaci na osnovu kojih bi se mogao tačno odrediti klinički tip bazocelularnog karcinoma kože.

Histološka klasifikacija je od velikog značaja s obzirom da histološka građa tumora utiče na njegov klinički tok: agresivni histološki suptipovi (mikronodularni, infiltrativni, morfeaformni; bazoskvamozni i mešoviti); manje agresivni histološki suptipovi (nodularni i superficijalni). I u terminologiji histoloških formi postoje razlike među autorima. Svetska zdravstvena organizacija je objavila klasifikaciju sa 8 histoloških tipova: superficijalni, nodularni, mikronodularni, infiltrativni, fibroepitelijalni, bazoskvamozni, keratotični i bazocelularni karcinom sa adneksalnom diferencijacijom.

Terapija: Zlatni standard u terapiji bazocelularnog karcinoma kože jeste hirurška ekscizija: konvencionalna koja je sprovedena u ovom radu i Mohsova mikrograf-ska koja ima značajno mesto u lečenju visokorizičnih bazocelularnih karcinoma kože. Mesto ekscizije mora biti okruženo zdravim tkivom da bi ekscizija bila adekvatna, što određuje njen uspeh. Kod 6% naših bolesnika nađen je tumorski proces na ivicama ekscizije. Santiago i saradnici su od 947 bazocelularnih karcinoma kože koje su ekcidirali nekompletnu eksciziju našli kod 90 (9,5%) bolesnika. Kod 29 (32,2%) ovih bolesnika potvrđen je recidiv. Prosečno trajanje remisije je iznosilo 12 meseci (raspon od 1 do 57 meseci). Zavisno od mesta, veličine, ivica tumora, prethodnog tretmana i histologije, ekscizija margina bazocelularnog karcinoma kože od 3–10 mm, može biti racionalna u najmanje 95% slučajeva. Tako su Rigel i saradnici, sa marginom od 4 mm, adekvatno uklonili 98% nemorfeaformnih tumora manjih od 2 cm u prečniku. Dermoskopskom detekcijom ekscizionih ivica može se dobiti histološka potvrda kompletne ekscizije u

Head&Shoulders, lider u inovacijama u borbi protiv peruti

Head & Shoulders tehnologija

Naučnici iz Head & Shoulders-a su na čelu nauke za kožu glave i kose, gde su preko 40 godina značajno unapređivali znanje i tretiranje peruti, bivajući prvi koji su predstavili ZPT (Zink Pyrithione) kao veoma efikasan aktiv protiv peruti i optimizovali ga tokom decenija da pruži sadašnju tehnologiju koja je najefikasnija u istoriji Brenda.

Aktivnost i bioraspoloživost ZPT u Head & Shoulders-u su povećane putem dva pristupa:

- 1) ZPT čestice su dizajnirane za optimalno taloženje i aktivnost na koži glave
- 2) Anti-gljivična aktivnost je povećana cink karbonatom koji povećava bioraspoloživost ZPT na koži glave.

Pored toga, svi Head & Shoulders proizvodi su dizajnirani da pruže velike kozmetičke koristi kosi, prilagođene širokom spektru potreba nege kose.

Perut i Zink PYRITHIONE šampon

Dermatitis seboroična ili perut, je skoro pa fiziološko stanje kože koje pogađa oko 50% od indoevropske populacije, poznato i kao Pityriasis simplex, furfuracea ili Malassezia furfur. To stanje je povezano sa proliferacijom Stratum korneuma koje izaziva kvasnica m. furfur. Tačna uloga ove kvasnice je još uvek kontraverzna, ali postoje dokazi da je perut rezultat slabog odgovora imunoloških mehanizama na njenu prisutnost, što dovodi do upalnog odgovora koji rezultira ekcematoznim stanjima. Postoji jaka povezanost sa androgenim aktivnostima i u velikoj meri sa seborejom. Obično se klinički manifestuje kao ljuskanje kože glave na područjima prekrivenim terminalnom dlakom (seboroične regije). Studije (1) su pokazale da je perutanje okarakterisano kao hiper-proliferacija epidermisa, čemu u prilog govori promet stanica sa prisutnim parakeratocitnim jedrima u stratum corneum(1). TEM (transmisiona elektronska mikroskopija) istraživanja su identifikovala nekoliko patoloških promena u stratumu korneumu perutom zahvaćenog tkiva kože glave. •Pri (TEM-u) vlasi vidi se da perut vlasi poseduje abnormalne ultra strukture stratuma corneuma (SC). Poređenje zink pyrithione (ZPT) proizvoda sa placebo preparatima pokazuje značajan napredak u SC ultrastruktura, sugerišući da kozmetički proizvodi koji sadrže ZPT bolje kontrolišu površno ljuštenje i imaju fiziološka poboljšanja na SC koje se tumače kao poboljšanja na koži glave koji i izgleda "zdravije". Kliničke studije SC abnormalnosti kod peruti se sastoje iz hiperproliferativnog stanja, uključujući parakeratozu, pojavu masnih kapljica u korneocitima, nekoliko desmosoma i interdigitaciju korneocitne membrane sa ekstenzivnom disorganizacijom intrastaničnih lipida. Ove abnormalnosti se pojavljuju duž kože glave koji je sklon perutanju čak i kada ljuskanje nije prisutno. Ako je hiperproliferativno stanje izvor ljuskanja onda

kontrola peruti zahteva popravku SC struktura. Klinički protokol je razvijen da bi kvantifikovali strukturne abnormalnosti vlasi gde bodovanjem stanica epidermisa vlasi na osnovu broja kvasnica, količine međustaničnih lipida, i normalnih intrastaničnih struktura, zastupljenosti masnih kapljica, broja parakeratocitnih korneocita i incidence korneocitne interdigitacije donose se zaključci o efikasnosti (ZPT). Studija je rađena na 12 osoba sa različitim težinom peruti. Težina perutanja ispitanika studije je evaluirana upotrebom skora za ljuskanje kože glave (ASFS), a procedura je slična onoj koju je koristio Van Abbe. Nasumično im je dodjeljen komercijalni 1% zink pyrithione šampon (Head & Shoulders) i drugi šampon koji nije sadržao zink pyrithione. Svaka grupa se sastojala od 6 ispitanika. Oni su instruirani da koriste ove šampone svaki drugi dan u trajanju od 3 nedelje, koliko je i sama studija trajala. Niti jedan drugi tretman kose im nije bio dozvoljen. Po završetku studije, ponovo je urađena evaluacija ASFS skora istih područja koja su pregledana na početku studije. Svi su ponovo pregledani TEM mikroskopijom koja je opisana prethodno. Učinkovitost proizvoda sa kliničke tačke gledišta je utvrđena oduzimanjem početnog ASFS skora iz konačnog rezultata. Pozitivniji broj indicira veći uspeh u stanju perutanja kože glave (manje peruti, veća efikasnost proizvoda). Negativan broj znači da se perut pogoršala. Učinkovitost proizvoda sa stanovišta zdravlja kože je evaluirana posmatranjem promena u SC morfologiji od inicijalnog pregleda pa do finalnog. Statističke razlike među grupama su utvrđene pomoću jednog faktora varijance. Rezultati su podrazumevali razlike za za $p < 0,05$.

Rezultati studija su pokazali poboljšanja ultrastrukturnih promena u SC zahvaćenim perutanjem, pokazale su smanjenu prisutnost gljivica, parakeratocitnih jezgara, smanjenu pojavu lipidnih inkluzija unutar korneocita i očito smanjenje desmosoma. Dodatne abnormalnosti povezane sa perutanjem kože glave smanjile su izvijenost membrane korneocita i očito smanjenje međustaničnih lipida. Raznolik je ultrastrukturni odgovor korneocita kod pojedinih osoba sa peruti. Tretman peruti sa komercijalnim zink pyrithione šamponom rezultira klinički vidljivom poboljšanju kao i poboljšanju u SC sloju epidermisa. Evaluacija mikroskopiranjem prikazuje da Zink Pyrithione šampon poboljšava strukturu vlasi samim smanjenjem perutanja. Evaluacija mikroskopiranjem je pokazala da šampon bez zink pyrithione ima relativno manje efekte na SC ultrastrukture peruti.

Zaključak: Postoji nekoliko studija koje proučavaju ultrastrukturu peruti. Svetlosna i elektronska mikroskopija biopsije, opisuje prisustvo mikroorganizama i pojavu hiperproliferacije epidermisa kože glave sa parakeratocitnim jedrima, lipidnim inkluzijama u korneocitima, smanjenje broja desmosoma i relativno česte rascepe među korneocitima. Upotrebom novih fiksacionih tehnika za vizuelizaciju SC lipida, potvrđuju se strukturalne abnormalnosti koje se javljaju kod peruti. Takođe je pronađeno u spoljašnjem SC-u da osobe pogođene perutanjem vlasi obično imaju povećanu količinu međustaničnih lipida sa nekoliko različitih ultrastrukturnih prikaza, kao što su tamne mrlje i amorfne strukture za koje se veruje da nalikuju promenama opisanih za sebum(24) ili supstancu "poput zemlje" koja sadrži brojne tamne depozite čestica. Ultrastrukturne abnormalnosti kod peruti, očito su smanjene pomoću zink pyrithione šampona: broj Malassezia je smanjen, prekomerni međuceljski lipidi su bili smanjeni, parakeratosa je eliminisana, lipidi unutar korneocita uveliko su smanjeni, a morfološki mrtve stanice eliminisane. Iako je vizuelna patologija peruti locirana u SC, ovaj sloj reflektuje fundamentalnim promenama koje se javljaju kod germinativnih stanica koje proizvode ovaj sloj. Može se zaključiti da normalizacija SC ultrastruktura sa zink pyrithione nastaje usled korekcije patoloških promena u germinativnim slojevima epidermisa.

with fibrinoid degeneration within and around the microvessels is often seen. GF follows a chronic course with intermittent acute flares. It is often refractory to treatment and tends to relapse when treatment is discontinued. As a result, a wide variety of treatment modalities, both surgical and medical, have been used to treat this condition.

We present a patient with GF on the nose, misdiagnosed clinically as basal cell carcinoma and pyogenic granuloma on histopathology examination and treated as granuloma annulare.

Case report

A 65-year-old woman was admitted to our Department with a 5-month history of gradually enlarging, asymptomatic, infiltrated lesions on her nose. Four months before, a clinical suspicion of basal cell carcinoma was made by a plastic surgeon and an excisional biopsy from the middle of the infiltrated plaque on the back of the nose was performed. Histological examination of the biopsy specimen revealed a dense inflammatory infiltrate that consisted of eosinophils in combination with neutrophils, histiocytes and lymphocytes. Numerous dilated blood vessels with edematous walls were found. Her original histological diagnosis, made by a pathologist, was pyogenic granuloma. Beside these findings, skin lesions were identified as granuloma annulare, and treated with open-spray cryotherapy

by a dermatologist. Cryotherapy with liquid nitrogen caused no improvement of the lesion, with peripheral enlargement, so the patient asked for second opinion.

Physical examination revealed a sharply bordered (3 x 2.5 cm), erythemolivid plaque, over the back and the tip of the nose. In the center of the lesion an atrophic cicatrix was seen on the site of the biopsy. The infiltrated plaque showed orange-peel surface markings with prominent telangiectasia (Figure 1a-c). The patient was otherwise healthy and all laboratory tests were normal. Peripheral blood eosinophils were within a normal range.

Revision of the biopsy specimen, performed by a dermatopathologist at our Clinic, revealed a normal-appearing epidermis and a dense, mixed, inflammatory infiltrate in the upper and mid dermis. The infiltrate was composed of numerous eosinophils and neutrophils, lymphocytes, histiocytes, and plasma cells. A band of normal collagen referred to as a "Grenz' zone" typically separated the inflammatory infiltrate from the epidermis and pilosebaceous appendages. In addition, vasculitis, with fibrinoid deposits near and within the vessel walls, and extravasation of erythrocytes around the capillares were also evident. A mild fibrosis area was also found. These findings were in agreement with the diagnosis of GF (Figures 2,3,4).

Several treatments with mid-to high-potency topical corticosteroids showed only minimal and transient improvements during drug administration,

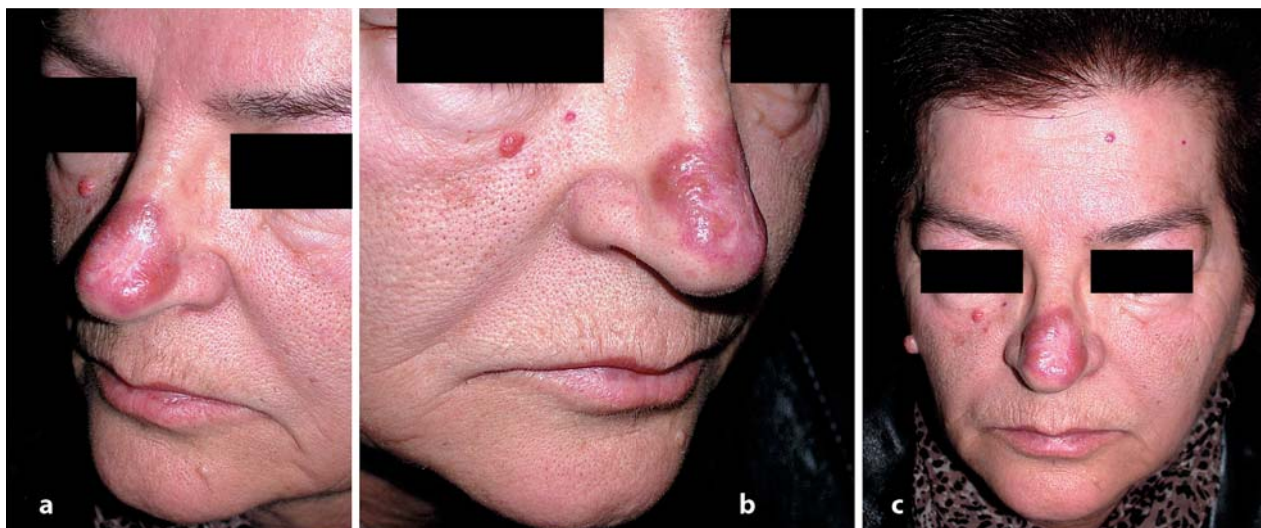

Figure 1. Granuloma faciale: a) sharply bordered (3 x 2.5 cm), erythemolivid plaque over the back and the tip of the nose; b) orange-peel surface markings and prominent telangiectasia; c) in the center of the lesion there is an atrophic cicatrix on the site of the biopsy

telangiectasia. The diagnose is based on clinical and histopathological findings. GF is also characterized by a mixed inflammatory infiltrates with a predominance of eosinophils and neutrophils, separated from the normal appearing epidermis and pilosebaceous structures by a band of normal collagen without cells. Granuloma faciale is an uncommon condition. The first thorough review of GF was published by Pedace and Perry in 1966 (9). They reported on 21 patients (13 males and 8 females), 7 of whom (33%) had a single lesion. Extrafacial lesions were found in two patients. A Grenz zone was usually present, and tissue eosinophilia was considered to be necessary for microscopic diagnosis of GF.

In 2004, Marcoval et al. published findings on 11 patients (9 males and 2 females) with GF (10). All of them had facial lesions. Histopathologically, all cases showed a Grenz zone, a dense infiltrate with eosinophils and neutrophils, extravasated erythrocytes and nuclear dust.

The largest clinicopathological study of 66 patients (41 males and 25 females) with GF was performed by Ortonne et al. (5). Five patients presented with extrafacial lesions, while forty patients (62%) showed single lesions. The most frequent histopathological findings included presence of lymphocytes (100%), neutrophils (93%), telangiectasia (74%), a Grenz zone (74%), hemosiderin (70%) and leukocytoclasia (66%). In contrast to previous studies, eosinophils were found only in 57.5% of cases and extravasated erythrocytes only in 19%. Dermal fibrosis was present in 45%. Clinical diagnosis of GF was made in only 10 cases; sarcoidosis, lupus, lymphoma and basal cell carcinoma were the main differential diagnoses.

The disease mimics many other dermatoses and may be confused with other conditions, such as sarcoidosis, granuloma annulare, lymphocytic infiltrate of Jessner, basal cell carcinoma, angiolymphoid hyperplasia with eosinophilia, discoid lupus erythematosus, mycosis fungoides or erythema elevatum diutinum, when extrafacial localization occurs. Our patient was clinically misdiagnosed as basal cell carcinoma, because the lesion was solitary, localized on the back and the tip of the nose, with prominent telangiectasia, and raised border of coalescent nodules.

The most likely pathologic differential diagnosis of GF is erythema elevatum diutinum (EED). The

histopathology of GF and EED is very similar and overlapping due to identical sequential inflammatory changes. First, there are neutrophils accompanied by nuclear dust, which are followed by eosinophils, lymphocytes, plasma cells and finally macrophages (11).

Criteria for histopathological distinction of GF from EED in classical dermatology books include sparing of the epidermis and papillary dermis, presence of many eosinophils within the infiltrate and less fibroplasia. In their retrospective study, Ziemer M. et al. reviewed in a blinded manner, 9 cases of EED and 41 cases of GF (8). High density of the infiltrate was noted in 97% of cases with GF, but only in 56% of cases with EED. Eosinophils were the predominant cell type in 59% of cases with GF, but in none of the cases with EED. Plasma cells were more frequent in GF (64%) than in EED (22%), and granulomas were not found in GF, but in 22% of EED. A zone of perijunctional sparing (Grenz zone) was observed in about three quarters of cases in both groups. They concluded that presence of a Grenz zone and patterned fibrosis does not distinguish the two diseases. It remains controversial whether EED and GF are separate entities or different names for the same condition at different anatomic sites taking into account that GF is predominantly located on the head, and EED involves extremities or trunk.

Histological interpretation of the biopsy specimen from the infiltrated plaque on the nose was misinterpreted as granuloma pyogenicum. Although lobular proliferation of small blood vessels, which erupt through a breach in the epidermis, to produce a globular pedunculated tumour was missing, the proliferating vessels surrounded by a mixed cell population of fibroblasts, mast cells, lymphocytes, plasma cells and polymorphonuclear leukocytes initiated the diagnosis of granuloma pyogenicum.

Due to the prominent location of GF on the face, treatment is often desired. The pathogenesis of the disease is unknown, and no etiological treatment exists. Its therapy remains a challenge, but spontaneous resolutions have also been reported. Therefore, different destructive and antiinflammatory and antiproliferating agents have been used, but none of them has been consistently satisfactory. Surgical excision of the lesion, which was already used in the past (12) seems to be ineffective,

- nm pulsed dye laser. *Dermatol Surg* 2011;37:102–4.
25. Mitchell D. Successful treatment of granuloma faciale with tacrolimus. *Dermatol Online J* 2004;10:23.
26. Tomson N, Sterling JC, Salvary I. Granuloma faciale treated successfully with topical tacrolimus. *Clin Exp Dermatol* 2009;34:424–5.
27. Ertam I, Ertekin B, Unal I, Alper S. Granuloma faciale: is it a new indication for pimecrolimus? *J Dermatol Treat* 2006;17:238–40.

Abbreviations:

- GF – Granuloma faciale
 EED – Erythema elevatum diutinum
 IL – Interleukin
 PUVA - Photochemotherapy (psoralen +UVA)
 CO₂ – Carbon dioxide
 PDL – Pulsed dye laser

Facijalni granulom – da li ga je teško dijagnostikovati? – Prikaz slučaja

Sažetak

Uvod: Granuloma faciale ili granuloma faciale eosinophilicum je retka, hronična inflamatorna dermatoza koja se klinički manifestuje asimptomatskim crvenkasto-braon ili lividnim nodulima ili plakovima, koje su primarno lokalizovane na licu, a retko mogu da se jave i ekstrasfacijalno. Bolest se javlja kod oba pola, ali se češće sreće kod muškaraca srednje dobi. I pored toga što je etiopatogeneza bolesti nedovoljno razjašnjena, granuloma faciale predstavlja lokalizovanu varijantu hroničnog leukocitoklastičnog vaskulitisa sa izrazitim eozinofilnim infiltratom. U prilog tome da je granuloma faciale imuno-kompleks medirani vaskulitis govori nalaz IgG depozita unutar i oko dermalne vasculature. Imunohistohemijskim markiranjem detektuju se CD4+ limfociti koji sintetizuju IL-5, moćni eozinofilni hemoatraktant. Histopatološkim pregledom može se utvrditi prisustvo gustog polimorfnog inflamatornog infiltrata koji se sastoji pretežno od eozinofila i neutrofila. Karakteristično je da je infiltrat odvojen od intaktnog epidermisa i pilosebacealnih jedinica sa uskom zonom normalnog kolagena, siromašnom ćelijama tzv. Grenz zona. Može se naći leukocitoklastični vaskulit, a u kasnijim fazama bolesti, prisutna je fibroza. Dijagnoza se potavlja na osnovu kliničke slike, facijalne lokalizacije dobro ograničenih, mekih eritemno-braonkastih nodulusa ili plaka, sa sjajnom površinom na kojoj se vide teleangiectazije i dilatirani folikularni otvori, što daje lezijama izgled pomorandžine kore. Definitivna dijagnoza granuloma faciale se postavlja na osnovu prisustva klinički tipičnih lezija i potvrđnog histopatološkog nalaza. Granuloma faciale ima hroničan tok sa intermitentnim akutnim kliničkim pogoršanjem. Ne zahvata unutrašnje organe. U

velikom broju slučajeva bolest je refraktorna na različite destruktivne ili antiinflamatorne tretmane. Zbog toga granuloma faciale predstavlja dijagnostički i terapijski izazov.

Prikaz slučaja: Prikazujemo 65-godišnju ženu sa petomesečnom anamnezom o kontinuiranom povećanju asimptomatske, infiltrirane lezije na nosu. Pre četiri meseca, specijalista za plastičnu hirurgiju je postavio kliničku dijagnozu bazocelularnog karcinoma i uradio ekscizionu biopsiju središnjeg dela lezije, a od strane patologa postavljena je histopatološka dijagnoza granuloma pyogenicum. Histološka interpretacija opisivala je prisustvo gustog inflamatornog infiltrata sastavljenog od eozinofila u kombinaciji sa neutrofilima, histiocitima i limfocitima, sa brojnim dilatiranim kapilarima. I pored ovog nalaza, konsultovani dermatolog je smatrao da se radi o granuloma annulare i tretirao je pacijenticu krioterapijom. Krioterapija sa tekućim azotom izazvala je pogoršanje lezije, odnosno njeno povećanje na periferiji. Pacijentica je tražila ekspertsko mišljenje na Univerzitetској Klinici za Dermatologiju u Skoplju. Pregledom je utvrđeno prisustvo eritemo-lividnog plaka na nosu, jasno ograničenog, sa dimenzijama 3 x 2.5cm. U centru lezije bio je vidljiv atrofični cikatriks na mestu prethodne biopsije. Površina plaka imala je izgled pomorandžine kore sa dilatiranim folikularnim otvorima i teleangiectazijama (Slike 1a-c). Pacijentica je inače bila zdrava sa urednim laboratorijskim nalazima, bez eozinofilije u perifernoj krvi. Urađena je revizija histološkog preparata koji je pacijentica donela.

Histopatologija: U revidiranom histološkom preparatu bio je prisutan normalan epidermis i gust mešani

Quackery in the treatment of syphilis in Serbia

Bosiljka M. LALEVIĆ-VASIĆ

Clinic of Dermatology and Venereology, Clinical Center of Serbia, Belgrade, Serbia

*Correspondence: Bosiljka Lalević-Vasić, E-mail: labuba@gmail.com

UDC 616.972:614.26(497.11)

Abstract

During the multi-century Ottoman rule, there were no educated physicians in Serbia, and “folk healers” used to treat the sick. Just after the 3rd decade of the 19th century, when the first educated physicians came to Serbia, we can also speak about quackery. At that time, syphilis started spreading and some quacks became “specialists for syphilis”. They were most numerous in the North-East Serbia in the 4th and 5th decades of the 19th century. They represented a major problem, because people believed them more than they believed physicians, while the state authorities of just liberated country, tolerated them. The quacks were not familiar with the clinical features of syphilis, and mostly used mercury to treat it by fumigation and inhalation, rubbing it into the skin, proscribing mercury pills, while symptoms of severe, sometimes lethal intoxication were signs of successful treatment. They also used sarsaparilla. Authorities of the new Government often issued them permission to work, whereas professional control and prohibition of such treatment began in 1839, when the Health Department of the Ministry of Internal Affairs was established.

The most famous quack, “specialist for syphilis”, was Gojko Marković, who was also a “physician” and the first director of the Hospital for the treatment of syphilis in Serbia during a certain period. A married couple, Gaja and Kita Savković, were also well known, as well as Stojan Milenković, a young man in the service of Prince Miloš. There were, of course, many adventurers, imposters, travelling Turkish and Greek physicians, Gipsies, fortune-tellers, old women, and ignorant people of various professions. Their work was banned by the Government.

Key words

History of Medicine; Quackery; Serbia; Syphilis; History, 19th Century

The Medical Annual of the Kingdom of Yugoslavia from 1933, defines “quackery, as a concept and an activity, contrary to legal regulations, just like a statement and an offense, which began with the foundation of first medical schools, when educated physicians, although not always privileged, were only responsible for treating the sick”. Thus, quackery existed only in areas where educated doctors, though very few, practiced medicine (1). If this explanation is accepted as true, quackery in Serbia started not before the thirties of the 19th century, because under the Ottoman rule, as well as during the first decades of the 19th century, there were no educated physicians in Serbia. The first educated physician in Serbia, Dr. Alexandridi, started working in 1818 (2). After that, in

1823, Mito Romita was the physician of the Belgrade Vizier, and later of Prince Miloš. Not before 1829, T. Đorđević (3) specified the names of four physicians: Dr. Jovan Stejić, Dr. Kunibert, Dr. Đorđe Novaković (baptized Leopold Erlih), a surgeon in Jagodina, and a Russian doctor in Požarevac. There was also a Turkish doctor in Čačak.

Quacks should not be confused with “folk healers” who were present in our history during the multientury Ottoman rule, but at the time when there were no trained doctors in Serbia. Vuk Karadžić used to call them “natural doctors“, as they even had copies of treatment codes, which were passed on from generation to generation, as well as some other gathered knowledge. At that time, “folk healers” were the only

mostly old women, wondering around, use cinnabar fumigation”, so that most patients” are permanently crippled or dead». He suggested foundation of a hospital for patients suffering from “frega”, otherwise “all the people will be poisoned” (7). At first even the highest State authorities were without definite attitudes towards quackery, so “specialists for syphilis” were given approval to work by the Governship, the State Council and Magistrates, sometimes even by the Health Department of the MIA. It remains unclear under which criteria they did it (4), bearing in mind that competence and attitude of public and health institutions were not in accordance at various levels. It was also important that people were used to “folk healers” for centuries of their slavery and they trusted them more than the doctors (4). Those who were superstitious were also very friendly and kind to quack doctors, so they cared about them, hid them in the times of troubles, whereas delivery of their names to the authorities was sometimes considered a sin in God’s eyes. Even in fatal torment, caused by the treatment of quacks, people consistently refused to reveal the perpetrators of their misfortune (11). Although to a lesser extent, the problem existed in the enlightened Europe as well: in 1906, there were 31.304 physicians and around 10.000 quacks in Germany (12); it is also a well known fact that in the 18th and 19th century the number of quacks treating syphilis in England was extremely high (15). Apart from that, physicians were very rare in Serbia for a long time: in 1837 there were only 9 physicians in the country (16).

Therapeutic modalities of quacks – “specialists for syphilis”

Before presenting quack doctors individually, we will explore what were the therapeutic means at their disposal. During almost four centuries the standard anti-syphilis therapy included: *mercury*, *guaiacum*, *sarsaparilla* and *sassafras* (17). According to available data, quack doctors in Serbia used *mercury* and *sarsaparilla*.

Mercury

From the earliest times, *mercury* was associated with medicine and chemistry, but special emphasis was given to it since the end of the 15th century, when syphilis began to spread across Europe (18). Medicine

of that time was under great influence of “humoral theory”, and it was believed that *mercury* healed by inducing “pittuit” or “phlegm” secretion causing venereal poison leaching. The treatment of syphilis using *mercury* was performed by: *inunction of mercury*; *fumigation* or *using mercurial plasters*; since 1536 peroral pills were used; intramuscular injection of *mercury* appeared later, and it was the only advance in the treatment of syphilis at the end of the 19th century (17). The criterion used in the assessment of drug effects was increased salivation: it was advised to secrete at least three pints of saliva a day, in order to achieve therapeutic effects; if the quantity was lower, the dose of *mercury* was increased; tooth loss and oral ulcerations were evidence of adequate treatment (17).

However, Discorides, a classical author, already wrote that mercury was a “deadly poison”, while in the 18th century, there were some doctors who required decrease in the amount of salivation, thus considering decrease in the quantity of mercury. Using mercury as a treatment option was a problem from the very beginning, because the therapeutic dose (*dosis curativa*) and the highest tolerated dose (*dosis tolerata*) were very close (17), so doctors were searching for the optimum dose and efficacy of mercury, as well as for the best route of administration: there were those who were in favour of peroral therapy (19), as the best and the most common (20), whereas the others thought *inunction* and *fumigation* were better, because the drug did not get directly to the liver, as by oral administration, causing no damage to internal organs and general condition of the patient. Considering the fact that *inunction* (rubbing mercury into the skin) caused soiling the clothes, *fumigation* had plenty of supporters. Mercury vapour was used by combustion of a mercury preparation and it was done in two ways: *fumigation over the skin* under a plastic layer which enclosed the body and the source of mercury vapour, closed around the neck, so that the head was free and the respiratory organs were spared (21); the other way was *fumigation by inhalation of the mercury* vapour (8, 20). Patients were also required to be on a certain diet (20). In 1831, suppression of mercury started by initiation of potassium iodine in the treatment of secondary syphilis; later it was accepted by quacks as well, so patients used to buy it themselves as “white iodine”; Salvasan was discovered in 1909 (8), and Bismuth in 1921 (22).

After returning to Serbia, from 1836 to 1838, Gojko Marković treated people from “frega”, from village to village, in North-East Serbia (3).

Back in 1836, Gojko Marković even established a private hospital (25), and in some periods he even kept proper records of his work. He made a list of patients from 6 counties (46 villages), but specified only their number – 149 patients, 69 male and 80 female. According to V. Mihajlović, it might have been the first statistics about syphilis in Serbia (4). Gojko Marković was a very distinguished person: on October 11, 1838, the State Council decided to pay his fees for treating the poor, while he was to charge the rich himself (3, 4). It was the first time that free treatment of patients with syphilis was available, although for a limited number of people. In the same year, the Magistrate of the Gurgusovac District decided to open a hospital exclusively for patients with syphilis. It was done for many reasons: syphilis was spreading, it was hard for “doctor” Gojko to visit village after village, and the “diet” he prescribed could not be carried out. Considering the fact that Gojko Marković enjoyed great popularity and reputation among the people and authorities, he was intended for the “physician” and the director of the hospital. After the State Council approved this project, the Magistrate rented an empty Inn for 120 groshes on the outskirts of the town, and the patients were settled comfortably. Thus, this hospital, directed by Gojko Marković, was approved from the highest levels as the first hospital for treatment of syphilis in Serbia. The hospital worked a little longer than a year, and despite its all shortcomings, it was the first attempt of organized treatment of syphilis in Serbia (3, 4).

However, Dr. K. Pacek, head of the newly founded Health Department, opposed the decision that an incompetent person should be in charge of a hospital (4): and at his request, a surgeon, Đ. Novaković, submitted a comprehensive report on the work (see below) of Gojko Marković and of the newly founded hospital, concluding that “it was completely inappropriate” and that a more experienced physician should be sent to assess the work of Gojko Marković (4).

Based on that report, a very active correspondence began between the Gurgusovac Magistrate, Health Department of the MIA, the State Council, the

Governorship, even Prince Mihailo, which lasted from October 1838 until the end of 1839. The correspondence started with a challenging letter of the Health Department of the MIA, informing the State Council that it was “dangerous to put partly toxic drugs at the disposal of a man with merely empiric knowledge... that it was outrageous to entrust a whole hospital to a man who knew nothing about hospital routine...”. The State Council and the Governorship did not accept these suggestions, so the MIA (Health Department) issued an act to keep Gojko Marković as the director of the hospital “until doctors showed enough experience and knowledge and guaranteed that they were capable to treat this disease like him” (25). Gojko Marković received 200 thalers for his work, and this Act was signed by Prince Regents: Avram Petronijević, Efre Obrenović, and Toma Vučić-Perišić (4). Obviously, members of the State Council and the Governorship were insufficiently informed, often uneducated and inclined to the public opinion. The wage to which Gojko Marković was entitled to was good, because at that time salaries of physicians and pharmacists ranged from 150 to 500 thalers (25). Vojislav Mihajlović did not exclude the possibility that Gojko Marković had a patronage of some members of the State Council, so that the MIA was forced to entrust the hospital in Gurgusovac to a quack doctor, but after this affair, his name was no longer found in any reports. Further correspondence between the MIA and the Governorship showed that they began accepting opinions of professional institutions. In 1839, all districts got trained physicians (25), implementing active fight against quackery.

Today we are familiar with the diagnostic and therapeutic procedures of Gojko Marković due to the abovementioned report of the surgeon Đ. Novaković. First of all, Marković used the term “frega” for a great number of diseases, such as various skin growths, ulcers, asthma; venereal diseases were known as “wet frega”; whereas internal diseases, jaundice and similar diseases were included into tropical diseases. All patients were treated by mercury, without determined doses (by the eye), in forms of pills, inunction and fumigation, as well as sarsaparilla boiled with sugar. He attributed special significance to diet: patients were allowed to eat only bread and brandy, while the treatment lasted from 20 to 100 days. External

Rista the Farrier was sentenced to 25 strokes, in order „not to exercise doctor's job“ anymore (3).

Furthermore, in 1845, a certain Sima Gipsy and Sava Pandur were forbidden to treat venereal diseases; Đorđe Komljenović was allowed to treat „frega“ from 1850 to 1856, but no other data were available about his work for us. Quackery was even more flourishing in places which remained under the Turkish rule till 1912, and these travelling quacks were the only ones treating the sick (26).

In the thirties of the 20th century, a „dangerous“ quack, Aleksej Suvorin, was known to treat 95% of all diseases, including syphilis, venereal and skin diseases, by starvation (1).

After all, the question of quacks - “specialists for syphilis“ is certainly not exhausted: the period till the Balkan wars was unfavourable for them, firstly because of the growing number of doctors, and secondly because of the introduction of new drugs in the treatment of syphilis. After the I World War, syphilis started spreading again, while our poor and devastated country was without doubt a fertile ground for the restoration of quackery. Despite difficult circumstances, the health service was reorganized, together with its discipline dermatovenereology: much effort has been put into suppressing quackery, by education of physicians, establishing a network of specialized health facilities and hospitals in Serbia, and by enlightening the people.

Conclusion

Apparently, spread of syphilis and quackery lasted almost parallel from the 4th decade of the 19th century well into the 20th century. That period was also characterized by hard and continuous development and activity of an organized medical service. It was not until the discovery of penicillin and eradication of syphilis in the 5th and 6th decades of the 20th century, when quacks - “specialists for syphilis“, finally disappeared in Serbia.

Abbreviation

Ministry of Internal Affairs - MIA

References

1. Milovanović V, urednik. Medicinski godišnjak Kraljevine Jugoslavije [Medical almanac of the Kingdom of Yugoslavia]. Beograd: Jugoreklam K.D; 1933. Serbian.
2. Karadžić V. Vukova prepiska, II [Correspondence of Vuk Stefanović Karadžić, II]. Serbian. Beograd: Državno izdanje; 1908. Serbian.
3. Đorđević T. Iz Srbije kneza Miloša [Serbia during the Rule of Prince Miloš]. Beograd: Prosveta; 1983. Serbian.
4. Mihajlović V. Istorija polnih bolesti u Srbiji do 1912. godine [The history of venereal diseases in Serbia up to 1912]. Beograd: Štamparija Centralnog higijenskog zavoda 7; 1931. Serbian.
5. Ilić S, Ignjatović B. Endemski sifilis u Srbiji: savremena akcija u njegovom suzbijanju [Endemic syphilis in serbia; an eradication campaign]. Beograd: Biblioteka Higijenskog instituta NR Srbije 12; 1957. Serbian.
6. Crosby AW. The Columbian exchange: biological and cultural consequences of 1492. 30th anniversary ed. London: Greenwood Press; 1972; Praeger, Westpoint: Connecticut Publishers; Copyright 2003.
7. Raport fizikusa Krainskog okruga Načelstvu Krainskog okruga [Archive document: A Report of the Krainki District Physicus to the Authorities of the Krainki District]. Arhiv Srbije, MD. Avg, 22, 1845. No 35. Serbian.
8. Waugh MA. History of clinical development in sexually transmitted diseases. In: Holms KK, Mardh PA, Sparling PF, Wiesner PJ, Cates W jr, Lemon SM, et al, eds. Sexually transmitted diseases. 2nd ed. New York: Mc Graw-Hill; 1999. p. 3-16.
9. Oriol JD. Eminent venereologists: 3. Philippe Ricord. Genitourin Med 1989;65:388-93.
10. Nedeljković J, Đuknić E, Đurić S, Jaćimović O, urednici. Vodič arhiva Srbije, I [A guide to the Archives of Serbia]. Beograd: Arhiv Srbije; 1973. Serbian.
11. Nešić M. Sifilis u severo-istočnoj Srbiji [Syphilis in North-East Serbia]. Beč: Štamparija Mehitarista; 1926. Serbian.
12. Jovanović-Batut M. Nadrulekari [Quacks]. Beograd: Štamparija i Litografija Save Radenkovića i brata; 1923. Serbian.
13. Dimitrijević L. Kako živi naš narod [How do our people live]. Beograd: Infinitas; 2010. Serbian.
14. Izveštaj lekara Okruga Gurgusovačkog Ministarstvu unutrašnjih dela [Archive Document: a report of the Gurgusovac County Physician to the Ministry of Internal Affairs]. Arhiv Srbije, MUD. Nov. 10, 1845. No 93. Serbian.
15. Fessler. Discussion on the history of the treatment of syphilis. Br J Venereal Dis 1948;24(4):160-1.
16. Stanojević V. Istorija medicine [History of medicine]. Beograd-Zagreb: Medicinska knjiga; 1953. Serbian.
17. Abraham JJ. Some account of the history of the treatment of syphilis. Br J Vener Dis 1948;24(4):153-60.
18. Norn S, Permin H, Kruse E, Kruse PR. Mercury – a major agent in the history of medicine and alchemy. Dan Medicinist Arbog 2008;36:21-40.

„lekara“ Turaka, radio je krijući svoju delatnost od državne vlasti. Jedan od njih, Asanaga, lečio je živom i sarsapatrilom, podučavao ljude kako da se sami leče, a i nekim babama je prenosio svoje znanje. Još jedan Turčin, Hadži Ahmed, lečio je „pilulama venerične bolesti“. Poznati su bili i Rista Potkivač, Stevan Kočijaš, Sima Ciganin i Sava Pandur. Državna vlast

im je zabranjivala rad, a neke je i kažnjavala batinama. Zaključak: U XIX veku, u Srbiji se sa širenjem sifilisa, gotovo paralelno, razvijala pojava nadržilekarstva, ali se razvijala i organizacija sanitetske službe. Tek sa otkrićem penicilina i eradikacijom sifilisa u V i VI deceniji XX veka, u Srbiji je definitivno završena era nadržilekara – „specijalista za sifilis“.

Ključne reči

Istorija medicine; Nadržilekarstvo; Srbija; Sifilis; Istorija 19. veka

Virgil Feier (Romania), Nikolai Tsankov (Bulgaria), Mirna Šitum (Croatia), Nermina Hadžigrahić (Bosnia and Hercegovina), Metka Adamič (Slovenia), Borut Poljšak (Slovenia), Branka Marinović (Croatia), Gjorgji Gocev (Macedonia), Tanja Planinšek Ručigaj (Slovenia), Evgenia Hristakieva (Bulgaria), Marina Jovanović (Serbia), Ljiljana Medenica (Serbia), Marijan Novaković (Serbia), Jana Kazandzieva (Bulgaria), Andrew J. Carmichael (UK), Camila K. Janniger (USA), Sanja Schuller-Petrović (Austria), Elena Belyakova (Russia), Milica Rajević (Serbia), and Igor Smiljanić (Serbia).

There were four eminent professors of dermatology from Serbia who were invited and presented Plenary Lectures: Miloš Nikolić lectured on the significant role of antinuclear antibodies with a speckled fluorescence pattern in keratinocytes of

patients with connective tissue diseases; Ljiljana Medenica reported about the history of moulage making in Serbia; Đorđije Karadaglić highlighted the challenging topic of palmoplantar pustular psoriasis; Marina Jovanović conveyed current data on genital herpes infections.

Various topics raised attention, we selected the following: Robert A. Schwartz assessed Kaposi's sarcoma; Jana Hercogová reported about Lyme disease. Andrew J. Carmichael supported indirect immunofluorescence to rule out impending pemphigoid in those over 50 years of age with persistent unexplained pruritus. Torello M. Lotti gave the latest information on vitiligo. Jana Kazandzieva answered the question what was new in dermatologic allergy. Gjorgji Gocev lectured about rosacea/demodex associations and controversies. Drug-induced and drug-triggered




Figure 2. a) Jana Hercogová (Czech Republic) and Predrag Štilet at the Opening Ceremony; b) Predrag Štilet presenting a honorary diploma to Marina Jovanović; c) Torello M. Lotti; d) Ljiljana Medenica

FORTHCOMING EVENTS

Dermatology and Venereology Events 2012

DATE	MEETINGS, CONGRESSES, SYMPOSIA	ABSTRACT SUBMISSION DEADLINE	MORE INFORMATION AT
06 April, 2012	Meeting of the Serbian Medical Society's Section of Dermatology and Venereology; Military Medical Academy, Belgrade	No abstract submission	www.sld.org.rs
11-14 April, 2012	European Academy of Allergy and Clinical Immunology (EAACI) focused meeting: Drug Hypersensitivity; Munich, Germany	10 February, 2012	www.eaaci-dhm2012.com
12-15 April, 2012	4 th Spring Meeting of the International Society for Dermatologic Surgery (ISDS); New Delhi, India	15 February, 2012	www.isdsworld.com
4-6 May, 2012	Meeting of the Serbian Medical Society's Section of Dermatology and Venereology; Prolom Banja	No abstract submission	www.sld.org.rs
16-19 May, 2012	11 th Congress of the European Society for Pediatric Dermatology; Istanbul, Turkey	20 January, 2012	www.espd2012.org
17-19 May, 2012	3 rd World Congress of Dermoscopy; Brisbane, Australia	12 December, 2011	www.dermoscopycongress2012.org
6-10 June, 2012	9 th EADV Spring Symposium; Verona, Italy	23 January, 2012	www.verona2012.eadv.org
16-20 June, 2012	European Academy of Allergy and Clinical Immunology Congress 2012; Geneva, Switzerland	18 January, 2012	www.eaaci2012.com
21-23 June, 2012	16 th European Hair Research Society (EHRS) Meeting; Barcelona, Spain	1 April, 2012	www.ehrs2012.com
27 June- 01 July, 2012	3 rd World Psoriasis and Psoriatic Arthritis Conference 2012; Stockholm, Sweden	1 March, 2012	www.ifpaworldconference.com
11-14 July, 2012	38 th Annual Meeting of the Society for Pediatric Dermatology; Monterey, United States	No deadline information	www.pedsderm.net
26-28 August, 2012	6 th International Congress on Dermato-Epidemiology; Malmö, Sweden	1 May, 2012	www.idea2012.net
19-22 September, 2012	42 nd Annual Meeting of the European Society for Dermatological Research; Venice, Italy	No deadline information	www.esdr2012.org
27-30 September, 2012	21 st EADV Congress; Prague, Czech Republic	21 March, 2012	www.eadvprague2012.org
5-7 October, 2012	European Academy of Allergy and Clinical Immunology (EAACI) focused meeting; International Symposium on Molecular Allergology; Rome, Italy	No deadline information	www.eaaci-isma2012.com

Prepared by: Dr. Tatjana Roš, Clinic of Dermatovenereology Diseases, Clinical Center of Vojvodina, Novi Sad, Serbia

provide the context or background for the study, as well as the purpose, basic procedures, main findings and principal conclusions. Authors should avoid using abbreviations.

- An **abstract in Serbian language**, (limited to 150 words) should follow the second page. It should contain a briefing on the purpose of the study, methods, results and conclusions, and should not contain abbreviations.

1.3. A list of abbreviations

Use only standard abbreviations, because use of non-standard abbreviations can be confusing to readers. Avoid abbreviations in the title, abstract and in the conclusion. A list of abbreviations and full terms for which they stand for should be provided on a separate page. All measurements of length, height, weight, and volume should be reported in the metric units of the International System of Units – SI, available at <http://www.bipm.fr/en/si/>.

1.4. Cover Letter

Manuscripts must be accompanied by a cover letter, which should include a date of submission, statement that the manuscript has been read and approved by all the authors and that the authorship requirements have been met. It should also include the name, address, and telephone number of the corresponding author, who is responsible for communicating with other authors about revisions and final approval of the proofs. The original copy of the cover letter, signed by all authors, should be enclosed with the manuscript.

2. Tables and illustrations

Tables should capture information concisely and precisely. Including data in tables, rather than in the text, reduces the length of the article itself.

- Submit tables in separate files, not included in the manuscript. Tables are to be double spaced and numbered sequentially, with Arabic numbers (Table 1, Table 2, etc.), in order of text citation. Each column, including the first, must have a heading. Provide a brief title for each table. Put all explanatory matter in

footnotes, including any nonstandard abbreviations used in the table.

- **Figures** should be submitted in a separate file, not included in the manuscript document. Cite figures consecutively, as they appear in the text, with Arabic numbers (Fig. 1, Fig. 2, Fig. 3, etc.). Each figure must be assigned a title, as well as a legend. Legends should appear on a separate page, not with each figure. The **Legend Page** is to be numbered in sequence after the last page of the references list. Figures should be professionally drawn, as sharp black-and-white or color photographs. If photographs of persons are used, either the subjects must not be identifiable, or their pictures must be accompanied by written permission to use them.

3. References

References in the text, tables and legends should be identified by Arabic numerals in parentheses. Number references consecutively in the order in which they are first mentioned in the text. The *Vancouver System* of referencing should be used. List each author's last name and initials; full first names are not included. List all authors, but if the number exceeds six, give the first six followed by „et al.” National journals, which are not indexed in *Index Medicus*, should be abbreviated according to the style in the *List of Abbreviated Titles of Yugoslav Serial Publications* available on <http://vbsw.vbs.rs>. For further information please visit www.ICMJE.org.

4. Additional information

Accepted manuscripts are edited and returned to the corresponding author for approval. Then a final version of the manuscript will be requested in a defined period of time. Authors will be notified of acceptance or rejection by email, within approximately 4 weeks after submission.

- Open access: Every article published in the **Serbian Journal of Dermatology and Venereology** will immediately be accessible on www.udvs.org to everyone at no charge.

For further information please contact the Editorial Office (Tel: +381 21/484 35 62) or visit our web site: www.udvs.org.

NOVO BIOLOŠKA
ZAŠTITA ČELIJA



Jača odbrambeni mehanizam kože od sunca

Osetljivoj dečijoj koži je potrebna posebna zaštita. Osim veoma visoke UVB/UVA zaštite sa SPF 50+, Eucerin SUN dečiji preparati obezbeđuju dodatnu DNK zaštitu zahvaljujući prirodnoj gliciretinskoj kiselini. Vrhunska zaštita od sunca i veoma dobra podnošljivost, za osetljivu dečiju kožu.

Eucerin[®]